

4. Varettoni M, Corso A, Pica G, Mangiacavalli S, Pascutto C, Lazzarino M. Incidence, presenting features and outcome of extramedullary disease in multiple myeloma: a longitudinal study on 1003 consecutive patients. *Ann Oncol.* 2010;21:325–30.

Melda Cömert,<sup>a,\*</sup> Soner Gürsoy,<sup>b</sup> Mahmut Töbü<sup>a</sup>

<sup>a</sup> Departamento de Hematología, Facultad de Medicina, Universidad Ege, Esmirna, Turkey

<sup>b</sup> Departamento de Cirugía Torácica, Hospital de Investigación Suat Seren, Esmirna, Turkey

\* Corresponding author.

E-mail addresses: [meldacomert@hotmail.com](mailto:meldacomert@hotmail.com) (M. Cömert), [grssoner@gmail.com](mailto:grssoner@gmail.com) (S. Gürsoy), [mtobu@yahoo.com](mailto:mtobu@yahoo.com) (M. Töbü).

## Pleural Effusion Secondary to Actinomyces Infection as a Late Complication of Laparoscopic Cholecystectomy<sup>☆</sup>



### Derrame pleural secundario a infección por Actinomyces como complicación tardía de una colecistectomía laparoscópica

To the Editor,

Cases of intra-abdominal actinomycosis have been described years after cholecystectomy, although it is a rare complication. Due to the slow growth of *Actinomyces*, symptoms can present months or even years after surgery.<sup>1,2</sup>

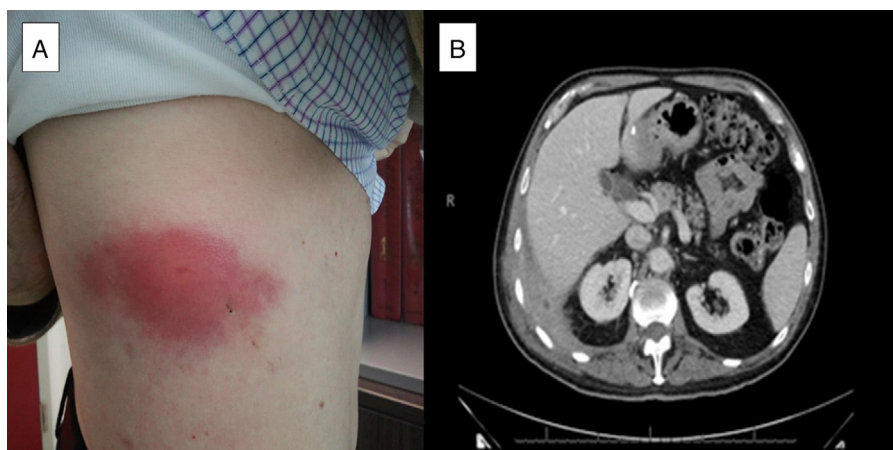
We present the case of a 71-year-old patient who underwent delayed laparoscopic cholecystectomy for acute cholecystitis. Four years later, he presented with dyspnea, cough, asthenia and pleuritic pain in the right hemithorax. On physical examination he was found to have a hard, painful swelling on the lateral region of the right hemithorax (Fig. 1A), with absent breath sounds. Acute phase reactants were elevated, and the chest radiograph showed right pleural effusion. Computed tomography (CT) revealed thickening of the pleura of the right posterolateral costophrenic angle (2.5-cm in thickness) and a hypodense area inside with extrapleural fat involvement, muscle thickening and pleural effusion (Fig. 1B). Thoracocentesis was performed and a fluid consistent with an exudate with predominantly polymorphonuclear cells was obtained, which later became mononuclear cell-predominant. Microbiology and cytology were negative. Needle biopsy of the pleural thick-

ening reported an inflamed abscess. Ultrasound of the rib region showed a 3-cm hypoechoic mass, with multiple echoes, consistent with an abscess. This was aspirated and purulent matter was extracted; subsequent culture revealed *Actinomyces israelii* and *Escherichia coli*. From that time, the patient presented a chest wall fistula. Intravenous (i.v.) amoxicillin/clavulanic acid treatment was started for 14 days, followed by a further 4 weeks of i.v. penicillin. After 6 weeks of i.v. antibiotic, clinical improvement was observed and the fistula closed. Oral amoxicillin was continued until the patient had completed 12 months of treatment. A follow-up CT scan performed after the patient had been on antibiotics for 5 months showed a reduction in the effusion, with no changes in the pleural thickening.

*A. israelii* inhabits the oral cavity and upper gastrointestinal tract. Infection can occur when the mucosal barrier is damaged due to endoscopic manipulation, surgery or immunosuppression. Sulfur granules are characteristic on histological examination, but definitive diagnosis is made with microbiological isolation.<sup>3</sup> The infection is usually found in middle-aged men with poor dental hygiene, and is most often located in the cervicofacial area (50%), followed by the abdomen (20%) and chest (15%–20%).<sup>2</sup>

The most common cause of chest involvement is aspiration of secretions,<sup>2</sup> and it can present as empyema, pneumonia that progresses to cavitation, and pericardial or diaphragmatic involvement.<sup>4</sup>

Symptoms are variable and non-specific, and the patient may be asymptomatic. Acute phase reactants are generally elevated.<sup>3</sup>



**Fig. 1.** (A) Image of the lesion in the lateral region of the right hemithorax. (B) Chest CT slice showing thickening of the pleura of the right posterolateral costophrenic angle with a hypodense area inside, with extrapleural fat involvement, muscle thickening and pleural effusion.

<sup>☆</sup> Please cite this article as: Díaz Campos RM, López-Medrano F, Lalueza A, Granados Caballero F, Villena Garrido V. Derrame pleural secundario a infección por *Actinomyces* como complicación tardía de una colecistectomía laparoscópica. *Arch Bronconeumol.* 2015;51:419–420.

Initial treatment is i.v., with maximum doses for 4–6 weeks followed by oral treatment for a further 6 to 12 months. Penicillin is the drug of choice, although tetracycline, erythromycin or clindamycin may be also used in patients who are allergic to penicillin. Chest involvement usually requires more prolonged treatment than involvement at any other level. There are specific indications for surgery; as this alone is not curative, it must always be combined with prolonged high-dose antibiotic treatment.<sup>2,5</sup>

When diagnosed and treated promptly, the prognosis is good, with low mortality.<sup>5</sup>

Thus, pleural effusion with chest wall involvement in a patient with a history of laparoscopic cholecystectomy could be secondary to abdominal infection by *Actinomyces*.

## References

1. Stupak D, Cohen S, Kasmin F, Lee Y, Siegel JH. Intra-abdominal actinomycosis 11 years after spilled gallstones at the time of laparoscopic cholecystectomy. *Surg Laparosc Endosc Percutan Tech*. 2007;17:542–4.
2. Choi JC, Koh WJ, Kim TS, Lee KS, Han J, Kim H, et al. Optimal duration of IV and oral antibiotics in the treatment of thoracic actinomycosis. *Chest*. 2005;128:2211–7.

3. Ozgediz D, Zheng J, Smith EB, Corvera CU. Abdominal actinomycosis after laparoscopic cholecystectomy: a rare complication of bile spillage. *Surg Infect*. 2009;10:297–300.
4. Avisbal Portillo N, Rueda Ríos C, Benítez Domenech A. Actinomycosis como causa de un derrame pleural. *Arch Bronconeumol*. 2002;38:153–4.
5. Mabeza GV, MacFarlane J. Pulmonary actinomycosis. *Eur Respir J*. 2003;21:545–51.

Rocío Magdalena Díaz Campos,<sup>a,\*</sup> Francisco López-Medrano,<sup>b</sup> Antonio Lalueza,<sup>b</sup> Fernando Granados Caballero,<sup>c</sup> Victoria Villena Garrido<sup>a</sup>

<sup>a</sup> Servicio de Neumología, Hospital Universitario 12 de Octubre, Madrid, Spain

<sup>b</sup> Unidad de Enfermedades Infecciosas, Servicio de Medicina Interna, Hospital Universitario 12 de Octubre, Madrid, Spain

<sup>c</sup> Servicio de Radiología, Hospital Universitario 12 de Octubre, Madrid, Spain

\* Corresponding author.

E-mail address: rociomdc80@gmail.com (R.M. Díaz Campos).

## Mortality in Obesity-hypoventilation Syndrome and Prognostic Risk Factors<sup>☆</sup>



### Mortalidad en el síndrome de obesidad-hipoventilación y factores de riesgo pronóstico

To the Editor:

The clinical presentation of patients with obesity-hypoventilation syndrome (OHS) is heterogeneous in terms of severity, ranging from those with few symptoms referred for suspected sleep apnea–hypopnea syndrome (SAHS), to those diagnosed after admission to an intensive care unit for hypercapnic encephalopathy. Published clinical series indicate that OHS is associated with major morbidity and mortality, with respiratory or cardiovascular failure causing fatal outcome. It is likely that failure to suspect the respiratory disorder together with cardiovascular comorbidity at the time of diagnosis contribute to an unfavorable prognosis in specific patients.<sup>1–4</sup>

Several observational series estimating mortality in this group and identifying associated risk factors have been published.<sup>1–4</sup> Ojeda Castillejo et al. recently published an interesting prospective study in *Archivos de Bronconeumología* on the evolution of patients with OHS, and we would like to comment on several aspects of this series.<sup>5</sup> This study has probably the longest follow-up time (mean >7 years) of those hitherto published; patients were closely monitored, and seemingly appropriate ventilation criteria were established. As regards results, the authors found that the OHS group without SAHS had higher mortality, and that, in contrast to earlier studies, persistence of reduced forced vital capacity (FVC) had prognostic value. Moreover, and contrary to what might be expected,<sup>2–4</sup> they found that baseline paO<sub>2</sub> had no prognostic value. Although the results of studies such as this are relevant and necessary to understand the natural history of patients with OHS, the absence of some data limits interpretation of the results:

1. Patients were recruited either after they had been stabilized following hospital admission for respiratory acidosis, or

during a visit to the clinic. Hospitalized patients may have more comorbidities than those recruited in the clinic.<sup>3,4</sup> However, the authors do not provide data on comorbidities.

2. In the mortality analysis, the authors do not indicate if they included patients who did not comply with non-invasive mechanical ventilation (NIV) or continued positive airway pressure (CPAP) therapy—a total of 9 subjects. This is another relevant detail, as lack of compliance has been associated with higher mortality.<sup>1,3</sup> The distribution of non-compliers by patient group is also unknown.
3. The many causes of hypoxemia under NIV include central hypoventilation and ventilation/perfusion disorders. In this respect, there are clinical practice guidelines that recommend a support pressure setting of at least 10 mmHg (inspiratory positive airway pressure [IPAP]–expiratory positive airway pressure [EPAP]) before assessing whether oxygen should be added. In the paper by Ojeda Castillejo et al., it is not clear if this consideration has been taken into account.
4. ANOVA or the Student's *t*-test with Bonferroni correction is more appropriate for a comparative analysis of FVC values over time.

To summarize, to estimate prognostic factors of mortality in patients with OHS, NIV or CPAP settings must be correct, and a detailed study of potentially relevant risk factors should be made. Additionally, and while awaiting the results of ongoing studies, it will be interesting to see if nocturnal monitoring of NIV in poor responders (by analyzing the ventilator software with or without simultaneous polygraphy) will have a positive effect on their quality of life and prognosis for survival.

## Funding

The authors did not receive any funding for writing this manuscript.

## Conflict of Interest

The authors declare that they have no conflict of interests.

<sup>☆</sup> Please cite this article as: Navarro Esteve J, Hinojosa Astudillo C, Juliá Serdá G. Mortalidad en el síndrome de obesidad-hipoventilación y factores de riesgo pronóstico. *Arch Bronconeumol*. 2015;51:420–421.