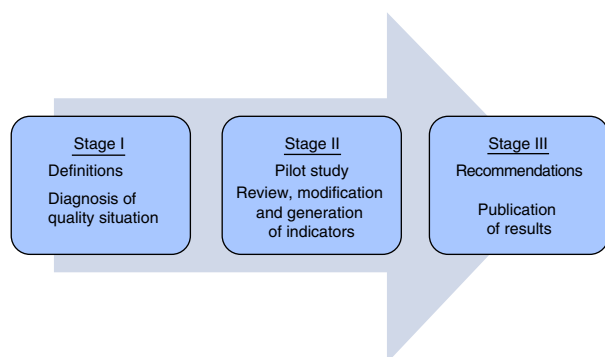


Table 2
Objectives.

Diagnose the quality situation by means of a pilot scheme to monitor the most relevant quality healthcare indicators for respiratory patients in participating units (Stage II)
Review existing evidence-based quality indicators for the respiratory population or specialty and study their applicability and relevance for respiratory intensive care units (Stage II)
Modify the most relevant quality indicators for the respiratory population, based on the available scientific evidence, for use in units specializing in respiratory intensive care, adapted to their specific needs (Stage II)
Generate quality indicators for respiratory intensive care units based on the key processes identified in those units (Stage II)
Draw up recommendations for the use of quality indicators in respiratory intensive care units (Stage III)
Publish the results of the project in scientific journals (Stage III)

**Fig. 1.** Task force working plan for the review, modification and generation of quality indicators for respiratory intensive care units.

deficient (Table 1) and the team agreed to complete the first stage of the project by collecting relevant information from a prospective cohort. Specific project objectives that will be addressed in 2 subsequent stages are described in Table 2 and Fig. 1.

The Task Force is currently receiving support from their respective hospitals (the most important tertiary and fourth-level centers

in the Mexican health system), as well as the backing of the Mexican Pulmonology Council. In the future, we hope to gain the support of the Mexican College of Critical Medicine, the Mexican Society of Pulmonology and Thoracic Surgery and other scientific societies, with the aim of achieving the widespread dissemination of acceptable results.

References

- Safe Practices for Better Healthcare: A Consensus Report, 2003. Available in: <http://www.qualityforum.org/txsafeexecsumorder6-8-03PUBLIC.pdf> [accessed 12.01.06].
- Martín MC, Cabré L, Ruiz J, Blanch L, Blanco J, Castillo F, et al. Indicadores de calidad en el enfermo crítico. *Med Intensiv.* 2008;32:23–32.
- Indicadores de calidad en el enfermo crítico. Actualización de 2011. Available in: http://www.semicuc.org/sites/default/files/actualizacion_indicadores_calidad_2011.pdf [accessed 01.10.11].
- Álvarez-Maldonado P, Cueto-Robledo G, Cerón-Díaz U, Pérez-Rosales A, Navarro-Reynoso F, Cicero-Sabido R. Indicadores de calidad en una unidad de cuidados intensivos respiratorios. Análisis inicial de la base de datos DEDUCIR. *Med Intensiv.* 2012;36:518–20.
- Torres A, Ferrer M, Blanquer JB, Calle M, Casolíve V, Echave JM, et al. Unidades de cuidados respiratorios intermedios. Definición y características. *Arch Bronconeumol.* 2005;41:505–12.

Pablo Álvarez-Maldonado,^{a,*} Edgar Bautista-Bautista,^b Víctor Huizar-Hernández,^c Roberto Mercado-Longoria,^d Guillermo Cueto-Robledo^a

^a *Unidad de Cuidados Intensivos Respiratorios, Servicio de Neumología y Cirugía de Tórax, Hospital General de México O.D., Mexico City, Mexico*

^b *Departamento de Medicina Crítica, Instituto Nacional de Enfermedades Respiratorias, INER, Mexico City, Mexico*

^c *Unidad de Cuidados Intensivos Respiratorios, Servicio de Neumología, Centro Médico Nacional "La Raza", IMSS, Mexico City, Mexico*

^d *Servicio de Neumología y Cuidados Intensivos, Hospital Universitario, Monterrey, Nuevo León, Mexico*

* Corresponding author.

E-mail address: pamyacs@yahoo.com (P. Álvarez-Maldonado).

Bronchoaspiration of Foreign Bodies. Clinical Case and Review[☆]



Broncoaspiración de cuerpos extraños. Caso clínico y revisión

To the Editor,

At the end of the nineteenth century, foreign body (FB) aspiration had a mortality rate of 50%, but this has gradually fallen since the first endoscopic extraction performed by Gustav Killian. Modifications of the extraction technique followed, and today, flexible bronchoscopy is one of the most widely used methods in these cases. We present the case of a 67-year-old man diagnosed with aspiration of a dental drill bit used for dental implants.

The patient came to the Emergency Department from a dental appointment one hour earlier, during which a drill bit had accidentally fallen into his oral cavity while he was undergoing root

canal treatment, and disappeared; the dentist believed that the patient had swallowed it, and referred him to our hospital. The patient was asymptomatic on arrival. Chest X-ray and computed axial tomography (CT) (Fig. 1) revealed the drill bit in the bronchus intermedius, with no associated complications. Oral bronchoscopy was performed under sedation, and the bit was removed en bloc using crocodile forceps (Fig. 1). The patient was discharged 24 h later.

The first published case of endoscopic extraction occurred on 30th March 1897, when a 63-year-old German farmer experienced dyspnea, cough and hemoptysis after aspirating a pork bone (11 mm long and 3 mm wide). Using a modified Mikulicz-Rosenheim esophagoscope (a rigid tube illuminated with a head mirror) and rigid forceps, Gustav Killian managed to remove the splinter from the right main bronchus.¹

FB aspiration is most common in males aged between 1 and 2-years,² with a mortality of 7% in children <4 years. The incidence in adults is <0.4%,³ mostly in the geriatric population, or in association with neurological diseases, alcohol or drug abuse, traumatic intubation, mental retardation, dental treatment and tracheotomy patients. The type of FB depends on the age: in children, up to 55% are of vegetable origin (peanuts and seeds²); in adults, Blanco et al. reported 32 cases of bronchoaspiration out of 9781 bronchoscopies

[☆] Please cite this article as: Gómez López A, García Luján R, de Miguel Poch E. Broncoaspiración de cuerpos extraños. Caso clínico y revisión. *Arch Bronconeumol.* 2015;51:358–359.

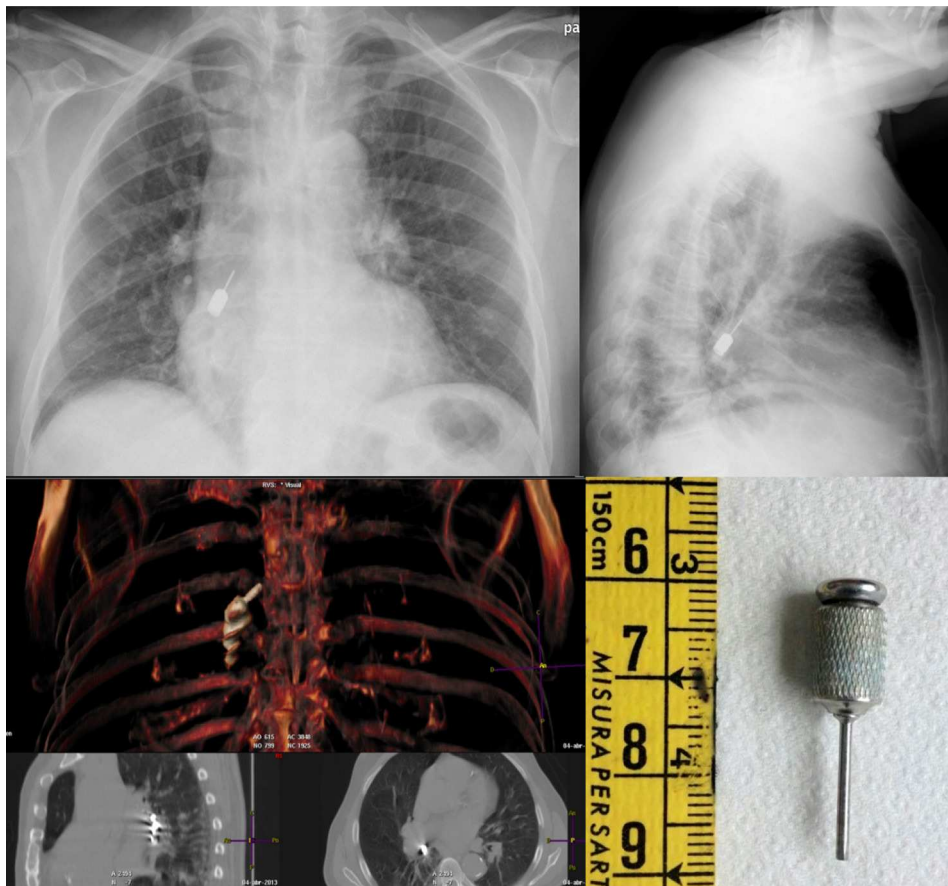


Fig. 1. The upper images show the chest X-ray with the drill bit in the bronchus intermedius. In the lower figures, the chest CT can be seen on the left and the foreign body extracted is shown on the right.

performed, 78% of which were of inorganic material, followed by dental material.³

Only one case involving the same dental object with characteristics and results similar to ours has been published.⁴

Symptoms, when present, are usually: intractable cough, dyspnea or repeated infections. Abnormal findings on chest X-ray include atelectasia, infiltrates or signs of hyperinflation, although results are normal in more than 40% of patients.³

Bronchoscopy is the technique of choice; the most common location is the bronchus intermedius, and foreign bodies are observed in routine bronchoscopies in up to 9% of patients.⁵ The extraction technique varies from non-bronchoscopic techniques (in small, movable objects like dried fruits or seeds) where positioning maneuvers and/or the use of systemic steroids to reduce the edema and facilitate expectoration may suffice,⁵ to endoscopic techniques or thoracotomies. The endoscopic route will avoid distal displacement of the FB, using a Fogarty catheter or balloon prior to its extraction.⁵ Although flexible bronchoscopy is recommended in most cases,³ rigid bronchoscopy is the technique of choice in children <12 years and some adults, depending on the FB and patient.²

References

1. Campos Meirelles R, Machado Neves-Pinto R. Gustav Killian – a Milestone in the Otorhinolaryngology. *Int Arch Otorrinolaringol.* 2005;9. http://www.internationalarchivesent.org/conteudo/acervo_eng.asp?id=315 [accessed 13.01.14].
2. Airways foreign bodies: clinical presentation, diagnosis and treatment. Strausz J, Bollinger CT, editors. *European respiratory monograph. Interventional pulmonology.* Nice, France: European Respiratory Society (ERS); 2010. p. 136–48.
3. Blanco M, Fernández-Villar A, Rivo JE, Leiro V, García-Fontán E, Botana MI, et al. Extraction of airway foreign bodies in adults: experience from 1987–2008. *ICVTS.* 2009;9:402–5.
4. Luezzi G, Kawamukai K, Lacava N. An unusual foreign body after dental filling. *Lung.* 2013;191:677–8.
5. Swanson KL. Airway foreign bodies: what's new. *Semin Respir Crit Care Med.* 2004;25:405–11.

Antolina Gómez López,* Ricardo García Luján,
Eduardo de Miguel Poch

Unidad de Endoscopia Respiratoria, Hospital Universitario 12 de Octubre, Madrid, Spain

* Corresponding author.

E-mail address: antolinagl@hotmail.com (A. Gómez López).