

apical, anterior and posterior. Bronchoalveolar lavage and cytology were normal. Bronchoalveolar lavage and aspirated fluid were negative for acid-alcohol resistant bacilli and Lowenstein culture for tuberculosis was negative. No clinical or radiological changes were observed after 6 months of follow-up.

SI is an uncommon congenital transpositional anomaly in which the organs of the abdomen develop in the wrong place. It occurs at a ratio of men to women of 3:2.³ In the normal arrangement, or *situs solitus*, the trilobar lung, the liver, the gall bladder and other internal organs are on the right side, but in SI they are on the left. The heart may be on the left on the right.⁴

In our case, SIT was defined with segmentary atelectasis of the right lung and the development of the right upper lobe in the area of the left upper lobe. To our knowledge, this combination has never been described in the worldwide literature. Sarkar et al.⁵ are the only authors to have reported a case of unilateral pulmonary hypoplasia associated with abdominal *situs inversus* in a 2-month-old infant.

In conclusion, SI is diagnosed fortuitously during a chest and abdominal imaging study. In these cases, pulmonary atelectasis in the right upper lobe of the left lung may be observed.

Conflict of Interests

The author declares no conflict of interests.

References

1. Akbulut S, Caliskan A, Ekin A, Yagmur Y. Left-sided acute appendicitis with situs inversus totalis: review of 63 published cases and report of two cases. *J Gastrointest Surg.* 2010;14:1422–8.
2. Nelson MJ, Pesola GR. Left lower quadrant pain of unusual cause. *J Emerg Med.* 2001;20:241–5.
3. Huang SM, Yao CC, Tsai TP, Hsu GW. Acute appendicitis in situs inversus totalis. *J Am Coll Surg.* 2008;207:954.
4. Küçükay F, Ökten RS, Cumhur T. Percutaneous biliary intervention for primary sclerosing cholangitis in a patient with situs inversus totalis. *Turk J Gastroenterol.* 2011;22:636–40.
5. Sarkar S, Mondal R, Nandi M, Das NK. Unilateral pulmonary hypoplasia with abdominal situs inversus. *Indian J Pediatr.* 2012;79:1360–2.

Abdullah Şimşek

Chest Diseases Public Hospital, Bursa, Turkey

E-mail address: abdullahsimsek@yahoo.com.tr

Malignant Solitary Fibrous Tumour of the Pleura: An Uncommon Entity[☆]



Tumor fibroso solitario pleural maligno: una rara entidad

To the Editor,

Solitary fibrous tumor of the pleura (SFTP) is an uncommon disease, and only about 800 cases have been described in the literature. There are 2 distinct types: the local, benign form, and the more uncommon, highly aggressive diffuse form.^{1,2} It can appear at any age, although it is more common in patients between 60 and 70 years of age. It begins as an intrathoracic pleomorphic mass, requiring a differential diagnosis considering benign and malignant pleuropulmonary lesions. Histopathological analysis is essential for reaching the right diagnosis.

We report the case of a 55-year-old woman, non-smoker with no significant clinical history, who presented with chest pain after an injury. A chest X-ray was performed, which fortuitously revealed a right pleuropulmonary tumor. The patient had no respiratory symptoms and lung function test results were normal. A computed axial tomography (CAT) of the chest was obtained for further investigation, showing a tumor in the lower third of the right hemithorax, in close proximity to the diaphragm and cardiomediastinal structures (Fig. 1). Fine needle biopsy revealed tissue consistent with spindle cell mesenchymal tumor. In view of these findings, the patient underwent the routine surgical procedure and the tumor was fully resected. Pathological analysis confirmed a solitary fibrous tumor with areas of spindle cells with a high mitotic index, significant pleomorphism and high cellularity (meeting the malignancy criteria of England et al.). Immunohistochemistry was positive for vimentin and CD34.³ Adjuvant treatment was ruled out due to the low chemosensitivity of this tumor strain and the lack of data in this respect. Routine monitoring was performed until 1 year later, when 2 apparently

malignant nodular lesions, very close to each other (18 mm and 13 mm), were seen on a follow-up CAT. These lesions were subsequently resected. Pathological findings confirmed tumor compatible with SFTP metastasis. Six months later, multiple nodules were observed in both lungs on a repeat CAT, and bone involvement was confirmed by scintigraphy. After evaluation by the medical oncology department, c-KIT mutation determination was ordered, in view of reports of long periods of response with imatinib associated with this mutation.⁴ In the end, however, the tumor was c-KIT negative, so chemotherapy was started. Despite the various treatment lines administered, disease progression was rapid and the patient died shortly after the diagnosis of relapse.

This case illustrates 2 interesting aspects. Firstly, the appearance of SFTP, an uncommon tumor that presents with generalized symptoms, and must be considered as part of the differential diagnosis of pleural masses. Secondly, the disease appeared to begin as a non-aggressive type, although the histopathological finding suggested it was high risk. It subsequently gradually developed to a highly aggressive form. These findings underline that little is known about

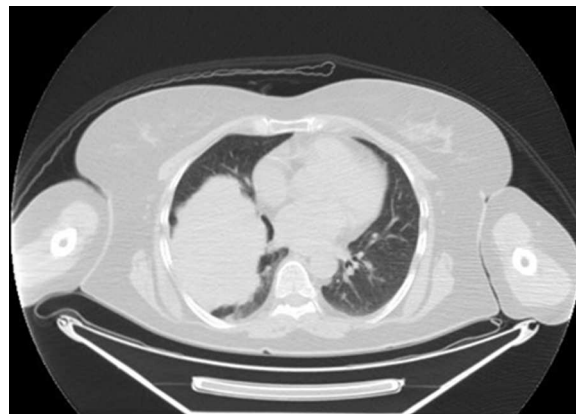


Fig. 1. Computed axial tomography.

[☆] Please cite this article as: Cruz Castellanos P, de Castro Carpeño J. Tumor fibroso solitario pleural maligno: una rara entidad. *Arch Bronconeumol.* 2015;51:362–363.

this tumor and its natural history, and that treatment options are limited.

References

1. de Perrot M, Fischer S, Bründler MA, Sekine Y, Keshavjee S. Solitary fibrous tumors of the pleura. *Ann Thorac Surg.* 2002;74:285–93.
2. Marak CP, Dorokhova O, Guddati AK. Solitary fibrous tumor of the pleura. *Med Oncol.* 2013;30:573.
3. England DM, Hochholzer L, McCarthy MJ. Localized benign and malignant fibrous tumors of the pleura. A clinicopathologic review of 223 cases. *Am J Surg Pathol.* 1989;13:640–58.

4. De Pass T, Toffaloro F, Colomo P, Trifirò G, Pelosi G, Vigna PD, et al. Brief report: Activity of imatinib in a patient with platelet-derived-growth-factor receptor positive malignant solitary fibrous tumor of the pleura. *J Thorac Oncol.* 2008;3:938–41.

Patricia Cruz Castellanos,* Javier de Castro Carpeño

Servicio de Oncología Médica, Hospital Universitario La Paz, Madrid, Spain

* Corresponding author.

E-mail address: cruz.patricia@hotmail.com (P. Cruz Castellanos).

Delayed Pulmonary Fibrosis (Usual Interstitial Pneumonia) in a Patient With Previous Uncomplicated H1N1-Associated Pneumonia[☆]



Fibrosis pulmonar tardía (neumonía intersticial usual) en un paciente con antecedentes de neumonía asociada a H1N1 no complicada

To the Editor,

In February 2011, a 53-year-old man was admitted to our hospital for fever, non-productive cough and dyspnea on effort; he did not report any history of workplace exposure during the medical examination.

Computed tomography (CT) of the chest showed bilateral pulmonary consolidations, mainly involving the lower lobes.

No leukocytosis was seen on the blood tests, and the differential leukocyte count was 72.7% neutrophils and 18.5% lymphocytes. Serum biochemistry results were normal. Tests for anti-neutrophil cytoplasmic antibodies (ANCA), antinuclear antibodies (ANA), anti-DNA antibodies and extractable nuclear antigens (ENA) were negative.

Arterial blood gases (ABG) showed moderate hypoxemia, with partial oxygen pressure (PO₂) 52 mmHg, PCO₂ 34 mmHg, and pH 7.48; arterial oxygen saturation (SaO₂) was 88%.

Pharyngeal swab analysis was positive for H1N1.

The patient was referred to the infectious diseases unit, where he received combined treatment with prednisone 25 mg, orally, twice a day for 10 days, cefotaxime 1 g, intravenously, twice a day for 10 days, inhaled zanamivir (2 mg × 5 mg) twice a day for 5 days and oseltamir, 1 75 mg capsule twice a day for 5 days. The patient's clinical situation improved rapidly, as reflected in radiological and ABG results. Twenty days later, he was discharged in good condition.

A chest CT was performed before discharge, showing good recovery of lung function, and ABG results were normal (pH=7.41; PCO₂=37 mmHg; PO₂=85 mmHg and SaO₂=96%).

The patient was then referred for respiratory follow-up, including high-resolution computed tomography (HRCT) scans, ABG analysis and lung function testing with determination of the diffusing capacity of the lungs for carbon monoxide (DLCO).

At the 1, 3 and 6-month follow-up visits, the patient was asymptomatic; serial chest HRCTs showed slight basal consolidation, less than 3 cm in diameter, in the form of reticular and ground glass opacities.

During this time, the radiological signs did not alter either in shape or in size. Lung function test results were normal: FVC=86.6%; FEV1=96%; FEV1/FVC: 88.47; DLCO: 78% and SpO₂: 96%.

In May 2012, the patient became symptomatic again, with non-productive cough and dyspnea on effort. He returned to the clinic with marked reduction in lung function parameters: FVC=66.7%; FEV1=76.2%; FEV1/FVC=90.63, SpO₂=91%; DLCO values were also severely reduced (55% compared to 78%).

Another chest HRCT was then performed, revealing ground glass and peripheral reticular opacity, particularly in the lung bases (Fig. 1A).

Blood and serum test results were normal. A flexible fiberoptic bronchoscopy was performed, and a transbronchial biopsy was obtained, the results of which were indecisive—only inflammatory lymphocyte infiltration and alveolar septal fibrosclerosis were found on histopathology examination. Bronchoalveolar lavage (BAL) results were negative.

A surgical lung biopsy was performed using video-assisted thoracoscopic surgery (VATS) under general anesthesia with one-lung ventilation, and 3-port incision in the right side (one sample per lobe).

Histopathological analysis revealed widened alveolar septa with type II pneumocyte proliferation and mononuclear inflammatory infiltrate with interstitial fibrosis in patchwork pattern, suggesting usual interstitial pneumonia (Fig. 1B). After an incident-free post-operative period, the patient was referred to the pulmonology unit for appropriate medical treatment.

Although the etiology of usual interstitial pneumonia (UIP) is unknown, the following risk factors have been proposed: acute respiratory distress syndrome (ARDS), environmental exposure to metal dust, smoking habit, connective tissue disorders, drug toxicity, chronic viral infections, such as Epstein-Barr virus, cytomegalovirus, hepatitis C virus, human herpesvirus (HHV)-7 and HHV-8.¹

Ground glass opacity on chest imaging studies and reduced DLCO have been reported in H1N1 pneumonia in a study with 3 months' follow-up.^{2,3} We report a very uncommon case of late-onset UIP after uncomplicated H1N1 pneumonia in a 53-year-old man, detected in HRCT obtained one year after the disease onset.

These results, along with the histopathology examination, were consistent with the development of pulmonary fibrosis. Pulmonary fibrosis may occur after ARDS or ventilator-associated pneumonia.^{4,5}

In our patient, radiological signs of fibrosis were confirmed by histopathological examination of surgical biopsy specimens obtained by standard VATS.⁶

By presenting this case, we wish to draw attention to long-term sequelae in a patient with no prior history of ARDS and who did not require mechanical ventilation. Symptomatic pulmonary

[☆] Please cite this article as: Baietto G, Davoli F, Turello D, Rena O, Roncon A, Papalia E, et al. Fibrosis pulmonar tardía (neumonía intersticial usual) en un paciente con antecedentes de neumonía asociada a H1N1 no complicada. *Arch Bronconeumol.* 2015;51:363–364.