

2014 GesEPOC and Systemic Steroids in Chronic Obstructive Pulmonary Disease (COPD) Exacerbation: An Update[☆]



Actualización de GesEPOC 2014 y corticoides sistémicos en la agudización de enfermedad pulmonar obstructiva crónica (EPOC)

To the Editor,

We have read the latest version of the Spanish guidelines on COPD (GesEPOC), published recently (January 2014) in Archivos de Bronconeumología.¹ When the AUDIEPOC study was published in July 2012, we observed that there was little homogeneity in the management of COPD exacerbation at the national level.² A more rigorous review of the published data revealed that this variability also exists in the use of systemic corticosteroids during exacerbations. In the 2014 update, GesEPOC clinical guidelines propose a change in systemic corticosteroid treatment during exacerbations. Thus, the original version recommended a short course of 7–10 days,³ while in the 2014 update, the guidelines support the use of “short 5-day courses for [...] exacerbations that do not require hospitalization”.

We believe that this change is based essentially on data from the REDUCE clinical trial,⁴ which compared treatment with a short 5-day course of 40 mg of prednisone versus a 14-day course during exacerbations. The trial showed a similar reexacerbation rate, with the advantage of lower exposure to corticosteroids and very similar findings as regards outcomes (hospital stay and deaths).

We agree that exacerbations can be managed with lower doses and shorter treatment times than those used in routine clinical practice. At the same time, we consider that this conclusion, currently limited by the guidelines to outpatients, could also be extended to some patients with more severe exacerbations who require hospital admission. In the REDUCE clinical trial, of the 314 patients who attended the Emergency Department (311 evaluated) and were randomized to receive a short or long corticosteroid regimen, 289 (92%) patients were admitted to hospital. The groups

[☆] Please cite this article as: Marcos PJ, Huerta A, Márquez-Martín E. Actualización de GesEPOC 2014 y corticoides sistémicos en la agudización de enfermedad pulmonar obstructiva crónica (EPOC). Arch Bronconeumol. 2015;51:360.

Peripheral Intrapulmonary Lipoma: A Case Report[☆]



Lipoma intrapulmonar periférico: reporte de un caso

To the Editor,

Endobronchial pulmonary lipomas are rare, and intraparenchymal endobronchial lipomas are even more so. We report the case of a 62-year-old housewife, never-smoker, with a history of vaginitis, psoriasis, hypertension and hysterectomy. During a private health check-up, a chest X-ray revealed a radiopaque mass, 4 cm × 3 cm,

[☆] Please cite this article as: Castro Ramírez N, Cano Pazmiño F, Rivera Rivera T. Lipoma intrapulmonar periférico: reporte de un caso. Arch Bronconeumol. 2015;51:360–361.

were adequately balanced with respect to COPD severity (GOLD 2, 3 and 4 in both groups) and clinical presentation (vital signs, oxygenation on admission, leukocytosis).

The meta-analysis published by Cheng et al.⁵ also reinforces the hypothesis that lower doses of corticosteroids (30–80 mg of prednisolone for 5 days) can be safely used in inpatients with COPD exacerbation.

This meta-analysis and the REDUCE clinical trial are perhaps the only studies to support short in-hospital regimens, and further research will probably be required to confirm this in special populations (e.g. patients with persistent bronchospasm). However, we consider that GesEPOC guidelines should include this patient population, and indicate that this treatment regimen is not limited to outpatients treated for COPD exacerbation.

References

- Miravittles M, Soler-Cataluña JJ, Calle MD, Molina J, Almagro P, Quintano JA, et al. Guía Española de la EPOC (GesEPOC). Actualización. Arch Bronconeumol. 2014;50 Suppl. 1:1–16.
- Pozo-Rodríguez F, López-Campos JL, Álvarez-Martínez CJ, Castro-Acosta A, Agüero R, Hueto J, et al. AUDIPOC Study Group. Clinical audit of COPD patients requiring hospital admissions in Spain: AUDIPOC study. PLoS ONE. 2012;7:e42156.
- Guía de práctica clínica para el diagnóstico y tratamiento de pacientes con enfermedad pulmonar obstructiva crónica (EPOC)-Guía Española de la EPOC (GesEPOC). Arch Bronconeumol. 2012;48 Suppl. 1:2–58.
- Leuppi JD, Schuetz P, Bingisser R, Bodmer M, Briel M, Drescher T, et al. Short-term vs conventional glucocorticoid therapy in acute exacerbations of chronic obstructive pulmonary disease. JAMA. 2013;309:2223–31.
- Cheng T, Gong Y, Guo Y, Cheng Q, Zhou M, Shi G, et al. Systemic corticosteroid for COPD exacerbations, whether the higher dose is better? A meta-analysis of randomized controlled trials. Clin Respir J. 2013;7:305–18.

Pedro J. Marcos,^{a,*} Arturo Huerta,^b Eduardo Márquez-Martín^c

^a Servicio de Neumología, Instituto de Investigación Biomédica de A Coruña (INIBIC), Complejo Hospitalario Universitario de A Coruña (CHUAC), SERGAS, A Coruña, Spain

^b Imperial College London Academic Unit of Respiratory Medicine at Royal Brompton Hospital, London, United Kingdom

^c Unidad Médico-Quirúrgica de Enfermedades Respiratorias, Hospital Virgen del Rocío, Sevilla, Spain

* Corresponding author.

E-mail address: pedro.jorge.marcos.rodriguez@sergas.es (P.J. Marcos).

with defined borders in the right lung base. She was referred to the Instituto Oncológico Nacional Dr. Juan Tanca Marengo, in Guayaquil, Ecuador. Lung auscultation revealed reduced breath sounds in the right lung base. Other physical examination parameters were normal. Hematology, biochemistry, tumor marker (CEA, CYFRA 21-1, NSE) and lung function test results were within normal values. Chest computed tomography (CT) showed a formation of soft tissues with attenuation coefficient for fat and irregular outline in the right posterior basal segment, containing a 4 cm × 3 cm macrocalcification. The patient underwent right thoracotomy, revealing a tumor in the right posterior basal section of the lung. Right lower lobectomy was performed, with no post-surgical complications. Pathology study of the sample reported intraparenchymal lipoma.

Pulmonary lipomas are thought to represent 0.1%–0.5% of all lung tumors. They occur within the bronchus and very occasionally in the lung periphery.¹ According to Watts, Clagget and MacDonald, lipomas in the lung parenchyma or below the pleura

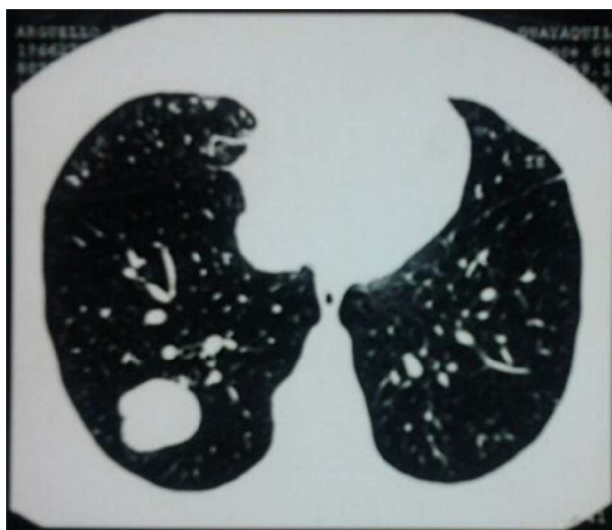

Fig. 1. Chest computed tomography showing soft tissue mass with attenuation coefficient for fat and irregular outline, containing a macrocalcification measuring 4 cm×3 cm.

may develop from the fat that is often found in the smaller bronchi.²

Few cases of peripheral intrapulmonary lipomas have been published, and the limited literature makes it difficult to diagnose these cases and provide appropriate treatment. Most cases recorded involve chance discovery and diagnosis after surgical resection. The first case reported in the literature, to the best of our knowledge, was a description of an autopsy finding by Buchmam in 1911.² In 1989, Hirata declared that the treatment of peripheral lipoma was limited to surgical intervention,³ while in 2004, Wood et al.³

found that surgical intervention for diagnostic purposes could be avoided by careful review of the radiological records. These same authors also pointed out that the differential diagnosis of a fatty peripheral pulmonary mass must include not only lipoma, but also fibrolipoma-hamartoma and liposarcoma.³

Our case was a patient with no previous radiological records and a radiopaque intrapulmonary mass, so the only reliable approach for reaching an accurate diagnosis and confirming or ruling out malignancy was pathological analysis (Fig. 1).

Conflict of Interests

We confirm that we have no conflict of interests with any constitutional government, that no pharmaceutical or medical company was involved in this report.

References

1. Sánchez-Font A, Pijuan L, Rodríguez-Rivera C, Vollmer I, Curull V. Tumores endobronquiales benignos infrecuentes. *Rev Esp Patol.* 2011;44:245–8. <http://dx.doi.org/10.1016/j.patol.2010.11.003>.
2. Touroff AS, Seley GP. Lipoma of the bronchus and the lung. A report of two unusual cases. *Ann Surg.* 1951;134:244–50.
3. Wood J, Henderson RG. Peripheral intrapulmonary lipoma: a rare lung neoplasm. *Br J Radiol.* 2004;77:60–2.

Norma Castro Ramírez,^a Fernando Cano Pazmiño,^b
Tannia Rivera Rivera^{b,*}

^a Servicio de Medicina Interna, Instituto Oncológico Nacional Dr. Juan Tanca Marengo, Guayaquil, Ecuador

^b Servicio de Neumología, Instituto Oncológico Nacional Dr. Juan Tanca Marengo, Guayaquil, Ecuador

* Corresponding author.

E-mail address: dramimo@hotmail.com (T. Rivera Rivera).

Situs Inversus With Pulmonary Atelectasis[☆]



Situs inversus asociado a atelectasia pulmonar

To the Editor,

Situs inversus totalis (SIT) is an uncommon congenital disease in which the positions of the chest and abdominal organs are reversed.¹ *Situs inversus* (SI) is an autosomal recessive genetic condition that occurs in only about 0.001%–0.01% of the general population.² This rare genetic anomaly is usually described or diagnosed by chance during chest or abdominal imaging procedures. We report a case of right pulmonary atelectasis in which the heart, spleen and liver were located right of midline.

A 46-year-old man, non-smoker with no particular complaints was referred to our department due to an abnormal chest X-ray showing dextrocardia and homogeneous opacity in the mid-right lung. Chest computed tomography (CT) showed segmentary atelectasis, extending from the right lower lobe to the right middle lobe (Fig. 1). Heart and spleen were also observed right of midline, while the liver was on the left. These findings were consistent with

SIT. Fiberoptic bronchoscopy revealed the lack of an upper lobe in the right lung, but it is interesting to note that the structure of the upper lobe of the left lung was normal, i.e., it had 3 segments;

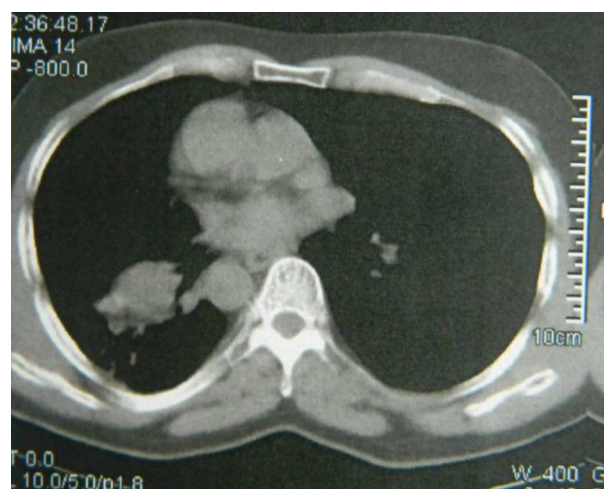


Fig. 1. Chest computed tomography showing segmentary atelectasis extending from the right lower lobe to the right middle lobe.

[☆] Please cite this article as: Şimşek A. *Situs inversus* asociado a atelectasia pulmonar. *Arch Bronconeumol.* 2015;51:361–362.