

recently study,² compliance is key to the success of noninvasive ventilation.

In our opinion, nighttime monitoring of patients is particularly important. While we agree that studies evaluating the benefits of polygraphy and/or polysomnography monitoring are needed, we are convinced that ventilator efficacy must be monitored in terms of PaCO₂, the value directly related with alveolar ventilation. Our belief, corroborated by other authors,³ is that this type of monitoring is essential. It is a routine practice in our clinic, and early morning arterial blood gases are measured in the patient on ventilation both at the start of the ventilation program and in all follow-up visits.

In brief, although the study is limited by the lack of data evaluating the impact of comorbidity, we believe that it is important to have been able to show in a long term study that the severity of ventilatory impairment is a factor for poor prognosis in patients with obesity-hypoventilation syndrome requiring noninvasive ventilation, while concomitant sleep apnea constitutes a protective factor. PaCO₂ monitoring is essential for ensuring effective ventilatory support and obtaining good outcomes.

Funding

No funding was received for this study.

Conflict of Interests

The authors state that they had no conflict of interests.

References

- Ojeda Castillejo E, de Lucas Ramos P, López Martín S, Resano Barrio P, Rodríguez Rodríguez P, Morán Caicedo L, et al. Ventilación mecánica no invasiva en pacientes con síndrome de obesidad-hipoventilación. Evolución a largo plazo y factores pronósticos. Arch Bronconeumol. 2015;51:61–8.
- Borel JC, Pepin JL, Pison C, Vesin A, González-Bermejo J, Court Fortune I, et al. Long-term adherence with non-invasive ventilation improves prognosis in obese COPD patients. Respirology. 2014;19:857–65.
- Berry RB, Chediak A, Brown LK, Finder J, Gozal D, Iber C, et al., NPPV Titration Task Force of the American Academy of Sleep Medicine. Best clinical practices for the sleep center adjustment of non invasive positive pressure ventilation NIPPV in stable chronic alveolar hypoventilation syndromes. J Clin Sleep Med. 2010;6:491–509.

E. Ojeda Castillejo,* P. de Lucas Ramos, P. Resano Barrios, S. López Martín, P. Rodríguez Rodríguez, L. Morán Caicedo, J.M. Bellón Cano, J.M. Rodríguez González-Moro

Hospital General Universitario Gregorio Marañón, Madrid, Spain

* Corresponding author.

E-mail address: e.ojeda.castillejo@gmail.com (E. Ojeda Castillejo).

Combination of Tracheal Bronchus and Partial Anomalous Pulmonary Venous Return in a Patient With Type 1 Neurofibromatosis and Ipsilateral Vagal Nerve Neurofibroma[☆]



Asociación de bronquio traqueal y drenaje venoso pulmonar anómalo parcial en paciente con neurofibromatosis tipo 1 y neurofibroma del nervio vago ipsilateral

To the Editor:

Type 1 neurofibromatosis (NF1) is the most common form of neurofibromatosis, a group of genetic disorders of the nervous system that mainly affect the development and growth of neural cell tissues. NF1 occurs in approximately 1 of every 3000 newborns. Transmission to progeny is by the autosomal dominant mode, although up to 50% of new cases occur spontaneously through *de novo* mutations. The literature describing the association of NF1 with cardiovascular or airway malformations is sparse.¹

We report a clinical case of a 45-year-old woman with a diagnosis of NF1, non-smoker, with dysphagia due to a posterior mediastinal tumor causing compression of the thoracic esophagus. On magnetic resonance imaging, the tumor was radiologically consistent with right vagal nerve neurogenic tumor. The physical examination only revealed café-au-lait spots on the skin and several scars on her back and abdominal wall from previously resected neurofibromas at these sites. In view of symptoms of progressive dysphagia, we decided to perform surgical resection of the posterior mediastinal tumor. The pre-operative chest X-ray revealed suspected tracheal bronchus (TB) (Fig. 1A), so these examinations were complemented with a chest computed tomography (CT). This

confirmed TB, and revealed the unexpected combination of partial anomalous pulmonary venous return (PAPVR), consisting of drainage from the right upper lobe vein into the superior vena cava (Fig. 1B–D).

The combination of NF1 with pulmonary development anomalies, either vascular or airway, and their diagnosis in adults is exceptional, and, to our knowledge, this the first report of simultaneous NF1, PAPVR and TB.¹ TB is one of the most common abnormalities of the bronchial tree and, despite its name, more often occurs in the right main bronchus than in the trachea itself. TB is generally diagnosed incidentally in asymptomatic patients undergoing bronchoscopy or chest CT for other reasons. It can, however, occasionally cause hemoptysis, recurrent lung infections, or right upper lobe atelectasis in intubated patients in whom the distal end of the endotracheal tube is located at or distal to the origin of the TB.² PAPVR is a vascular development anomaly consisting of abnormal drainage of one or more pulmonary veins into a systemic vein (the innominate vein, superior vena cava, azygos vein, right atrium, coronary sinus, or inferior vena cava), causing left-to-right shunt. Adults with PAPVR have a risk of developing long-term pre-capillary pulmonary hypertension due to volume overload in the right ventricle.³ The combination of these 2 development anomalies in a single patient is exceptional.⁴ The association of NF1 with pulmonary development anomalies is very rare (2.3%).¹ In a review of vascular and cardiac malformations in 2322 patients with NF1, pulmonary stenosis and aortic coarctation were more prevalent, but no cases of anomalous pulmonary vein drainage (partial or total) were identified.¹ Detection of these 2 anatomical variants may have clinical, anesthetic and therapeutic implications in patients scheduled for thoracic surgery. In our case, the anesthesiologist and the thoracic surgeon were aware of the anomalies, and complete thorascopic resection of the right mediastinal tumor with preservation of the ipsilateral vagal nerve could be planned and successfully performed. Histological examination confirmed a myxoid neurofibroma without atypia. The post-operative period was incident-free, and the patient was discharged 4 days after the intervention.

[☆] Please cite this article as: Gorospe Sarasúa L, Saldaña Garrido D, Ayala Carbonero AM. Asociación de bronquio traqueal y drenaje venoso pulmonar anómalo parcial en paciente con neurofibromatosis tipo 1 y neurofibroma del nervio vago ipsilateral. Arch Bronconeumol. 2015;51:305–306.

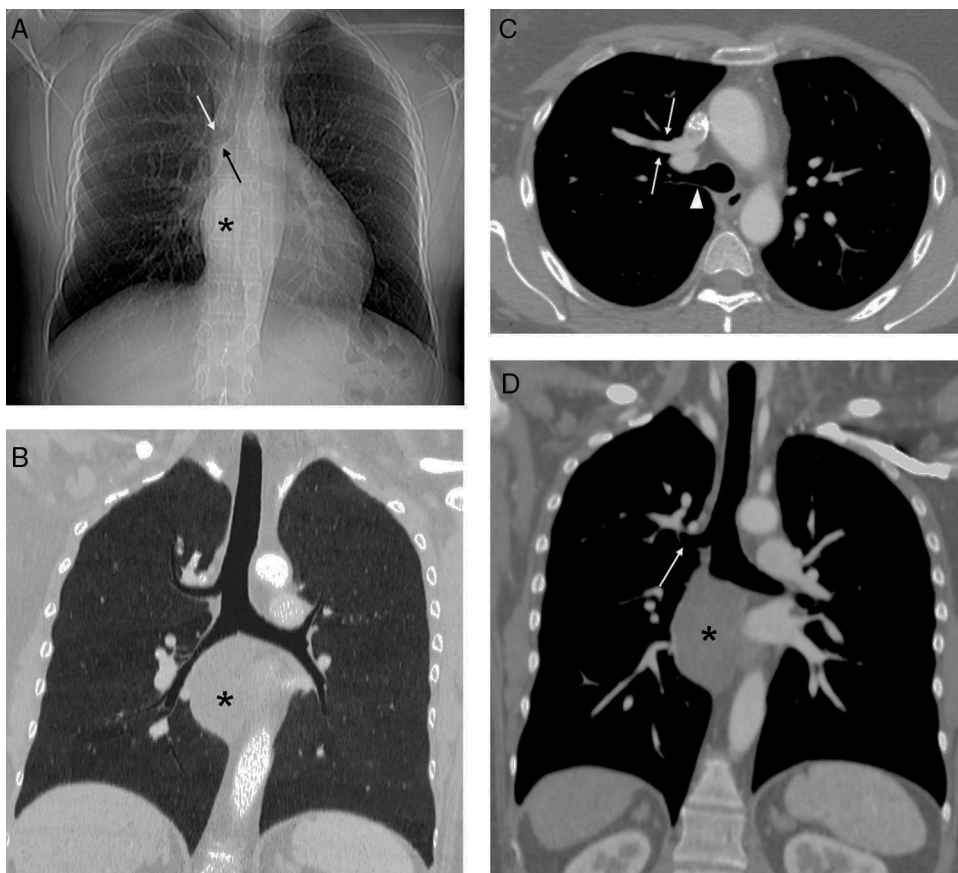


Fig. 1. (A) Chest X-ray showing a mediastinal mass (asterisk) obliterating the pleural-azygos-esophageal line and possible tracheal bronchus (arrows). (B) Minimum intensity projection coronal reconstruction confirming tracheal bronchus. Note the mediastinal mass (asterisk). (C) Axial chest computed tomography (CT) image with intravenous contrast medium, showing anomalous drainage from the right upper lobe pulmonary vein into the superior vena cava (arrows) and the tracheal bronchus (arrowhead). (D) Oblique CT coronal image with intravenous contrast medium showing tracheal bronchus (arrow) and the mediastinal mass (asterisk).

This is the first description in the scientific literature of TB and PAPVR in an NF1 patient with symptomatic mediastinal neurofibroma, and is therefore an exceptional case.

References

1. Lin AE, Birch PH, Korf BR, Tenconi R, Niimura M, Poyhonen M, et al. Cardiovascular malformations and other cardiovascular abnormalities in neurofibromatosis 1. *Am J Med Genet.* 2000;95:108–17.
2. Desir A, Ghaye B. Congenital abnormalities of intrathoracic airways. *Radiol Clin North Am.* 2009;47:203–25.
3. Zylak CJ, Eyler WR, Spizarny DL, Stone CH. Developmental lung anomalies in the adult: radiologic–pathologic correlation. *Radiographics.* 2002;22:S25–43.
4. Oshiro Y, Murayama S, Miyagi S, Nakamoto A, Ohta M, Ishikawa K. Simultaneous occurrence of partial anomalous pulmonary venous return and major bronchial

anomaly: computed tomography findings in 5 adult patients. *J Comput Assist Tomogr.* 2009;33:535–9.

Luis Gorospe Sarasúa,^{a,*} David Saldaña Garrido,^b
Ana María Ayala Carbonero^a

^a Servicio de Radiodiagnóstico, Hospital Universitario Ramón y Cajal, Madrid, Spain

^b Servicio de Cirugía Torácica, Hospital Universitario Ramón y Cajal, Madrid, Spain

* Corresponding author.

E-mail address: luisgorospe@yahoo.com (L. Gorospe Sarasúa).