

Histological analysis reported a tumor consisting of mature adipose cells with interspersed areas of thin collagen stroma. The tumor nucleus was necrotic. It was separated by a fibrous capsule from the rest of the lung parenchyma and the visceral pleura on one side and the adipose and muscle tissue (considered part of the pericardium and the diaphragm) on the other. The diagnosis, according to appearance on histology, was lipoma. The patient remains well, 4 months after surgery.

Intraparenchymal pulmonary lipomas do not appear to favor any lung lobe or side, and appear in both men and women aged from 26 to 81 years of age. Tumors previously described range in size from 1.3 cm to 7 cm in diameter.^{2–4}

The clinical course of these tumors is benign and they are generally asymptomatic. In rare cases such as ours, however, they present with paresthesia of the arm, mild dyspnea and lung dysfunction.^{3,4}

Peripheral pulmonary lipomas are indistinguishable from malignant tumors on chest X-ray. Computed tomography is thought to assist diagnosis, although it remains difficult for radiologists to determine the biological nature of the lesion.³

Treatment of solitary pulmonary nodules (including pulmonary lipomas) remains a topic for debate, because in none of the reported cases could malignancy be definitively ruled out. In general, they are surgically resected, the most common procedure being lobectomy.⁵

In our case, multislice computed tomography and intraoperative inspection of the lung showed an intraparenchymal pulmonary lesion in contact with the diaphragm, the pericardium and the parietal pleura, clinically mimicking a malignant tumor, so lobectomy was selected as treatment of choice. Despite their rarity, intraparenchymal pulmonary lipomas should be considered in the differential diagnosis of pulmonary nodules located in the lung periphery, for careful planning and adaptation of the surgical intervention.

Acknowledgements and Funding

The manuscript was written in the Dubrava University Hospital, Zagreb. No external funding was received. Our thanks to Stela Bulimbašić and Arijana Pačić for their advice during the preparation of this paper.

References

1. Kransdorf MJ. Benign soft-tissue tumors in a large referral population: distribution of specific diagnoses by age, sex, and location. *AJR Am J Roentgenol.* 1995;164:395–402.
2. Erkilic S, Kocer NE, Tuncozgun B. Peripheral intrapulmonary lipoma: a case report. *Acta Chir Belg.* 2007;107:700–2.
3. Wood J, Henderson RG. Peripheral intrapulmonary lipoma: a rare lung neoplasm. *Br J Radiol.* 2004;77:60–2.
4. Moran AM, Jian B, Min H, Pechet T, Fogt F. Peripheral intrapulmonary lipoma in a 26-year-old woman. A case report. *Pol J Pathol.* 2011;62:113–5.
5. Kim NR, Kim HJ, Kim JK, Han J. Intrapulmonary lipomas: report of four cases. *Histopathology.* 2003;42:305–6.

Jasna Bacalja,^{a,*} Igor Nikolić,^b Luka Brčić^{c,d}

^a Clinical Department of Pathology and Cytology, Dubrava University Hospital, Zagreb, Croatia

^b Clinical Department of Surgery, Dubrava University Hospital, Zagreb, Croatia

^c Institute of Pathology, School of Medicine, University of Zagreb, Zagreb, Croatia

^d Clinical Department of Pathology and Cytology, University Hospital Centre Zagreb, Zagreb, Croatia

* Corresponding author.

E-mail address: jasnabacalja@yahoo.com (J. Bacalja).

Migratory Pulmonary Nodules in a Patient With Ulcerative Colitis[☆]



Nódulos pulmonares migratorios en paciente con colitis ulcerosa

To the Editor:

Ulcerative colitis (UC) is an intestinal inflammatory disease occasionally associated with extraintestinal complications. We report here an atypical case of pulmonary manifestations of UC.

A 70-year-old man with a history of UC, stable in the last 5 years, receiving azathioprine, presented with a clinical picture of hemoptysis. Chest computed tomography (CT) was performed, revealing an 18-mm cavitated nodule in the right lower lobe. One month later, PET-CT was performed, showing nodule growth (19.5 mm) and hypermetabolism (SUV 5.77). Bronchoscopy was normal and lung function testing found mild, non-obstructive changes (FEV1/FVC 77, FEV1 [L] 2.22 [68%], FVC [L] 2.89 [65%]). Microbiology testing of endoscopy specimens, including auramine staining and *Mycobacterium tuberculosis* complex DNA detection, were negative. Four weeks later, the patient had another episode of hemoptysis and respiratory failure (pO₂ 52 mmHg). Repeat chest CT showed a 7-cm mass in the right upper lobe (RUL) (Fig. 1A). Pulmonary thromboembolism was ruled out by the contrast study. Bronchoscopy was

repeated, and was normal again, and cytology and microbiology results remained negative (direct detection and bacterial, fungal and mycobacterial cultures). Pulmonary abscess was suspected, so treatment began with clindamycin with good clinical response. However, the 3-month follow-up chest CT showed that while the 7-mm RUL lesion had resolved, a new cavitated nodule had appeared in the RUL (Fig. 1B). To rule out the association with the patient's gastrointestinal disease, colonoscopy was performed, showing mild UC. The immunological examination (including antinuclear and anti-neutrophil cytoplasmic antibodies) was negative.

In an attempt to determine diagnosis, pulmonary biopsy by thoracotomy was performed. Pathology laboratory reports showed sterile aggregates of neutrophils with areas of necrosis and foci of organizing pneumonia, with no evidence of vascular infiltration. These findings were thought to be indicative of UC lung involvement. Treatment began with prednisone 30 mg every 12 h for 2 weeks, with complete resolution of radiological signs (Fig. 1C).

UC is an inflammatory disease that affects the mucosa of the colon. It manifests mainly as diarrhea, abdominal pain and rectal bleeding.¹ However, in 10%–30% of cases, it can be associated with extraintestinal manifestations, particularly in the joints, skin and eyes. Pulmonary manifestations of UC are rare, multiple and non-specific.^{2,3} The most common symptoms are cough and wheezing.³ Our patient presented hemoptysis and respiratory failure, unusual in the published cases.^{2–4} Radiological findings also vary widely. The most common include bronchiectasis and ground-glass opacities.³ In our case, migratory cavitated pulmonary nodules

[☆] Please cite this article as: Barril S, Rodrigo-Troyano A, Giménez A, Sibila O. Nódulos pulmonares migratorios en paciente con colitis ulcerosa. *Arch Bronconeumol.* 2015;51:303–304.

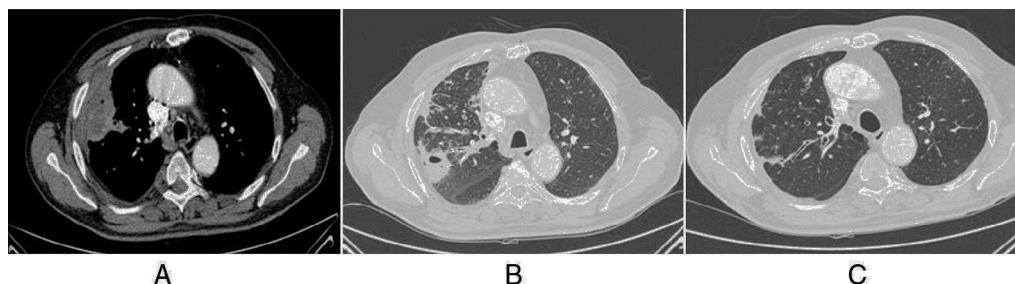


Fig. 1. (A) Pulmonary mass in the peripheral right upper lobe (RUL) of necrotic and abscessed appearance, containing a small air bubble (mediastinal window CT image). (B) Previously described nodule has disappeared, and a new cavitated nodule has appeared close by. Bronchial wall thickening and RUL bronchial impaction (lung window CT image). (C) Resolution of previous findings (follow-up lung window CT image).

were detected on CT, described elsewhere as very unusual.⁵ The most common histopathological changes are airway inflammation and bronchiectasis.² Our patient's lung biopsy revealed foci of organizing pneumonia and necrobiotic nodules. These necrotic areas, seen on CT as abscesses, appeared sporadically during our patient's clinical course. To date, flare-ups of organizing pneumonia associated with UC have been described,⁴ but necrobiotic nodules are rarer.² Treatment of UC lung involvement is based on corticosteroids.² Our patient's response to corticosteroids was excellent, with complete clinical and radiological resolution after 2 weeks of treatment.

To conclude, this is a case of pulmonary involvement of UC, with an interesting presentation, due to exacerbations occurring with hemoptysis, respiratory failure and radiological images of migratory cavitated pulmonary nodules, with no associated clinical symptoms. Definitive diagnosis was based on lung biopsy results and response to steroid treatment was complete.

Conflict of Interests

The authors state that they have no direct or indirect conflict of interests with the contents of this manuscript.

References

1. Danese S, Fiocchi C. Ulcerative colitis. *N Engl J Med.* 2011;365:1713–25.
2. Camus P, Colby TV. The lung in inflammatory bowel disease. *Eur Respir J.* 2000;15:5–10.
3. Black H, Mendoza M, Murin S. Thoracic manifestations of inflammatory bowel disease. *Chest.* 2007;131:524–32.
4. Storch I, Sachar D, Katz S. Pulmonary manifestations of inflammatory bowel disease. *Inflamm Bowel Dis.* 2003;9:104–15.
5. Carrascosa M, Salcines-Caviedes J, Millán MV, Martín MC, Murguiondo MZ, Gutiérrez PG, et al. Pulmonary nodules as respiratory manifestation of inflammatory bowel disease: case report and review. *Inflamm Bowel Dis.* 2011;17: E99–101.

Silvia Barril,^a Ana Rodrigo-Troyano,^a Ana Giménez,^b Oriol Sibila^{a,*}

^a Servei de Pneumologia, Departament de Medicina, Hospital Santa Creu i Sant Pau, Universitat Autònoma de Barcelona, Barcelona, Spain

^b Servei de Radiologia, Departament de Medicina, Hospital de la Santa Creu i Sant Pau, Universitat Autònoma de Barcelona, Barcelona, Spain

* Corresponding author.

E-mail address: osibila@santpau.cat (O. Sibila).

Mortality in Obesity-Hypoventilation Syndrome and Prognostic Risk Factors[☆]



Mortalidad en el síndrome de obesidad-hipoventilación y factores de riesgo pronóstico

To the Editor,

We read with interest the letter sent to ARCHIVOS DE BRONCONEUMOLOGÍA regarding our article “Noninvasive Mechanical Ventilation in Patients With Obesity Hypoventilation Syndrome. Long-term Outcome and Prognostic Factors”.¹ We would like to thank the authors and venture to respond.

We agree that the lack of comorbidity data is the greatest limitation of this study, particularly since the main aim was to define prognostic factors for predicting mortality. However, this aspect was not taken into account in the preliminary design of the database, and we rejected the idea of a retrospective search in the clinical records that would have reduced the quality of our

data. While including comorbidities in the analysis would have been interesting, this omission does not affect the results, namely, that patients with sleep apnea and those with better ventilatory function at the start of the ventilation program have the best prognosis.

With regard to the methodological concerns expressed by the authors of the letter, both initiation of ventilation and monitoring of ventilation mode comply with standard recommendations. Lowest pressure support (PS) was 10 cm H₂O, gradually increasing to 16, depending on arterial blood gases and tolerance. If 90% saturation could not be achieved with the initial PS, oxygen supplements were added until saturation was 90%, while FiO₂ was subsequently modified according to arterial blood gas and saturation achieved with the effective or maximum PS. The statistical tests for comparison were selected on the basis of the sample size and normal distribution, and nonparametric tests were used, assuming penalties.

Although all patients were included in the analysis of lung function and gas exchange outcomes until they left the ventilation program, the survival analysis was performed exclusively on patients who remained on ventilation until death (endpoint event). This means that patients who were withdrawn from the program due to poor compliance were not included in these analyses. As the authors of the letter rightly observe, and as confirmed in a

[☆] Please cite this article as: Ojeda Castillejo E, de Lucas Ramos P, Resano Barrios P, López Martín S, Rodríguez Rodríguez P, Morán Caicedo L, et al. Mortalidad en el síndrome de obesidad-hipoventilación y factores de riesgo pronóstico. *Arch Bronconeumol.* 2015;51:304–305.