

Severe Pneumonia Caused by *Rhodococcus equi* With Hematogenous Spread to the Central Nervous System in an Immunocompromised Patient[☆]



Neumonía grave por *Rhodococcus equi* con diseminación hematogena al sistema nervioso central en un paciente inmunodeprimido

To the Editor:

We report the case of a 59-year-old man who presented in the emergency room with a 48-h history of fever 38.8°C, dyspnea and cough. He had a prior diagnosis of cryptogenic organizing pneumonia and was receiving prednisone 70 mg/day and azathioprine 25 mg/day.

Physical examination showed fever 37.9°C, blood pressure 135/78 mmHg, breathing rate 28 breaths/minute and heart rate 103 beats/minute, with bilateral fine crackles on lung auscultation. Blood test results showed 16 600 leukocytes, 303 000 platelets, and normal serum biochemistry (including liver function tests and procalcitonin), with the exception of C-reactive protein 5.7 mg/dl. Baseline arterial blood gases were pO₂ 63 mmHg, pCO₂ 36 mmHg, pH 7.43 and oxyhemoglobin saturation 91%. Standard posteroanterior chest X-ray revealed cavitated alveolar infiltrate in the right upper lobe and infiltrate without cavitation in the left lower lobe (Fig. 1A).

Two blood cultures were performed, in aerobic and anaerobic media, and empirical treatment was started with piperacillin-tazobactam. Urine was negative for pneumococcal and *Legionella* antigens. After 4 days of antibiotic treatment without improvement, a chest–abdomen CT was performed, confirming previous radiological findings, with no other changes. *Rhodococcus equi* was isolated from both blood cultures, so based on susceptibility test results treatment was switched to imipenem, rifampicin and gentamicin. After 10 days of hospitalization, the patient began to complain of headache and instability, so magnetic resonance imaging (MRI) of the head was performed (Fig. 1B), revealing 8 cortical-subcortical nodular lesions, less than 1 cm in size, indicative of brain abscesses.

Intravenous treatment was maintained for 2 months, followed by 4 more months of oral azithromycin and trimethoprim-sulfamethoxazole. After 2 weeks of treatment, respiratory clinical signs had resolved and chest X-ray was normal. One month later, blood cultures were negative, and neurological signs had resolved. A follow-up head MRI at 3 months was normal.

There are more than 15 *Rhodococcus* species ubiquitous in the environment. They are strictly aerobic, intracellular Gram-positive coccobacilli that infect macrophages and polymorphonuclear cells. Some uncommon species, such as *R. luteus*, *R. erythropolis*, *R. ruber* and *R. rhodochrous*, mainly cause skin and corneal infections. *R. equi*, primarily transmitted via inhalation from contact with animals, is the most common and most pathogenic in humans. Cell immunosuppression is the major risk factor for infection, particularly in patients with acquired immunosuppression due to human immunodeficiency virus (HIV), although 10%–15% of infections occur in immunocompetent patients.^{1,2} The most common form of presentation in immunocompromised patients is cavitated pneumonia of the lower lobes³ (84%), while in immunocompetent patients, infections tend to be localized and extrapulmonary (42%),^{3,4} generally involving the central nervous system (abscesses, meningitis, etc.) and the skin (abscesses).

The respiratory process is insidious, manifesting as high fever, cough, dyspnea, chest pain and weight loss.² It is identified and diagnosed from the culture of affected tissue samples.⁴ Blood cultures are positive in 50% of immunocompromised subjects, as was the case for our patient, and in 10% of immunocompetent subjects.⁵ There is no standard treatment. *Rhodococcus* is resistant to betalactams, except for imipenem, and susceptible to macrolides, rifampicin, aminoglycosides and vancomycin. Susceptibility to fluoroquinolones, clindamycin, trimethoprim-sulfamethoxazole and tetracyclines is variable.^{1,5} Treatment with 2 or 3 drugs is recommended, of which at least 1 should have good intracellular activity, such as rifampicin or azithromycin.^{4,5}

In immunocompetent subjects with localized infection, successful outcomes have been reported with a combination of 2 antibiotics for 2–8 weeks.² Treatment can be extended for up to 6 months¹ if the patient remains immunocompromised, and in cavitated pulmonary lesions or CNS involvement, as occurred in our case.

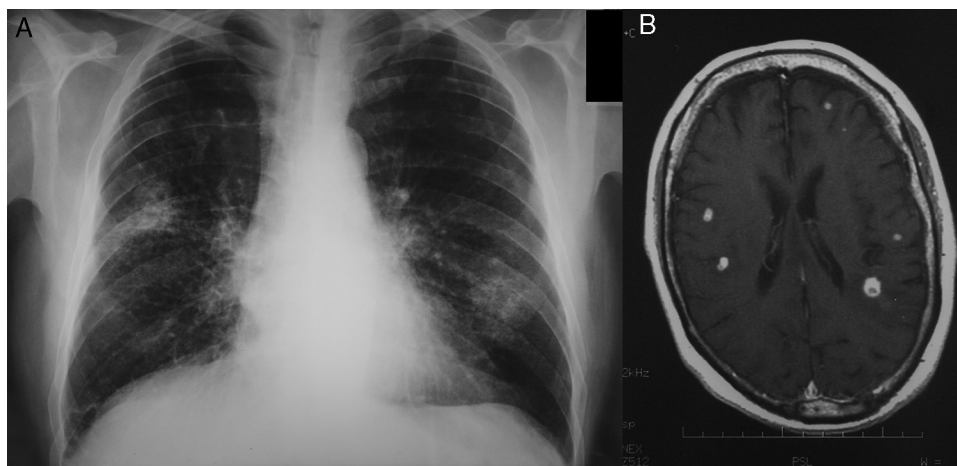


Fig. 1. (A) Chest X-ray showing cavitated infiltrate in upper right lobe and infiltrate without cavitation in lower left lobe. (B) Head MRI showing multiple nodular lesions, less than 1 cm in size, in the cortical-subcortical region, and vasogenic edema.

[☆] Please cite this article as: Enríquez Rodríguez AI, García Clemente M, Buchelli Ramírez HL. Neumonía grave por *Rhodococcus equi* con diseminación hematogena al sistema nervioso central en un paciente inmunodeprimido. Arch Bronconeumol. 2015;51:203–204.

Mortality in immunocompetent patients is 11%, while in HIV patients it is 50%–55%, and 20%–25% in non-HIV-infected immunocompromised patients.^{2–4}

References

1. Weinstock DM, Brown AE. *Rhodococcus equi*: an emerging pathogen. *Clin Infect Dis*. 2002;34:1379–85.
2. Kedlaya I, Ing MB, Wong SS. *Rhodococcus equi* infections in immunocompetent hosts: case report and review. *Clin Infect Dis*. 2001;32:e39–47.
3. Ng S, King CS, Hang J, Clifford R, Lesho EP, Kuschner RA, et al. Severe cavitary pneumonia caused by a non-*equi* *Rhodococcus* species in an immunocompetent patient. *Respir Care*. 2013;58:e47–50.
4. Moya-Mateo EM, Canora Lebrato J, Galindo-Andugar MA, García-Largacha M. Neumonía por *Rhodococcus equi* en un paciente en tratamiento con glucocorticoides. *Med Clin (Barc)*. 2006;127:197–8.

5. Verville TD, Huycke MM, Greenfield RA, Fine DP, Kuhls TL, Slater LN. *Rhodococcus equi* infections of humans. 12 cases and a review of the literature. *Medicine (Baltimore)*. 1994;73:119–32.

Ana Isabel Enríquez Rodríguez,* Marta García Clemente, Herminia L. Buchelli Ramírez

Área de Gestión Clínica del Pulmón, Neumología, Hospital Universitario Central de Asturias, Oviedo, Asturias, Spain

* Corresponding author.

E-mail address: anaisenriquez@hotmail.com

(A.I. Enríquez Rodríguez).

Respiratory Acidosis Secondary to Drug Therapy[☆]



Acidosis respiratoria secundaria a fármacos

To the Editor:

The use and combination of different central nervous system (CNS) depressants in elderly patients is a growing practice. This therapy is not without its complications, most notably respiratory center depression and respiratory acidosis requiring ventilatory support. It is therefore essential to be aware of these complications and identify which patients are at greater risk.

We present the findings from a series of patients admitted to the Respiratory Monitoring Unit of the Hospital Universitario de La Princesa (Madrid) over a period of 2 years. During this time, 302 patients were admitted with respiratory acidosis. A study of their medical records and urinalysis showed that in 10 cases (3.3%) the condition was associated with the use of CNS depressants. The doses given were estimated from clinical interview with the patient and/or carer, and in all cases drug-specific antagonists were used, together with non-invasive mechanical ventilation (NIV). Patients requiring emergency orotracheal intubation, patients transferred to the Intensive Care Unit for monitoring or intensive care, and those in whom NIV was ruled out by the Respiratory Medicine Department (approximately 12% of all patients admitted for respiratory acidosis) were excluded from the series. At admission, mean pH was 7.28 and mean PaCO₂ was 69.4 mmHg, both determined by arterial blood gas measurement. In many cases, progress was determined by other hypoventilation factors.

All patients included in the series were women with a mean age of 78.9 years. Of these, 80% were under treatment for a depressive syndrome, and 50% regularly took more than 2 CNS depressants. The combination drugs given were benzodiazepines (BZD), in 50%, and opiates, in 10%. This combination was responsible for 30% of cases. Predisposing factors, in addition to the therapy given, were found in 80% of patients (obesity in 60%, chronic obstructive pulmonary disease [COPD] in 30%, and kyphoscoliosis in 20%). In 1 case, drug toxicity was the result of an attempted suicide, and the patient died (Table 1).

BZDs are anxiolytic, hypnotic, anticonvulsant and antispasmodic drugs that enhance the inhibitory action of gamma-aminobutyric acid (GABA) receptors in the CNS. Opiates specifically bind to different central and peripheral receptors to regulate pain, amongst other actions. The use of these drugs, particularly in combination, inhibits the activity of the medullary and bulbopontine respiratory centers, which in turn diminishes the ventilatory response to hypoxia and hypercapnia, and can cause respiratory acidosis.^{1,2} This is particularly important in elderly patients with chronic pulmonary disease.³ Recent studies in patients with severe COPD have shown that high dose BZDs and opiates are associated with increased mortality.⁴ Long-term use of BZDs has also been associated with onset of acute hypercapnic respiratory failure in obese patients with sleep apnea/hypopnea syndrome (SAHS).⁵

In conclusion, patients with alveolar hypoventilation (SAHS, obesity, COPD) taking CNS depressants (BZD, opiates, etc.) alone or in combination are at greater risk of respiratory acidosis. It is important to bear this in mind when considering the use of these drugs in this high-risk population.

Table 1
Clinical Characteristics of the Sample.

Case	Age (years)	Sex	Main comorbidities	Caused by	Progress
1	89	F	Depressive syndrome, HT, obesity	BZD, opiates	Satisfactory
2	72	F	Depressive syndrome, obesity, COPD	BZD, TCA	Satisfactory
3	82	F	HTN, angina, renal failure	Pregabalin, opiates	Satisfactory
4	76	F	Depressive syndrome, kyphoscoliosis, obesity, COPD	BZD, opiates	Satisfactory
5	51	F	Pulmonary sarcoidosis, depressive syndrome	BZD, paroxetine	Satisfactory
6	64	F	COPD, lung neoplasm	BZD, opiates	Exitus
7	85	F	Atrial fibrillation, kyphoscoliosis, depressive syndrome, obesity	BZD	Satisfactory
8	89	F	Depressive syndrome, HT	BZD	Satisfactory
9	90	F	Depressive syndrome, obesity	BZD	Satisfactory
10	91	F	Depressive syndrome, CHF, obesity	Opiates	Satisfactory

BZD: benzodiazepines; CHF: congestive heart failure; COPD: chronic obstructive pulmonary disease; F: female; HTM: hypertension; TCA: tricyclic antidepressants.

[☆] Please cite this article as: Alonso T, García E, Segrelles G, Zamora E. Acidosis respiratoria secundaria a fármacos. *Arch Bronconeumol*. 2015;51:204–205.