

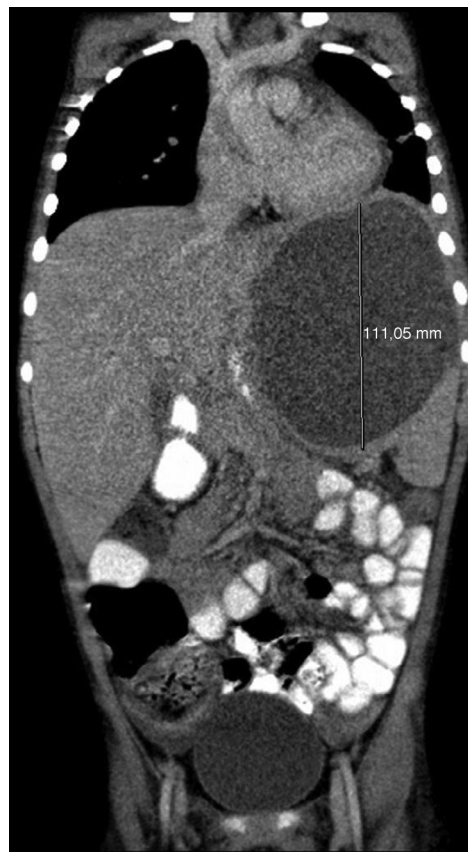
Letters to the Editor

**Pulmonary Consolidation Versus Splenic  
Abscess Due to *Salmonella enterica*\***



**Condensación pulmonar versus absceso esplénico por  
*Salmonella***

Splenic abscesses (SA) are unusual extraintestinal manifestations of salmonellosis, mainly due to *S. typhi*, *S. typhimurium* and *S. paratyphi*.<sup>1</sup> These abscesses are difficult to diagnose due to their low incidence and nonspecific symptoms, and mortality is high if they are not treated early. They often develop on preexisting lesions, are directly related or secondary to hematologic disease, hemoglobinopathies or injuries, and present with concurrent bacteremia or endocarditis.<sup>2</sup> Up to 80% of chest X-rays show changes, and up to 30% of cases involve left pleural effusion.<sup>3</sup> We report the case of a 5-year-old patient presenting with short-term fever and abdominal pain 2 weeks after a diagnosis of gastroenteritis due to *Salmonella* spp. In view of suspected typhoid fever, intravenous ampicillin was administered (150 mg/kg/day). Clinical laboratory test results showed leukocytes 24 580  $\mu$ l (neutrophils 21 150  $\mu$ l), C-reactive protein (CRP) 28.5 mg/dl and procalcitonin 5.63  $\mu$ g/ml. Fever and hypoventilation in the left lung base persisted, so a chest X-ray was performed. Basal pneumonia with parapneumonic effusion was diagnosed, and cefotaxime was administered intravenously (200 mg/kg/day). Ultrasound of the chest and abdomen showed effusion without lung involvement and a splenic cyst (79 mm  $\times$  74 mm) (Fig. 1). A follow-up ultrasound showed increased effusion, left basal pulmonary consolidation and elevated diaphragm, secondary to splenic cyst. Ampicillin-resistant *Salmonella enterica* serotype *Enteritidis* was isolated from a fecal culture. Pleural drainage fluid contained red blood cells 1440/mm<sup>3</sup>, leukocytes 29 610/mm<sup>3</sup> (90% polynuclear), glucose 41 mg/dl, protein 3.4 g/dl and lactic acid 32 mg/dl. Gram stain, culture, CRP and pneumococcal antigen were negative. The patient worsened unexpectedly, so a chest-abdomen ultrasound was performed, revealing an increase in cyst size. After contrast-enhanced abdominal computed tomography (CT), the splenic abscess was drained and *Salmonella* spp. (same type and sensitivity) were isolated from drainage fluid. Drainage was repeated due to abdominal pain and cyst enlargement. This time, the culture was negative and capsulectomy was scheduled. Antibiotic therapy was switched to meropenem (48 mg/kg/8 h). Progress was favorable, and minimal pleural thickening without effusion was seen on the chest-abdomen CT, while no images suggestive of cyst were seen on ultrasound. The initial prescription of ampicillin in our case is questionable, given the considerable rate of resistance (40% in our hospital). The early switch to cefotaxime, initiated due to



**Fig. 1.** Abdominal ultrasound showing spleen with cyst 79 mm  $\times$  74 mm, with echogenic contents, occasional ducts, and thickened, polylobulated walls.

radiological findings initially interpreted as pneumonia, may have prevented a poor outcome, but on the other hand, this erroneous interpretation complicated the diagnosis. Chest X-ray is a sensitive imaging technique for directing attention toward the left upper quadrant, but it lacks specificity for the diagnosis of splenic abscess. As a result, the pleural effusion observed is interpreted, as in this case, as a clinical sign of pneumonia, thus delaying the real diagnosis. Abdominal CT is the technique of choice in the case of suspected splenic abscess, and its use has improved detection of this disease. Incidence has also increased due to the greater prevalence of immunosuppressive states, producing more reports in recent series of fungal etiologies.<sup>3,4</sup> In this respect, our case is uncommon, due to the lack of predisposing factors, such as immunosuppression or endocarditis. Conventional treatment is antibiotic therapy and total or partial splenectomy, although percutaneous drainage may be considered in patients with contraindications for surgery.<sup>5</sup>

\* Please cite this article as: González-Abad MJ, Alonso Sanz M. Condensación pulmonar versus absceso esplénico por *Salmonella*. Arch Bronconeumol. 2016;52:169–170.

## References

1. Chaudhry R, Mahajan RK, Diwan A, Khan S, Singhal R, Chandel DS, et al. Unusual presentation of enteric fever: three cases of splenic and liver abscesses due to *Salmonella typhi* and *Salmonella paratyphi A*. *Trop Gastroenterol*. 2003;24:198–9.
2. Edelson K. A 6-year-old boy with shoulder pain. *Pediatric Annals*. 2011;40:342–4.
3. Nelken N, Ignatius J, Skinner M, Christensen N. Changing clinical spectrum of splenic abscess. A multicenter study and review of the literature. *Am J Surg*. 1987;154:27–34.
4. Debeuckelaere S, Schoors DF, Buydens P, Du Ville L, Spapen HD, Reynaert HM, et al. Splenic abscess: a diagnostic challenge. *Am J Gastroenterol*. 1991;86:1675–8.
5. Choudhury SR, Debnath PR, Jain P, Kushwaha AS, Puri A, Chadha R, et al. Conservative management of isolated splenic abscess in children. *J Ped Surg*. 2010;45:372–5.

María José González-Abad,\* Mercedes Alonso Sanz

Sección de Microbiología, Servicio de Análisis Clínicos,  
Hospital Infantil Universitario Niño Jesús, Madrid, Spain

\* Corresponding author.

E-mail address: mjglezabad@yahoo.es (M.J. González-Abad).

## Use of Pectus Bars in the Reconstruction of Complex Anterior Chest Wall Defects<sup>☆</sup>



### Uso de barras de pectus en la reconstrucción de defectos complejos de la pared torácica anterior

To the Editor,

*En bloc* resection of chest wall tumors with wide margins can generate wall defects which affect structural function and interfere in respiratory mechanics. Restoration of wall integrity is a surgical challenge, due to the complexity of reconstructing the structural rigidity of the thoracic cage, while preserving the elasticity required for the mechanics of breathing.<sup>1</sup>

We report the case of an 84-year-old woman who underwent resection of a giant chondrosarcoma. We were able to reconstruct the resulting large chest wall defect using a previously unpublished technique, which meets both rigidity and elasticity requirements.

The resection included the tumor, skin, soft tissue, ribs 2–5, and the lateral half of the sternum (Fig. 1). The resulting large chest wall defect was repaired using preformed surgical steel bars usually used for video-assisted surgical correction of congenital

deformities of the chest wall (Walter Lorenz®). The bars were placed to mimic the form of the costal arches, and fixed using Dall-Miles® cerclage with steel cables and dedicated stabilizers screwed to the remaining sternum (Fig. 1). Polytetrafluoroethylene (PTFE) mesh (Gore-Tex®) was used to seal the pleural cavity (Fig. 1). No perioperative complications occurred, and 4 years after the intervention the patient remains symptomatic with no signs of tumor relapse.

Chest wall defect repair with biological substitutes or prosthetics is necessary when the defect is greater than 4 costal arches or 5 cm, and is of particular significance when the resection involves the anterior chest wall, as in our case. Most of the rigid prostheses and metal meshes or cement<sup>2</sup> currently available for reconstruction provide the necessary rigidity but lack the necessary elasticity, while commercially available rib substitutes provide better thoracic compliance, but are limited in terms of length and rigidity.

In our case, the pectus bars were long enough to repair the large chest wall defect, while the stabilizers we used provided secure and stable fixation of the bars to the remaining sternum. Moreover, subsequent fixing of the bars with steel cable gave added stability. From a mechanical point of view, shaping the bars in the form of

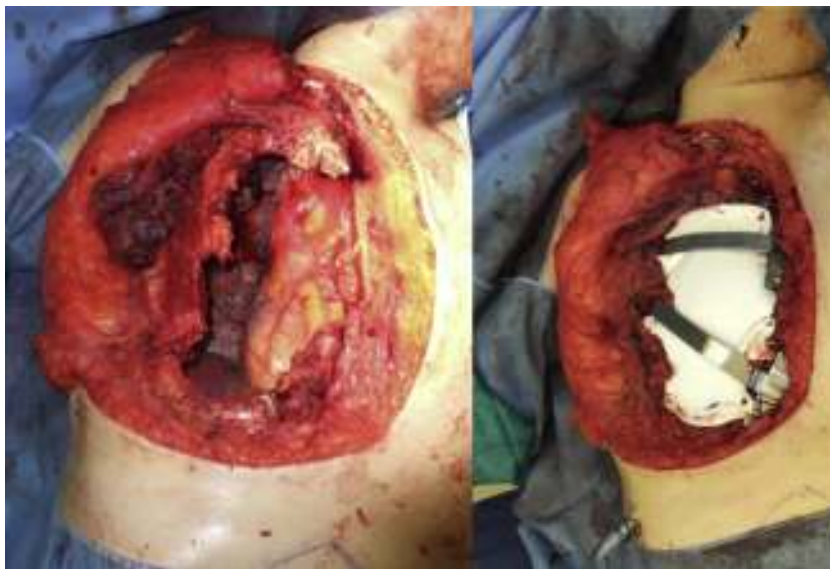

Fig. 1. Large chest wall defect after resection. Reconstruction with 2 pectus bars and PTFE mesh.

<sup>☆</sup> Please cite this article as: Hernández Escobar F, Pérez Alonso D, Cano García JR, Quevedo Losada S, López Rivero L. Uso de barras de pectus en la reconstrucción de defectos complejos de la pared torácica anterior. *Arch Bronconeumol*. 2016;52:170–171.