

References

1. Barquero-Romero J, Redondo-Morales MJ. Spontaneous pneumomediastinum and subcutaneous emphysema: an uncommon complication of lung cancer. Arch Bronconeumol. 2009;45:310–1.
2. Libeer C, Verbeken E, de Wever W, Vansteenkiste J, Nackaerts K. Mediastinal emphysema and small cell lung cancer (SCLC): a case-report. Lung Cancer. 2005;47:139–42.
3. Khan S. A case of mediastinal emphysema in a 80-year old male. Lung Cancer. 2006;51:391–2.
4. Craig SR, Walker WS. Pneumomediastinum: an unusual presentation of carcinoma of the carina. Respir Med. 1995;89:385–6.

Jan Kara,* Sarka Klimesova, Norbert Pauk
 Department of Pneumology and Thoracic Surgery, Third Faculty of
 Medicine, Charles University, University Hospital Na Bulovce, Praga,
 Czech Republic

* Corresponding author.

E-mail address: jan.kara@seznam.cz (J. Kara).

Giant Teratoma Presenting With Pregnancy and Causing Respiratory Failure[☆]



Teratoma gigante manifestado en el embarazo y causante de insuficiencia respiratoria

To the Editor,

Pregnancy is associated with certain specific physiological adaptations and some atypical symptoms can be misdiagnosed during this period, leading to serious complications, particularly if pregnancy is associated with tumor disease.

We report the case of a 21-year-old pregnant woman, admitted to the emergency department of our hospital with severe chronic dyspnea, minimal hemoptysis and premature labor. She was in week 28 of gestation, gravida 1, para 0. Gynecological examination revealed dilated external cervical orifice. SaO₂ was 90% and blood pressure 90 mmHg/60 mmHg. Chest auscultation revealed absence

of respiratory sounds in the left hemithorax, which was totally opaque on minimal exposure chest X-ray. Thoracocentesis was performed immediately, and a left chest tube was left in place to reduce dyspnea, producing 1500 cc of serous-sanguineous pleural fluid. Corticosteroid (betamethasone) was administered to accelerate fetal lung maturation. Three days later, after stopping premature labor, a Cesarean section was successfully performed with the birth of a healthy boy. Chest computed tomography (CT) and magnetic resonance imaging (MRI) (Fig. 1) revealed a mediastinal tumor occupying the whole left hemithorax, with massive right mediastinal shift. The tumor contained cystic spaces and discrete areas of soft tissue and fat, consistent with probable mature teratoma. Serum alpha-fetoprotein (AFP) and human chorionic gonadotropin (hCG) levels were normal. During posterolateral thoracotomy, the giant tumor was seen to have adhesions to the left lung, which was completely collapsed. The tumor contained organoid structures (hair), consistent with teratoma (Fig. 1b). Surprisingly, good lung re-expansion was achieved after full tumor resection (Fig. 1c).

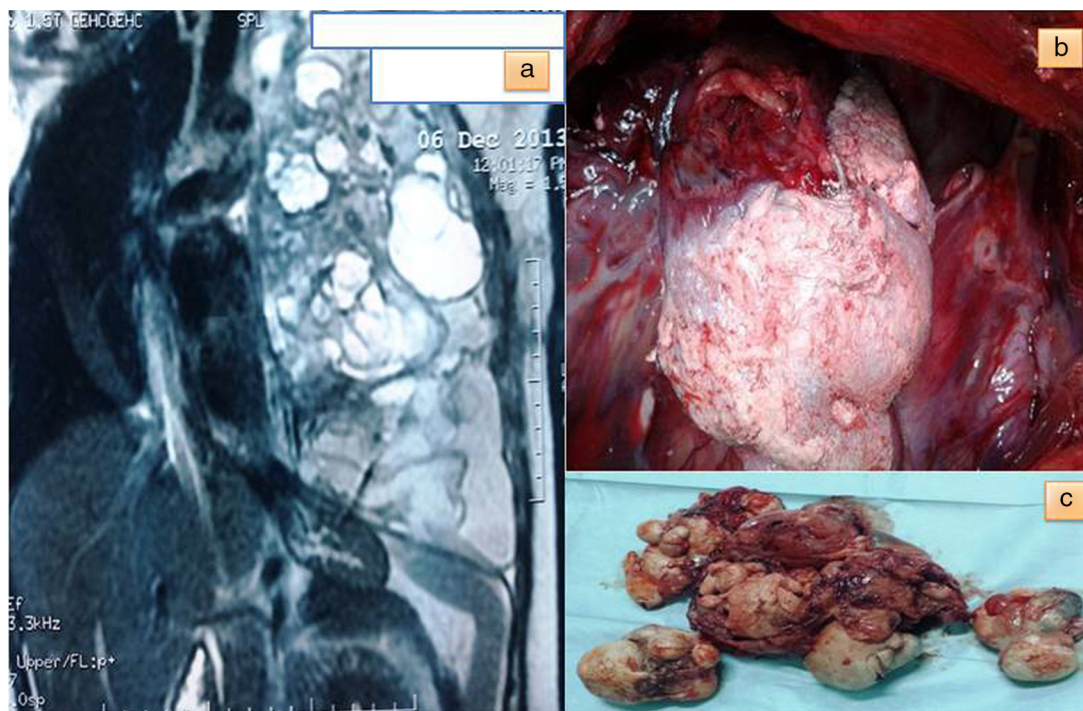


Fig. 1. (a) Chest magnetic resonance image of a massive tumor in the left hemithorax, with fat, cystic spaces and organoid structures; (b) perioperative image of the tumor with hair-like structures, and (c) macroscopic image of the fully resected teratoma.

[☆] Please cite this article as: El Hammoui M, Benosman A, Kabiri EH. Teratoma gigante manifestado en el embarazo y causante de insuficiencia respiratoria. Arch Bronconeumol. 2015;51:250–251.

Histological diagnosis was mature teratoma. Positive estrogen and progesterone receptors were detected in resected tumor tissue.

Sixty percent of teratomas are located in the anterior mediastinum, and 88% are mature.¹ Mature teratoma is often asymptomatic and protrudes from one hemithorax. On CT, it is seen as a mass containing fat, calcifications or cystic changes. The benign nature of these lesions is confirmed by lack of activity on FDG-PET.² MRI is useful for obtaining an accurate map of surrounding anatomical structures for surgical resection of the tumor.

The only curative treatment available for teratoma is surgical intervention, usually performed via sternotomy or thoracotomy, to relieve symptoms of compression and prevent transformation to malignancy.

Correct diagnosis and treatment are based on total tumor resection, although complete resection is not essential, since the local recurrence rate is low.³ Adjuvant treatment is unnecessary, as prognosis for mature teratoma is good.⁴

In pregnant women, radiation applied to the chest is considered safe if the abdomen is protected,⁵ so chest X-ray is formally indicated to avoid misdiagnosis of unexplained dyspnea in a pregnant woman.

This large chest tumor causes decline in lung function, and pleural effusion may increase due to hormone changes and mechanical factors associated with pregnancy.

To conclude, the appearance of these tumors during pregnancy is likely to involve real diagnostic and therapeutic issues.

Conflict of Interest

The authors have no conflict of interests to declare.

References

1. De Bournonville C, Maugendre S, Belleguic C, Corbineau T, Lena H, Desrues B, et al. Têratome mature du médiastin: à propos de deux cas. *Rev Pneumol Clin.* 1999;55:177–80.
2. Kikawa S, Todo Y, Minobe S. Growing teratoma syndrome of the ovary: a case report with FDG-PET findings. *J Obstet Gynaecol Res.* 2011;37:926–32.
3. Asteriou C, Barbetakis N, Kleontas A, Konstantinou D. Giant mediastinal teratoma presenting with paroxysmal atrial fibrillation. *Interact Cardiovasc Thorac Surg.* 2011;12:308–10.
4. Karangelis D, Kalafati G, Liouras V, Tsilimingas N. Germ cell tumors of the mediastinum. *Interact Cardiovasc Thorac Surg.* 2010;11:829.
5. Osei EK, Faulkner K. Fetal doses from radiological examinations. *Br J Radiol.* 1999;72:773–80.

Massine El Hammoumi,^{a,c,*} Abdelatif Benosman,^{b,c}
El Hassane Kabiri^{a,c}

^a Department of Thoracic Surgery, Mohamed V Military University Hospital, Rabat, Morocco

^b Department of Thoracic Surgery, Avicenne Hospital, Rabat, Morocco

^c Centre d'étude doctorale des sciences de la vie et de la santé, Faculté de médecine, Université Mohammed V Souissi, Rabat, Morocco

* Corresponding author.

E-mail address: hamoumimassine@hotmail.fr (M. El Hammoumi).

Talking About Endobronchial Lipoma[☆]



A propósito del lipoma endobronquial

With reference to the article “Endobronchial Lipoma: A Rare Cause of Bronchial Occlusion”,¹ we report the case of a 64-year-old man with a previous diagnosis of severe obstructive sleep apnea-hypopnea syndrome receiving CPAP therapy, who presented with a clinical picture of long-standing productive cough. Increased density with upper right paratracheal rounded mass was observed on chest X-ray; chest computed tomography showed partial atelectasis of the right upper lobe (RUL); bronchoscopy showed a soft, rounded, pinkish, vascularized lesion in the entrance to the RUL; biopsy revealed metaplastic bronchial mucosa; and pathological contrast uptake was seen on positron emission tomography (PET). With a diagnosis of a RUL lesion with uptake on PET, a thoracotomy with upper right lobectomy and lymphadenectomy was performed. Pathology report revealed endobronchial lipoma with focal osseous metaplasia, alveolar hemorrhage, areas of bronchopneumonia and obstructive architectural distortion.

Discussion

Endobronchial lipoma is a very rare tumor, accounting for only 0.1% of all lung tumors.² They are usually located in the first 3 divisions of the tracheobronchial tree. The most common symptoms

are cough, expectoration, hemoptysis, fever and dyspnea, although 25% of cases may be asymptomatic.³ The lipoma consists of mature fatty tissue covered with normal bronchial epithelium or—as in our case—squamous metaplasia.⁴ Fibrous, glandular tissue, areas of cartilage or osseous metaplasia can also be found in the lipoma; pathologist must use differential diagnosis to rule out atypical lipomatous tumors and well-differentiated liposarcomas.⁵ Treatment of choice is bronchoscopic resection, while thoracotomy should be considered in difficult-to-diagnose cases, when there is parenchymal destruction due to atelectasis and long-standing pneumonitis, extrabronchial growth, or if bronchoscopy cannot be used for technical reasons.⁶ Nevertheless, in view of the possibility of long-term relapse, we recommend regular follow-up of patients undergoing bronchoscopic resection.

References

1. Lirios Sacristán B, Fernández Robledo E, Peña Blas F. Lipoma endobronquial: una causa infrecuente de obstrucción bronquial. *Arch Bronconeumol.* 2014;50:78–9.
2. Marcote Valdivieso E, Baltasar Torrejón A, Bou Pérez R, Vierna García J. Lipoma endobronquial. *Cir Esp.* 1990;4:460–4.
3. Huisman C, Van Kralingen KW, Postmus PE, Sutedja TG. Endobronchial lipoma: a series of three cases and the role of electrocautery. *Respiration.* 2000;67:689–92.
4. Boland JM, Fritchie KJ, Erickson-Johnson MR, Oliveira AM, Colby TV, Folpe F A.L. Endobronchial lipomatous tumors: clinicopathologic analysis of 12 cases with molecular cytogenetic evidence supporting classification as “lipoma”. *Am J Surg Pathol.* 2013;37:1715–21.

[☆] Please cite this article as: Guelbenzu Zazpe JJ, Ramírez Gil E, Vilá Mayo E. A propósito del lipoma endobronquial. *Arch Bronconeumol.* 2015;51:251–252.