



## Clinical Image

## Diagnosis of Peritoneal-pleural Communication by Peritoneography With $^{99m}\text{Tc}$ -sulfur Colloid in a 3-year-old Girl With Congenital Nephrotic Syndrome of the Finnish Type<sup>☆</sup>



### Diagnóstico de comunicación peritoneo-pleural mediante peritoneograma isotópico con $^{99m}\text{Tc}$ -sulfuro coloidal en una niña de 3 años con síndrome nefrótico congénito tipo finlandés

Francisco Javier García Gómez,\* Andrés Martínez Esteve, Juan Luis Tirado Hospital

Servicio de Medicina Nuclear, Hospital Universitario Virgen del Rocío, Sevilla, Spain

Around 5% of patients receiving renal replacement therapy in Spain are on peritoneal dialysis. Anatomical integrity of the peritoneum is essential since increased hydrostatic pressure due to peritoneal accumulation of dialysis fluid predisposes to abdominal or pelvic hernias or chest leakage via the embryonic pneumatoenteric recess.<sup>1</sup>

We report the case of a 3-year-old girl with a history of Finnish-type congenital nephrotic syndrome, receiving post-nephrectomy peritoneal dialysis since the age of 2. Fourteen months after starting peritoneal dialysis, she was admitted to our hospital due to severe dyspnea, with massive right hydrothorax on chest X-ray. To rule out pleuroperitoneal leak, a peritoneal

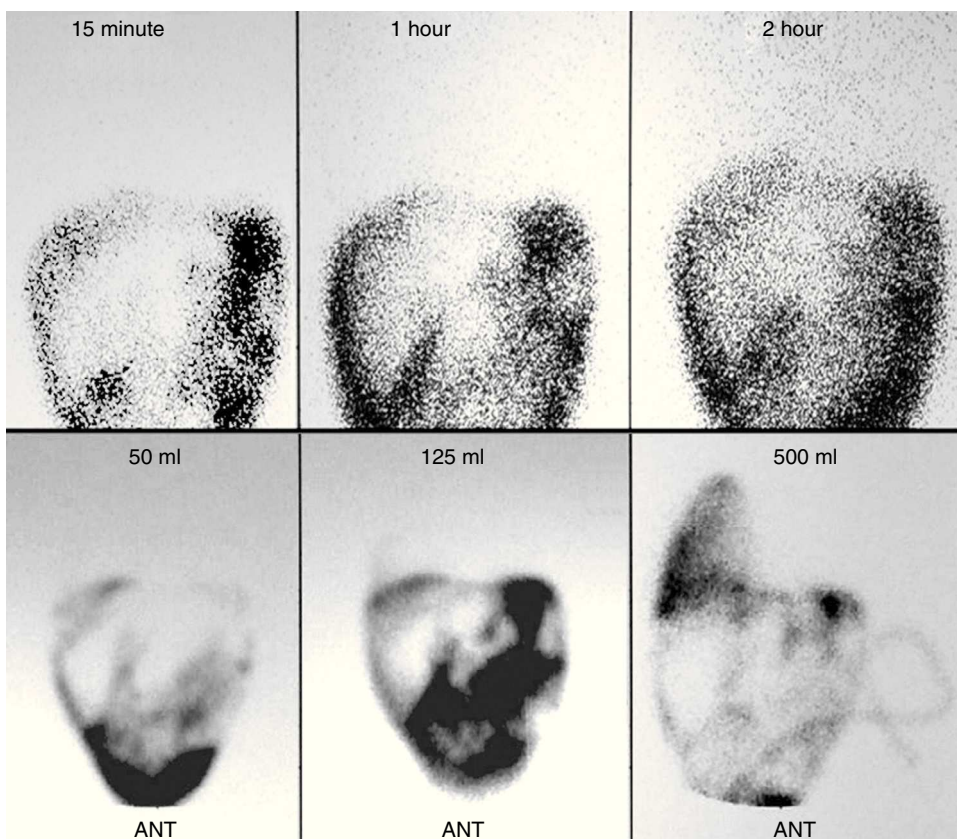
scintigraphy was performed during dialysis after instillation of 37 MBq of  $^{99m}\text{Tc}$ -sulfur colloid in 450 cc of dialysis solution (upper image), which was negative for pleuroperitoneal communication. One month later, after readmission for respiratory distress, hypoventilation, and right hydrothorax, isotopic peritoneography was repeated (lower image), and found to be positive after administration of 125 cc of dialysis solution. On this basis, the patient was transferred definitively to hemodialysis (Fig. 1).

We demonstrate the utility of isotopic peritoneography as a non-invasive, safe, and simple method of detecting pleuroperitoneal leaks in patients undergoing peritoneal dialysis.<sup>2</sup>

<sup>☆</sup> Please cite this article as: García Gómez FJ, Martínez Esteve A, Tirado Hospital JL. Diagnóstico de comunicación peritoneo-pleural mediante peritoneograma isotópico con  $^{99m}\text{Tc}$ -sulfuro coloidal en una niña de 3 años con síndrome nefrótico congénito tipo finlandés. Arch Bronconeumol. 2015;51:199–200.

\* Corresponding author.

E-mail address: javier191185@gmail.com (F.J. García Gómez).



**Fig. 1.** Peritoneal scintigraphy negative for pleuroperitoneal communication. Anterior projections obtained at 15, 60, and 120 min (upper image). Peritoneal scintigraphy positive for pleuroperitoneal leak. Anterior projections obtained after 50, 125, and 500 ml of peritoneal dialysis solution (lower image).

### Funding

The authors state that they received no funding.

### Conflict of Interest

The authors state that they have no conflict of interests.

### References

1. Díaz Mancebo R, del Peso Gilsanz G, Rodríguez M, Fernández B, Ossorio González B, Bajo Rubio MA, et al. Comunicación pleuro-peritoneal en pacientes en diálisis peritoneal. Experiencia en un centro y revisión de la literatura. *Nefrología*. 2011;31:213–7.
2. Hernández Martínez AC, Marín Ferrer MD, Coronado Poggio M, Escabias del Pozo C, Coya Viña J, Martín Curto L. Gammagrafía peritoneal con  $^{99m}\text{Tc}$ -MAA en las comunicaciones pleuroperitoneales en pacientes en diálisis peritoneal. *Rev Esp Med Nucl*. 2010;29:84–6.