



Case Report

Recurrent Pneumonia Due to Bronchial Carcinoid Tumour in a Young Patient: The Role of ^{111}In -Pentetreotide in Imaging Studies[☆]



Paloma García-Talavera,^{a,*} María Rosa López-Pedreira,^b Marian Udaondo,^b José María Matilla,^c Juan Gabriel Villanueva,^a Henar Borrego^d

^a Servicio de Medicina Nuclear, Hospital Clínico Universitario de Valladolid, Valladolid, Spain

^b Servicio de Radiodiagnóstico, Hospital Clínico Universitario de Valladolid, Valladolid, Spain

^c Servicio de Cirugía Torácica, Hospital Clínico Universitario de Valladolid, Valladolid, Spain

^d Servicio de Anatomía Patológica, Hospital Clínico Universitario de Valladolid, Valladolid, Spain

ARTICLE INFO

Article history:

Received 11 November 2013

Accepted 3 January 2014

Available online 24 January 2015

Keywords:

Bronchial carcinoid tumor

Recurrent pneumonia

^{111}In -pentetreotide scintigraphy

ABSTRACT

Bronchial carcinoid tumors are an uncommon cause of recurrent pneumonia in young patients. Diagnosis is determined from imaging studies, bronchoscopy, and histological confirmation, and treatment is generally surgical. Two cases are reviewed in order to examine the value of ^{111}In -DTPA-Phe-octreotide (^{111}In -pentetreotide) scintigraphy in the pre-surgical evaluation of these patients. After a suspicious area was observed in other tests (standard X-ray, CT), a neuroendocrine tumor was diagnosed using this technique and the presence of regional or distant disease was ruled out. Comparison with the less valuable ^{18}F -FDG PET (carried out in one of the cases) highlights the usefulness of SPECT-CT, which performs notably better in terms of the localization and characterization of findings.

© 2013 SEPAR. Published by Elsevier España, S.L.U. All rights reserved.

Tumor carcinoide bronquial como causa de neumonías de repetición en paciente joven: papel del ^{111}In -pentetreotida en el contexto de las pruebas de imagen

RESUMEN

Los tumores carcinoideos bronquiales son una causa infrecuente de neumonías de repetición en pacientes jóvenes. El diagnóstico se obtiene mediante pruebas de imagen, broncoscopia y confirmación histológica, y el tratamiento es fundamentalmente quirúrgico. Mediante la presentación de 2 casos, revisamos la utilidad de la gammagrafía con ^{111}In -DTPA-Phe-octreotide (^{111}In -pentetreotida) en la valoración de estos pacientes antes de la cirugía, apoyando el diagnóstico de tumor neuroendocrino ante una imagen sospechosa en otras pruebas (radiografía simple, TC) y descartando enfermedad regional o a distancia. Frente al reducido valor de la PET con ^{18}F -FDG (realizada en uno de los casos), se destaca el papel de la SPECT-TC, que mejora notablemente la localización y la caracterización de los hallazgos.

© 2013 SEPAR. Publicado por Elsevier España, S.L.U. Todos los derechos reservados.

Palabras clave:

Tumor carcinoide bronquial

Neumonías de repetición

Gammagrafía con ^{111}In -pentetreotida

Introduction

Around 25% of carcinoid tumors occur in the lung, accounting for approximately 2% of all lung cancers.¹ Eighty percent of

bronchial carcinoid tumors are typical, and this is the most common primary lung cancer among children and adolescents. It is asymptomatic in up to 58% of cases, and patients may present with respiratory symptoms¹ or, more rarely, Cushing's syndrome due to ectopic ACTH secretion (8%) or carcinoid syndrome (5%).² Diagnosis is generally made from imaging procedures, bronchoscopy and histological confirmation,³ and definitive treatment is surgery (segmentectomy, lobectomy or pneumonectomy).

We present 2 young patients with a history of recurrent pneumonia, in whom imaging results suggested bronchial neuroendocrine tumor (NET). These cases underline the utility of ^{111}In -pentetreotide scintigraphy in the presurgical assessment of this disease.

[☆] Please cite this article as: García-Talavera P, López-Pedreira MR, Udaondo M, Matilla JM, Villanueva JG, Borrego H. Tumor carcinoide bronquial como causa de neumonías de repetición en paciente joven: papel del ^{111}In -pentetreotida en el contexto de las pruebas de imagen. Arch Bronconeumol. 2015;51:e16–e18.

* Corresponding author.

E-mail address: palomagtalavera@gmail.com (P. García-Talavera).

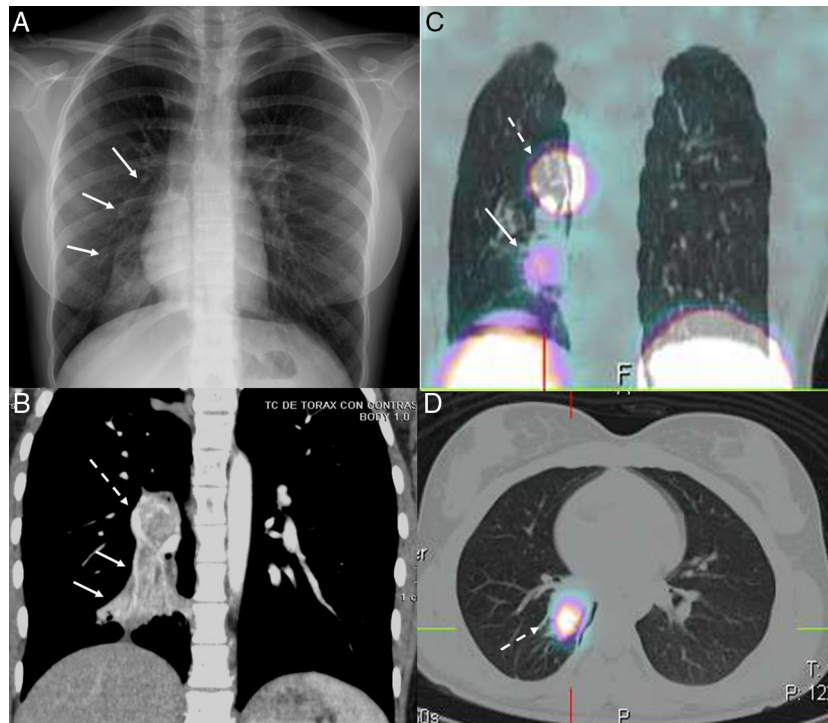


Fig. 1. (A) Standard posteroanterior chest X-ray: right basal opacity with signs of atelectasis in right lower lobe (RLL) (arrows). (B) Coronal contrast-enhanced computed tomography (CT): right hilar mass (dotted arrow), enhanced after contrast administration, causing RLL atelectasis (solid arrow). (C) Chest SPECT-CT. Coronal slice: radiotracer hotspot in right hilar region, suggestive of neuroendocrine tumor (dotted arrow). Another less intense radiotracer uptake focus, below the hotspot, located in an area of pneumonitis with atelectasis (solid arrows). (D) Chest SPECT-CT. Axial slice: radiotracer hotspot located in right hilar mass (dotted arrow).

Clinical Reports

Case 1 (Fig. 1)

A 16-year-old girl with a 3-year history of recurrent pneumonia, who was hospitalized due to a new episode of persistent cough. Diminished breath sounds in the right lung base and leukocytosis with left shift were identified and opacity with signs of atelectasis of the right lower lobe (RLL) were seen on standard chest X-ray (Fig. 1).

Contrast-enhanced computed tomography (CT) revealed a right parahilar mass (3.5 cm) with lumpy calcifications, enhanced with contrast, compressing the intermediate bronchus and causing obstructive atelectasis of the RLL with mucoid impactions. A lymphadenopathy (1 cm) was observed in right parahilar region.

Scintigraphy was requested to confirm suspected bronchial carcinoid tumor and to complete the evaluation. A whole body scan (WBS) and chest SPECT-CT were performed, revealing a focus of increased uptake or “hotspot” in the right parahilar mass, indicative of NET. Diffuse, mildly intense uptake was also observed on the SPECT-CT below the hotspot, due to pneumonitis.

A mass on the opening of the RLL bronchus was confirmed by bronchoscopy, and the bronchial aspirate was suggestive of carcinoid tumor.

Protocolized bilobectomy (middle and inferior lobes) was performed, revealing a typical carcinoid tumor in the RLL, with intrabronchial invasion (pT2apN0Mx).

The patient remains disease-free 30 months after the procedure.

Case 2 (Fig. 2)

A 21-year-old man with a history of asthma, who suffered 2 episodes of pneumonia in the previous year. During the second episode, he presented diminished breath sounds and isolated crackles in the left lung base and leukocytosis with left shift. Standard chest X-ray showed condensation in the left lower lobe (LLL) (Fig. 2).

Outpatient treatment did not produce any clinical improvement, so a bronchoscopy was performed, showing obstruction of the LLL bronchus due to an exophytic lesion. No malignancy was observed in the bronchial aspirate.

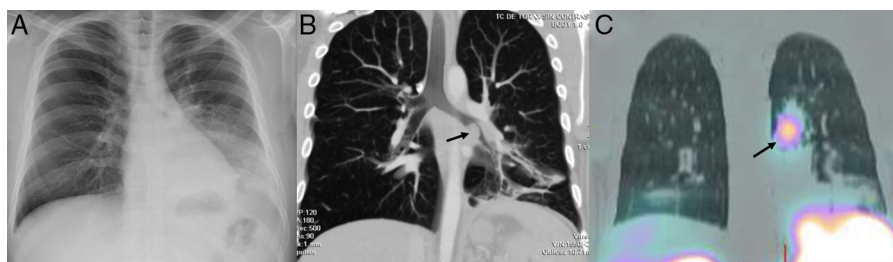


Fig. 2. (A) Standard posteroanterior chest X-ray: condensation in left lower lobe (LLL). (B) Coronal computed tomography (CT) with intravenous contrast, volumetric reconstruction: endobronchial mass (arrow) in LLL bronchus with distal pneumonitis and loss of volume. (C) Chest SPECT-CT. Coronal slice: radiotracer hotspot in left parahilar region (arrow).

Contrast-enhanced CT was performed, revealing a lobulated mass (3 cm × 3.5 cm) in the LLL, with an endobronchial component, and consolidation due to obstructive pneumonitis, along with loss of lung volume shown by hemidiaphragmatic elevation. Small hilar and subcarinal lymphadenopathies (up to 11 mm) were found in the mediastinum.

A ¹⁸F-deoxyglucose (¹⁸F-FDG) PET scan was performed, showing right paratracheal (maximum standard uptake value [SUV-max]: 2), left precarinal (SUV-max: 2.6) and left hilar (SUV-max: 2.8) uptake. Diffuse uptake due to pneumonitis was also observed in the LLL (SUV-max: 3.5). No pathological uptake was observed in the left hilar node.

In view of suspected endobronchial carcinoid tumor, ¹¹¹In-pentetreotide scintigraphy was performed. WBS showed radiotracer deposits in the left hemothorax, localized by SPECT-CT to the LLL parahilar mass, indicative of NET.

Bronchial carcinoid tumor was confirmed by rigid fiberoptic bronchoscopy, and protocolized left pneumonectomy was performed, since the peribronchial tumor was surrounding lobar and segmental arteries. Mediastinal lymphadenectomy was also performed on grossly abnormal lymph nodes (berry picking). Pathology results reported typical carcinoid cancer (pT2apN0pMx).

The patient remains clear of any signs of relapse, 34 months post-surgery.

Discussion

Although uncommon, the possibility of bronchial carcinoid tumor must be considered in a young patient with recurrent pneumonia, since clinical signs play an important role in the diagnosis of these tumors.

The ¹¹¹In-pentetreotide technique is highly sensitive and specific for identifying NETs, although it may be affected by several factors, such as tumor site, degree of cell differentiation and size.⁴

Activated lymphocytes due to infections or inflammatory conditions may produce false positives.⁴ In our patients, scintigraphy helped to characterize the tumors by highlighting the presence of somatostatin receptors. Tumor site was localized by SPECT-CT, and in one case helped to differentiate between tumor mass and associated pneumonitis. Scintigraphic procedures also assisted in ruling out lymphadenopathies or distant disease, as confirmed during surgery and follow-up.

The limited efficacy of ¹⁸F-FDG PET in the evaluation of well-differentiated NETs was confirmed by the negative result of this procedure in one of our cases. Phan et al.⁵ suggest that is due to the generally low proliferative activity of these tumors. These authors also report that ¹⁸F-FDG PET can be used in more undifferentiated, nonsecretory tumors when ¹¹¹In-pentetreotide uptake is negative, or even for characterizing tumor aggressiveness in the case of higher ¹⁸F-FDG uptake.

References

1. López Vivanco G, Barón Duarte FG, Cabezas Agrícola JM, Fernández-Bobadilla JC, Crespo Herrero G, López López C, et al. TNE torácicos: pulmón y timo. In: Guía práctica de diagnóstico, tratamiento y seguimiento de tumores neuroendocrinos. Barcelona: EdikaMed; 2010. p. 47–65.
2. García-Yuste M, Matilla JM, Cueto A, Paniagua JM, Ramos G, Cañizares MA, et al. Typical and atypical carcinoid tumours: analysis of the experience of the Spanish Multi-centric Study of Neuroendocrine Tumours of the Lung. *Eur J Cardiothorac Surg.* 2007;31:192–7.
3. Chong S, Lee KS, Chung MJ, Han J, Kwon OJ, Kim TS. Neuroendocrine tumors of the lung: clinical, pathologic, and imaging findings. *Radiographics.* 2006;26:41–57.
4. Kwekkeboom DJ, Krenning EP, Scheidhauer K, Lewington V, Lebtahi R, Grossman A. ENETS Consensus Guidelines for the Standards of Care in Neuroendocrine Tumors: somatostatin receptor imaging with ¹¹¹In-pentetreotide. *Neuroendocrinology.* 2009;90:184–9.
5. Phan AT, Oberg K, Choi J, Harrison LH Jr, Hassan MM, Strosberg JR, et al. NANETS consensus guideline for the diagnosis and management of neuroendocrine tumors: well-differentiated neuroendocrine tumors of the thorax (includes lung and thymus). *Pancreas.* 2010;39:784–98.