

References

- Murray PR, Baron EJ, Michael A, Pfaller MA, Tenover FC, Tenover FC. Manual of clinical microbiology. 7th ed. New York: Saunders; 2007.
- Furumoto A, Masaki H, Onidzuka T, Degawa S, Yamaryo T, Shimogama S, et al. A case of community-acquired pneumonia caused by *Corynebacterium propinquum*. Kansenshogaku Zasshi. 2003;77:456–60.
- Motomura K, Masaki H, Terada M, Onizuka T, Shimogama S, Furumoto A, et al. Three adult cases with *Corynebacterium propinquum* respiratory infections in a community hospital. Kansenshogaku Zasshi. 2004;78:277–82.
- Saidani M, Kammoun S, Boutiba-Ben Boubaker I, Ben Redjem S. *Corynebacterium propinquum* isolated from a pus collection in a patient with an osteosynthesis of the elbow. Tunis Med. 2010;88:360–2.
- Díez-Aguilar M, Ruiz-Garbajosa P, Fernández-Olmos A, Guisado P, del Campo R, Quereda C, et al. Non-diphtheriae *Corynebacterium* species: an emerging respiratory pathogen. Eur J Clin Microbiol Infect Dis. 2013;32:769–72.
- Babay HA. Pleural effusion due to *Corynebacterium propinquum* in a patient with squamous cell carcinoma. Ann Saudi Med. 2001;21:337–9.

Iván Prats-Sánchez,^a María José Soler-Sempere,^{b,*} Victoria Sánchez-Hellín^a

^a Sección de Microbiología, Hospital General Universitario de Elche, Elche, Alicante, Spain

^b Sección de Neumología, Hospital General Universitario de Elche, Elche, Alicante, Spain

* Corresponding author.

E-mail addresses: majosoler1@hotmail.com, majosoler20@gmail.com (M.J. Soler-Sempere).

Mycobacterium interjectum Lung Infection: A Case Report[☆]

Enfermedad pulmonar por *Mycobacterium interjectum*: a propósito de un caso

Mycobacterium interjectum (*M. interjectum*) is a rare, non-tuberculous mycobacterium, known to cause lymphadenitis cervicalis in young patients.¹ We report a case of pulmonary disease.

A 52-year-old man, active smoker, presented with a 15-day history of fever, general malaise and bloody expectoration. Isolated crepitations were heard on lung auscultation. Chest X-ray showed right upper lobe condensation and enlarged right hilum. Treatment with levofloxacin was prescribed, but improvement was limited, so a chest computed tomography (CT) was performed, revealing condensation with air bronchogram in the posterior segment of the right upper lobe (Fig. 1), and enlarged right hilar, retrocava-pretracheal and prevascular lymph nodes. Bronchoscopy was performed: gross results were normal, and cytology and bacilloscopic results from bronchial aspirate were also normal. CT-guided core biopsy of the lung was conducted, and histologic analysis of the specimen showed granulomas with multinucleated giant cells and epithelioid cell histiocytes, some of which had central necrosis. Treatment began with isoniazid, rifampicin, pyrazinamide and ethambutol. Mycobacteria were subsequently isolated from the culture of the bronchial aspirate; these were identified as *M. interjectum* using DNA technology based on inverse hybridization of PCR products targeting the 23S rRNA gene (GenoType[®] *Mycobacterium* CM). The patient's progress was satisfactory and, 2 months later, cultures were negative for mycobacteria. Pyrazinamide and ethambutol were withdrawn, while isoniazid and rifampicin administration continued for 1 year. At that time, the patient remained asymptomatic, with fibrous scarring and infiltration in the right upper lobe on chest X-ray. Currently, 20 months later, he is stable with no signs of disease reactivation.

Only three cases of lung involvement with *M. interjectum* have been reported in the literature.^{2–4} All three were cases of cavitary disease in which *M. interjectum* was later isolated. The strains were resistant to isoniazid, rifampicin, pyrazinamide³ and ethambutol,^{3,4} although one patient³ initially responded well

to standard antituberculosis treatment. Nevertheless, 18 months later, symptoms and radiological progression recurred, and a non-tuberculous mycobacteria with the same resistance profile as before was isolated.

In contrast to the above-mentioned cases, our patient did not have cavitary disease, and response to first-line antituberculosis drugs was good, despite rifampicin and ethambutol resistance found on antimicrobial sensitivity testing. In view of the good clinical progress after identification of the mycobacteria, an antibiogram was felt to be unnecessary, and this may be considered as a limitation of our report. However, discrepancies between *in vitro* and *in vivo* resistance data raise questions regarding the real significance of *in vitro* resistance in certain situations. This issue and the long follow-up period add to the value of the experience reported.

To conclude, *M. interjectum* is a very unusual cause of lung disease. Once diagnosed, treatment with a standard antituberculosis regimen may be attempted.

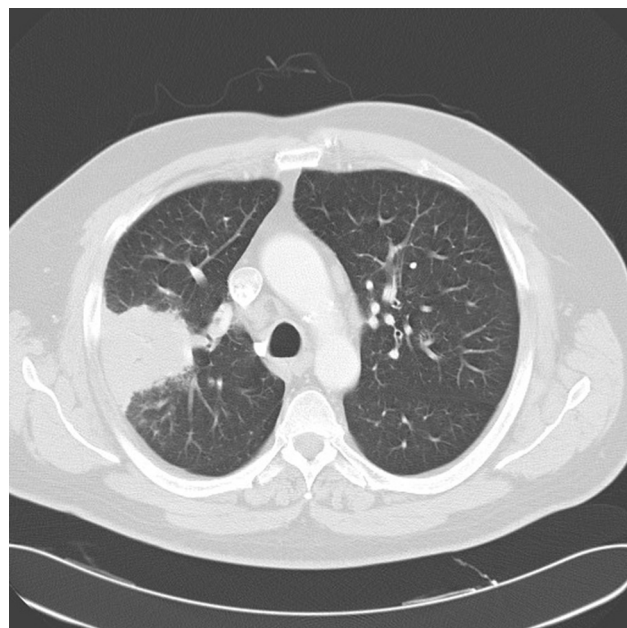


Fig. 1. Chest CT image of right upper lobe.

[☆] Please cite this article as: Villanueva MÁ, Gullón JA, Álvarez-Navascués F. Enfermedad pulmonar por *Mycobacterium interjectum*: a propósito de un caso. Arch Bronconeumol. 2015;51:155–156.

Conflict of Interests

The authors declare that they have no conflict of interests.

References

1. Rose M, Kitz R, Mischke A, Enzensberger R, Schneider V, Zielen S. Lymphadenitis cervicalis due to *Mycobacterium interjectum* in immunocompetent children. *Acta Paediatr.* 2004;93:424–6.
2. Emler S, Rochat T, Rohner P, Perrot C, Auckenthaler R, Perrin L, et al. Chronic destructive lung disease associated with a novel *mycobacterium*. *Am J Respir Crit Care Med.* 1994;150:261–5.
3. Martínez-Lacasa J, Cuchi E, Font R. *Mycobacterium interjectum* as a cause of lung disease mimicking tuberculosis. *Int J Tuberc Lung Dis.* 2009;13:1048.

4. Mirant-Borde M, Soto J, Johnson M. *Mycobacterium interjectum*: a rare cause of destructive lung disease. *Chest.* 2012;142:159A.

Manuel Ángel Villanueva, José Antonio Gullón,* Fernando Álvarez-Navascués

Unidad de Gestión Clínica de Neumología, Hospital San Agustín, Avilés, Asturias, Spain

* Corresponding author.

E-mail address: josegubl@gmail.com (J.A. Gullón).

Cardiogenic Shock and Pulmonary Embolism*

Shock cardiogénico y embolia de pulmón

To the Editor,

We read with interest the national consensus document for the diagnosis, risk stratification and treatment of patients with pulmonary thromboembolism (PTE).¹ The prognostic stratification of PTE patients is based on their hemodynamic status, and patients with hypotension (sustained systolic blood pressure less than 90 mmHg) or cardiogenic shock are considered high risk. The recommended treatment for cardiogenic shock is the administration of fibrinolytics.

The term “shock” describes a clinical situation with circulatory failure causing hypoperfusion and hypoxia.² We are indebted to Dr Max Harry Weil³ for his major contribution to the understanding of the physiopathology of shock and his proposed classification of stages of shock, published in the early 1970s.⁴ There are 4 potential, non-exclusive, forms of shock: hypovolemic, cardiogenic, obstructive and distributive (mainly associated with sepsis and anaphylaxis). Cardiogenic shock occurs as a consequence of heart failure associated with diminished cardiac output. It can be caused by acute myocardial infarction, end-stage myocardial or valve disease, myocarditis or arrhythmias.⁵ Obstructive shock is less common and comprises different entities: pulmonary embolism, cardiac tamponade, aortic dissection and tension pneumothorax. The basic mechanism is increased afterload.³ Our understanding is that the correct denomination would be obstructive shock, or simply shock.

* Please cite this article as: Romero Gómez C, Aguilar García JA, Martín Escalante MD. Shock cardiogénico y embolia de pulmón. *Arch Bronconeumol.* 2015;51:156.

Nevertheless, the clinical presentation of pulmonary embolism can be similar to that of cardiogenic shock, and some authors consider the first as a form of the second. Indeed, there is no agreement on the denomination in the 2 referenced guidelines on the treatment of thromboembolic disease¹ from the American College of Chest Physicians and the National Institute for Health and Clinical Excellence. The former only refers to the term “shock”, while the latter calls it cardiogenic shock. Irrespective of how this entity is called, there is no doubt that the new consensus document is of invaluable help in patient management.

References

1. Uresandi F, Monreal M, García-Bragado F, Domenech P, Lecumberri R, Escribano P, et al. Consenso nacional sobre el diagnóstico, estratificación de riesgo y tratamiento de los pacientes con tromboembolia pulmonar. *Arch Bronconeumol.* 2013;49:534–47.
2. Vicent JL, de Backer D. Circulatory shock. *N Engl J Med.* 2013;369:1726–34.
3. Vincent JL, Ince C, Bakker J. Circulatory shock an update: a tribute to Professor Max Harry Weil. *Crit Care.* 2012;16:239.
4. Weil MH, Shubin H. Proposed reclassification of shock states with special reference to distributive defects. *Adv Exp Med Biol.* 1971;23:13–23.
5. Reynolds HR, Hochman JS. Cardiogenic shock: current concepts and improving outcomes. *Circulation.* 2008;117:686–97.

Carlos Romero Gómez,* Josefa Andrea Aguilar García, María Dolores Martín Escalante

Servicio de Medicina Interna, Agencia Pública Hospital Costa del Sol, Marbella, Málaga, Spain

* Corresponding author.

E-mail address: carlosrg1968@gmail.com (C. Romero Gómez).

Atypical Deep Venous Thrombosis as the First Manifestation of Pulmonary Neoplasm*

Trombosis venosa inusual como primera manifestación de neoplasia pulmonar

To the Editor,

Hypercoagulable states in cancer are well known to be closely associated with thromboembolic phenomena. After a thromboem-

bolic event, the incidence of malignant tumors, mainly of the blood, pancreas, ovary, liver, kidney and lung, ranges between 2% and 25%. The most common sites are venous thrombosis of the lower limbs and pulmonary thromboembolism, and reports of cases in other venous territories are unusual.

We report a 68-year-old man, smoker of more than 40 pack-years, who was seen in the ophthalmology clinic for a 20-day history of loss of sight in the right eye. Examination of the eye revealed bilateral venous thrombosis of the retina. Additional examinations were performed to rule out secondary systemic disease. Clinical laboratory, coagulation, serological and autoimmune examinations and computed tomography (CT) of the brain were performed; all results were negative. A chest X-ray was performed, revealing a nodule in the left upper lobe (LUL). Chest CT confirmed a

* Please cite this article as: Jodra Sánchez S, Andrés Blanco AM, Abad Manteca L. Trombosis venosa inusual como primera manifestación de neoplasia pulmonar. *Arch Bronconeumol.* 2015;51:156–157.