

Clinical Image

Giant Dermatofibrosarcoma Protuberans of the Anterior Chest Wall[☆]

Dermatofibrosarcoma gigante de la pared torácica anterior

Mohammed Massine el Hammoumi,^{a,*} Abdjalil Abouchadi,^b El Hassane Kabiri^a^a Department of Thoracic Surgery, Mohamed V Military University Hospital, Faculté de Médecine et de Pharmacie, Université Mohamed V Souissi, Rabat, Morocco^b Department of Stomatology, Mohamed V Military University Hospital, Rabat, Morocco

Dermatofibrosarcoma is a slow-growing, locally aggressive fibrous tumor with high rates of local recurrence after surgical resection. The tumor occurs principally in the trunk and the proximal extremities. We report a case of pedunculated

dermatofibrosarcoma protuberans located in the skin above the sternum of a 31-year-old woman (Fig. 1) that was resected after pathological diagnosis. Esthetic issues were addressed with a secondary skin graft. Twelve months later, the patient remains free of

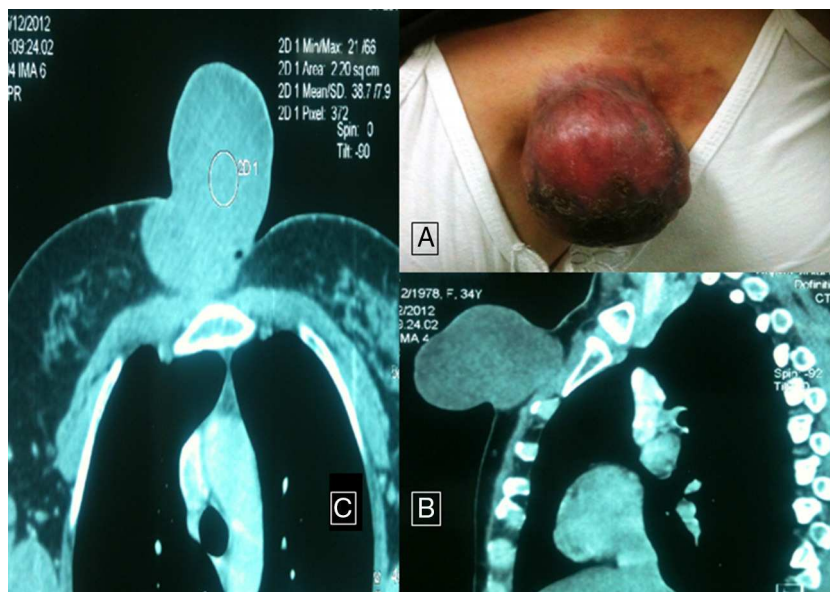


Fig. 1. Pedunculated tumor in the anterior chest wall (A). Chest computed tomography showing a pedunculated mass in the chest and right breast, with additional invasion of the chest wall (B and C).

[☆] Please cite this article as: el Hammoumi MM, Abouchadi A, Kabiri EH. Dermatofibrosarcoma gigante de la pared torácica anterior. Arch Bronconeumol. 2015;51:299–300.

* Corresponding author.

E-mail address: hamoumimassine@hotmail.fr (M.M. el Hammoumi).

signs of disease. This type of giant tumor is very rare in women.¹
Careful and complete resection is recommended.²

Conflict of Interests

The authors declare that they have no conflict of interest.

References

1. Ledniczky G, Bognár G, Diczházi C, Bereczky B, Barabás L, Ondrejka P. An uncommon malignancy of the breast: Dermatofibrosarcoma protuberans with fibrosarcomatous transformation. *Magy Seb.* 2009;62:27–9.
2. Kozarev J, Cuk D. Dermatofibrosarcoma protuberans: case report. *Med Pregl.* 1999;52:71–3.