

Clinical Image

Solitary Endobronchial Tumor Due to Sarcoidosis: An Autofluorescence Bronchoscopic Image[☆]

Tumor endobronquial único por sarcoidosis: imagen bronoscópica por autofluorescencia

Shuichi Kawano, Soichiro Kanoh,* Akihiko Kawana

Departamento de Enfermedades Infecciosas y Medicina Respiratoria, Colegio Médico de Defensa Nacional, Japan

A 72-year-old man was hospitalized for evaluation of bilateral hilar lymphadenopathy. Flexible bronchoscopy revealed a bronchial tumor with a smooth, glossy surface at the orifice of right B2 bronchus (Fig. 1A). On autofluorescence bronchoscopy, the tumor was magenta and showed less fluorescence than normal mucosa (Fig. 1B), findings characteristic of bronchogenic carcinoma. Histopathological examination of a biopsy specimen revealed a submucosal lesion composed of non-caseating granulomas covered by an intact bronchial epithelium. Laboratory

data showed an increased level of serum angiotensin converting enzyme, and bronchoalveolar lavage showed an elevated lymphocyte population and a high CD4/D8 ratio, which led to the diagnosis of sarcoidosis.

Sarcoidosis is a relatively common systemic granulomatous disease of unknown etiology.¹ An endobronchial vascular network and plaques are often seen. However, sarcoidosis manifesting as an endobronchial tumor is extremely rare.² Autofluorescence bronchoscopy is useful for detecting carcinoma in situ or other

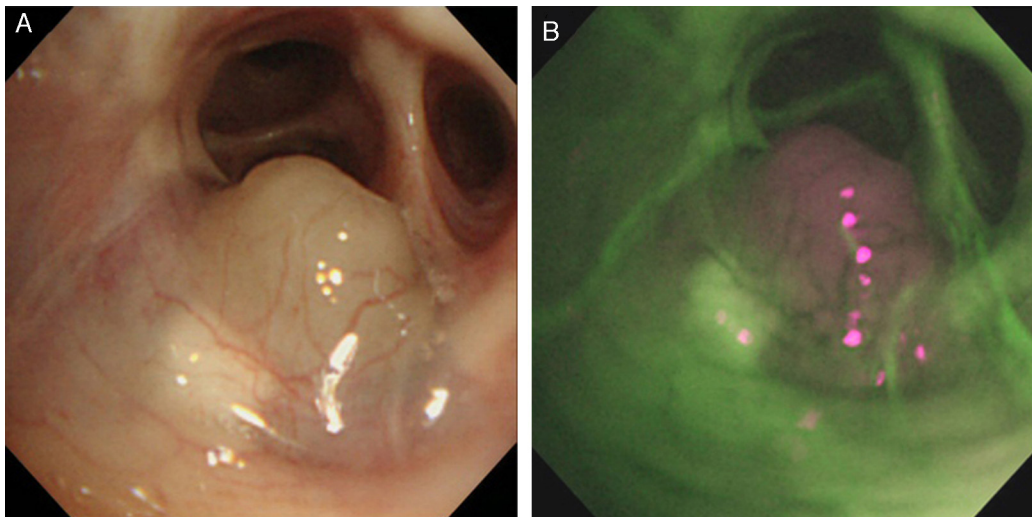


Fig. 1. Bronchoscopic views. (A) A bronchial mass at the orifice of right B2 and (B) an autofluorescence bronchoscopic image showing relatively less fluorescence than normal tissue.

[☆] Please cite this article as: Kawano S, Kanoh S, Kawana A. Tumor endobronquial único por sarcoidosis: imagen bronoscópica por autofluorescencia. Arch Bronconeumol. 2016;52:48–49.

* Corresponding author.

E-mail address: kanoh@ndmc.ac.jp (S. Kanoh).

epithelial dysplasia. Our case highlights the utility of autofluorescence bronchoscopy for detecting not only epithelial but also submucosal lesions.

Conflict of Interests

The authors declare that they have no conflict of interests.

References

1. [Statement on sarcoidosis](#). Joint Statement of the American Thoracic Society (ATS), the European Respiratory Society (ERS) and the World Association of Sarcoidosis and Other Granulomatous Disorders (WASOG) adopted by the ATS Board of Directors and by the ERS Executive Committee, febrero de 1999. *Am J Respir Crit Care Med.* 1999;160:736–55.
2. [Corsello BF, Lohaus GH, Funahashi A. Endobronchial mass lesion due to sarcoidosis: complete resolution with corticosteroids.](#) *Thorax.* 1983;38:157–8.