



Case Report

Resolution of Obstructive Atelectasis With Non-Invasive Mechanical Ventilation[☆]

Rosa Mirambeaux Villalona,* Sagrario Mayoralas Alises, Salvador Díaz Lobato

Servicio de Neumología, Hospital Ramón y Cajal, Madrid, Spain

ARTICLE INFO

Article history:

Received 8 September 2013

Accepted 24 November 2013

Available online 11 August 2014

Keywords:

Non-invasive mechanical ventilation

Atelectasis

Respiratory acidosis

Bronchoscopy

ABSTRACT

Bronchoscopy is a commonly used technique in patients with atelectasis due to mucus plugs. We present here the case of an 82-year-old patient with a history of Meige's syndrome that developed acute respiratory failure due to atelectasis of the right upper lobe associated with hospital-acquired pneumonia. The patient had a severely reduced level of consciousness, significant work-of-breathing and severe hypercapnic acidosis, all of which contraindicated bronchoscopy. Bi-level non-invasive mechanical ventilation (NIMV) was initiated by way of a face mask. Progress was favorable, with clear clinical and gasometric improvement. The chest X-ray performed 12 h later showed complete resolution of the atelectasis. These data suggest that NIMV may be useful in the treatment of atelectasis in some critical patients.

© 2013 SEPAR. Published by Elsevier España, S.L.U. All rights reserved.

Resolución de atelectasia obstructiva con ventilación mecánica no invasiva

RESUMEN

La broncoscopia es la técnica habitualmente empleada en pacientes con atelectasias secundarias a tapones mucosos. Presentamos el caso de una paciente de 82 años de edad con antecedentes de síndrome de Meige, que desarrolló un cuadro de insuficiencia respiratoria aguda al sufrir una atelectasia del lóbulo superior derecho en el contexto de una neumonía intrahospitalaria. La paciente presentaba importante disminución del nivel de conciencia, gran trabajo respiratorio y acidosis hipercápnica grave, condiciones que contraindicaban la realización de una broncoscopia. Se instauró ventilación mecánica no invasiva (VMNI) con doble nivel de presión a través de una mascarilla facial. La evolución fue favorable, con franca mejoría clínica y gasométrica. En la radiografía de tórax realizada a las 12 h se apreció resolución completa de la atelectasia. Estos datos sugieren que la VMNI podría ser útil en el tratamiento de las atelectasias de algunos pacientes críticos.

© 2013 SEPAR. Publicado por Elsevier España, S.L.U. Todos los derechos reservados.

Palabras clave:

Ventilación mecánica no invasiva

Atelectasia

Acidosis respiratoria

Broncoscopia

Introduction

Atelectasis associated with mucus plugs is common in hospitalized patients. Bronchoscopy is the technique of choice for resolving this disorder, particularly when the patient's respiratory system is compromised.¹ We present the case of a patient with obstructive atelectasis of the right upper lobe and respiratory acidosis, resolved with the application of non-invasive ventilation (NIV).

Clinical Case Report

An 82-year-old woman with a history of diabetes mellitus type 2 and oromandibular and cervical dystonia with blepharospasm (Meige's syndrome). In 2010, she had a pure sensory right hemispheric lacunar transient ischemic attack. She presented in the hospital complaining of abdominal pain of 2 days' duration. Evaluation in the emergency department led to a diagnosis of inflammation in the terminal ileum and admission to the general surgery unit for conservative management. Four days after admission, the patient's general status deteriorated, with dyspnea on minimal effort, worsening to dyspnea at rest accompanied by significant work-of-breathing and progressively diminishing level of consciousness. Temperature was 38 °C. Of note on physical examination was tachypnea with 28 breaths/minute and intense subcostal retraction, tachycardia 110 beats/min, arterial

[☆] Please cite this article as: Mirambeaux Villalona R, Mayoralas Alises S, Díaz Lobato S. Resolución de atelectasia obstructiva con ventilación mecánica no invasiva. Arch Bronconeumol. 2014;50:452–453.

* Corresponding author.

E-mail addresses: dra.rmmirambeauxv@gmail.com, rosita159@hotmail.com (R. Mirambeaux Villalona).

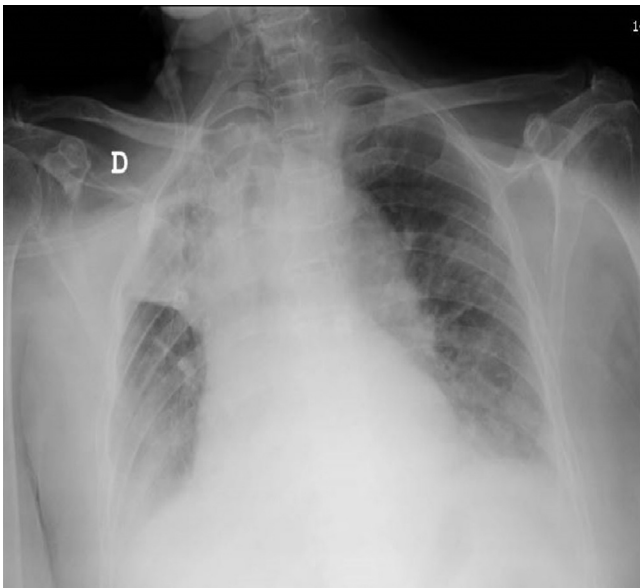


Fig. 1. Right upper lobe atelectasis with mediastinal shift toward the affected side.

hemoglobin oxygen saturation (SpO_2) 83% despite administration of O_2 via a non-rebreathing mask. Pulmonary auscultation revealed generalized loss of breath sounds and abundant rhonchi. There were no other findings of interest in other organs. Laboratory testing showed leukocytosis (12.5×10^9) with left shift (75% neutrophils). Chest X-ray revealed atelectasis of the right upper lobe (RUL) with ipsilateral mediastinal shift (Fig. 1). X-ray on admission was normal. The respiratory unit was requested to perform bronchoscopy for resolution of the RUL atelectasis. The patient's situation was critical and the possibility of using Cough Assist[®], a mechanical cough assistant, as alternative treatment was discussed. Blood gases determined while the patient was receiving reservoir O_2 delivery showed pH: 7.06; $PaCO_2$: 78 mmHg; PaO_2 : 94 mmHg; HCO_3^- : 22.1 mmol/l; SaO_2 : 86%. Ultimately, it was decided to start NIV. Bi-level pressure ventilation via a face mask with a Monnal T50[®] ventilator was initiated with the following settings: IPAP: 25; EPAP: 10; FR: 12; Ti: 1.3, with addition of O_2 at 8 l/min. Intravenous antibiotics were administered. After 1 h of treatment, blood gases were pH: 7.22; $PaCO_2$: 53 mmHg; PaO_2 : 58 mmHg; HCO_3^- : 21.7 mmol/l; SaO_2 : 83.3%. Respiratory rate and level of consciousness improved. After 24 h, the patient's level of consciousness was normal, work-of-breathing had resolved and blood gases were pH: 7.36; $PaCO_2$: 45 mmHg; PaO_2 : 73 mmHg; HCO_3^- : 24.3 mmol/l; SaO_2 : 94%. X-ray obtained at 12 hours showed complete resolution of atelectasis in the RUL and condensation in the right lower lobe (RLL) (Fig. 2). After 24 h of stable clinical signs and symptoms and blood gases, NIV was withdrawn. Antibiotic treatment continued for 14 days and progress was favorable.

Discussion

Atelectasis may be prevented with respiratory physiotherapy, mechanical insufflation–exsufflation devices, or the application of positive airway pressure. Respiratory physiotherapy in hospitalized patients has been largely ignored. Limited use of

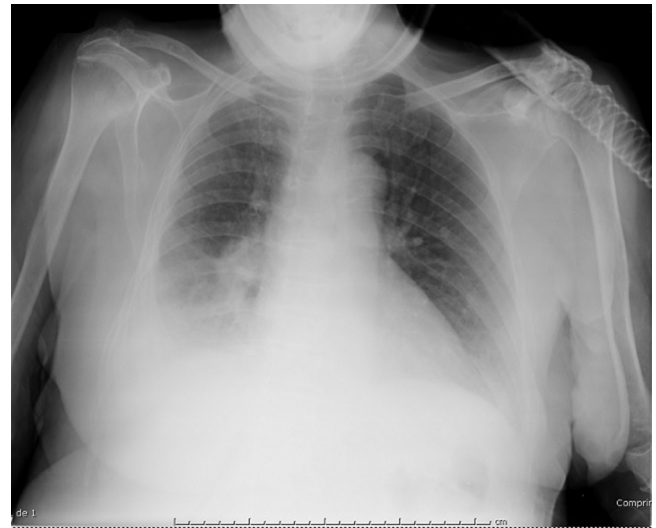


Fig. 2. Absence of right upper lobe atelectasis after non-invasive ventilation. Infiltration can be seen in the right lower lobe.

this technique leads to increased respiratory complications, including atelectasis. This in turn leads to the abuse of invasive treatment procedures, such as bronchoscopy.² Mechanical insufflation–exsufflation devices such as Cough Assist[®] have been shown to be useful in the prevention and cure of atelectasis in neuromuscular patients with secretory disorders, although they are mainly used in the home setting in association with physiotherapy.³ Positive airway pressure, alone or in conjunction with other physiotherapy techniques, has also been shown to be effective in the prevention of post-operative atelectasis.^{4,5}

Once atelectasis occurs, however, the intervention of choice is bronchoscopy for aspiration of mucous from the airway. In our patient, NIV was indicated due to hypercapnic respiratory failure; breathing, as expected, improved, accompanied by rapid, complete resolution of atelectasis. No references to NIV in the treatment of critical patients with contraindications for bronchoscopy were found in the literature. Our experience suggests that NIV may be useful in the treatment of atelectasis in some critical patients. Bronchoscopy is a more aggressive intervention that is also more costly in terms of resources and personnel, and the possibility of replacing it with NIV should be investigated in further studies.

References

- Aspa-Marco J, Prieto Vicente J. La fibrobroncoscopia en la urgencia respiratoria y en pacientes críticos. In: Díaz-Agero Álvarez P, Flandes Aldeytruriaga J, editors. Broncoscopia diagnóstica y terapéutica, X. Madrid: Monografías de la Sociedad Madrileña de Neumología y Cirugía Torácica (NEUMOMADRID); 2007. p. 85–97.
- McCool FD, Rosen MJ. Non-pharmacologic airway clearance therapies: ACCP evidence-based clinical practice guidelines. Chest. 2006;129 Suppl. 1:250S–9S.
- Farrero E, Antón A, Egea CJ, Almaraz MJ, Masa JF, Utrabo I, et al. Normativa sobre el manejo de las complicaciones respiratorias de los pacientes con enfermedad neuromuscular. Arch Bronconeumol. 2013;49:306–13.
- Al Jaaly E, Fiorentino F, Reeves BC, Ind PW, Angelini GD, Kemp S, et al. Effect of adding postoperative non-invasive ventilation to usual care to prevent pulmonary complications in patients undergoing coronary artery bypass grafting: a randomized controlled trial. J Thorac Cardiovasc Surg. 2013;146:912–8.
- Jaber S, Michelet P, Chanques G. Role of non-invasive ventilation (NIV) in the perioperative period. Best Pract Res Clin Anaesthesiol. 2010;24:253–65.