

latter is available on free access. The classification order of the journals for each index was reviewed and the possible correlation between both indicators was evaluated using Spearman's test.

The *Journal Citation Reports*[®] includes 50 specialized respiratory system journals and the *SCImago Journal & Country Rank* includes 98. In general, it was found that the top journals occupy similar positions in both classifications, as seen in Table 1, which lists the top 20 journals according to the SJR with their equivalent position in the IF. There was a very high correlation between the indicators for journals in this category ($r=0.94$; $P<.001$).

Our data reveal that use of the SJR index does not significantly change the classification of respiratory system journals compared to the IF. Moreover, its calculation methods address the main limitations attributed to IF, including nuances, such as citation weighting, that may improve the characterization of the journals. All these aspects, added to the fact that *SCImago Journal & Country Rank* is free access, lead us to believe that SJR may be at present be considered not only as a complement but also as an alternative to the IF.

References

1. Garfield E. The history and meaning of the journal impact factor. *JAMA*. 2006;295:90–3.
2. Falagas ME, Kouranos VD, Arencibia-Jorge R, Karageoropoulos. Comparison of SCImago journal rank indicator with journal impact factor. *FASEB J*. 2008;22:2623–8.
3. Bornmann L, Marx W, Gasparyan AY, Kitas GD. Diversity, value and limitations of the journal impact factor and alternative metrics. *Rheumatol Int*. 2012;32:1861–7.
4. The San Francisco Declaration on Research Assessment. Available from: <http://am.ascb.org/dora/> [accessed 11.09.13].
5. García-Pachón E, Padilla-Navas I. El factor de impacto y el índice h de las revistas biomédicas españolas. *Med Clin (Barc)*. 2014. <http://dx.doi.org/10.1016/j.medcli.2013.09.014>.

Eduardo García-Pachón,^{a,*} Ricardo Arencibia-Jorge^b

^a Sección de Neumología, Hospital General Universitario, Elche, Alicante, Spain

^b Centro Nacional de Investigaciones Científicas, La Habana, Cuba

*Corresponding author.

E-mail address: egpachon@gmail.com (E. García-Pachón).

Use of an Occlusion Balloon in Transbronchial Lung Cryobiopsy[☆]



Utilización de un balón de oclusión en la realización de biopsias pulmonares transbronquiales con criosonda

To the Editor:

With the aim of improving the diagnostic yield of transbronchial lung biopsy, cryotherapy probes have begun to be used for obtaining lung specimens. Studies evaluating the histological material from endobronchial tumors obtained by cryobiopsy have found that the specimens obtained are larger than those obtained with conventional forceps, and that the quality for histology is better.^{1,2}

From these data, the possibility of using cryoprobes as an alternative to the conventional method in the study of diffuse parenchymal lung disease has been proposed, and the results suggest that the technique improves diagnostic efficacy.³ Similarly, descriptive studies aimed at analyzing the viability and the safety of the technique have been performed and have shown no increase in adverse effects, even in lung transplantation patients.⁴

In this respect, the authors have analyzed the data from 77 patients with suspected diffuse interstitial disease randomized to undergo transbronchial lung biopsy with cryoprobe (39 patients) or conventional forceps (38 patients). A greater number of patients in the cryobiopsy group presented moderate bleeding compared to the conventional group (56.4% versus 34.2%, $P=.068$). However,

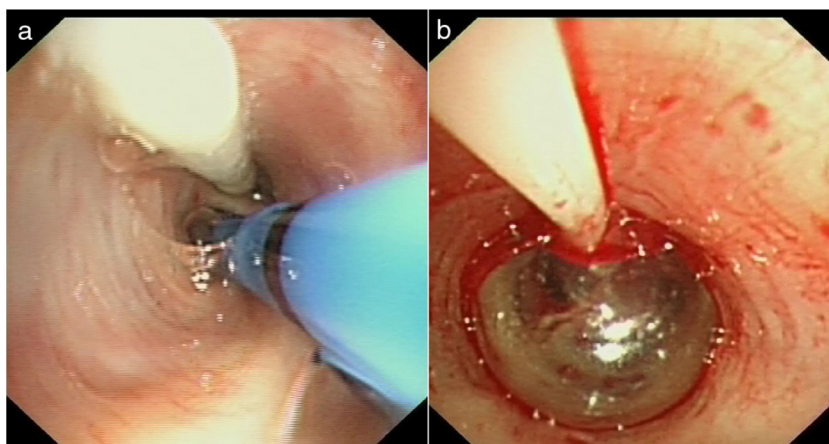


Fig. 1. (a) Endoscopic image of the occlusion balloon placed parallel to the cryoprobe in the entrance to the right lower lobe (RLL) segmental bronchus. (b) Endoscopic image of the inflated occlusion balloon after performing the transbronchial lung biopsy.

[☆] Please cite this article as: Pajares Ruiz V, Torrego Fernández A, Puzo Ardanuy C, Gil de Bernabé A. Utilización de un balón de oclusión en la realización de biopsias pulmonares transbronquiales con criosonda. *Arch Bronconeumol*. 2014;50:309–310.

this bleeding was not significant, the patients did not require other medical or surgical interventions, and the time of the procedure was not increased. For classification purposes, any bleeding that required suction and occlusion of the segmental bronchus was considered as moderate.

One of the features of this new technique is that, due to the size of the biopsies obtained, the bronchoscope has to be withdrawn with the specimen attached to the tip of the probe; therefore, unlike the conventional method, the endoscopic vision of the bronchial tree is lost for some seconds. Re-introduction of the bronchoscope and occlusion manoeuvres in the segmental bronchus in which the cryobiopsy has been performed may be complicated by the presence of bleeding. In this respect, the aim of using an occlusion balloon is not to reduce the amount of bleeding, but rather to provide better control of bleeding, should it occur. This aspect represents a change in the technique previously described by this group.⁵

Accordingly, before starting the procedure, an occlusion balloon is introduced (Model B5-2C[®], Olympus Medical Systems Corp, Tokyo, Japan) via the side channel of the endotracheal tube (Reference 104100. Broncoflex[®] 7.5 mm, Rüschi, Teleflex Medical, Durham, US) and placed at the entrance to the lung segment from which the transbronchial lung biopsy is to be obtained. Immediately after the specimen is obtained, the occlusion balloon is inflated until absence of bleeding is confirmed on endoscopy.

In conclusion, the preventive use of a hemostatic balloon allows the bleeding to be limited to an occluded area, in the case of hemorrhage. Although this does not directly reduce the intensity of any possible bleeding, it does facilitate endoscopy guiding (Fig. 1).

Conflict of Interests

The authors declare no conflict of interests.

References

1. Hetzel J, Hetzel M, Hasel C, Moeller P, Babiak A. Old meets modern: the use of traditional cryoprobes in the age of molecular biology. *Respiration*. 2008;76:193–7.
2. Hetzel J, Eberhardt R, Herth FJ, Petermann C, Reichle G, Freitag L, et al. Cryobiopsy increases the diagnostic yield of endobronchial biopsy: a multicentre trial. *Eur Respir J*. 2012;39:685–90.
3. Babiak A, Hetzel J, Krishna G, Fritz P, Moeller P, Balli T, et al. Transbronchial cryobiopsy: a new tool for lung biopsies. *Respiration*. 2009;77:1–6.
4. Yarmus L, Akulian J, Gilbert C, Illei P, Shah P, Merlo C, et al. Cryoprobe transbronchial lung biopsy in lung transplant patients: a safety pilot. *Chest*. 2013;143:621–6.
5. Pajares V, Torrego A, Puzo C, Lerma E, Gil de Bernabé MA, Franquet T. Transbronchial lung biopsy using cryoprobes. *Arch Bronconeumol*. 2010;46:111–5.

Virginia Pajares Ruiz,^{a,*} Alfons Torrego Fernández,^a
Carmen Puzo Ardanuy,^a Angels Gil de Bernabé^b

^a *Servicio de Neumología, Departamento de Medicina, Hospital de la Santa Creu i Sant Pau, Universidad Autónoma de Barcelona, Barcelona, Spain*

^b *Servicio de Anestesiología, Hospital de la Santa Creu i Sant Pau, Universidad Autónoma de Barcelona, Barcelona, Spain*

*Corresponding author.

E-mail address: vpajares@santpau.cat (V. Pajares Ruiz).