

Clinical Image

Hydropneumomediastinum Secondary to Gastric Volvulus Perforation in a Patient With Giant Hiatal Hernia[☆]



Hidroneumomediastino secundario a perforación de vólvulo gástrico en paciente con hernia de hiato gigante

Francisco Javier Garcipérez de Vargas,^{a,*} Sergio Luis Moyano Calvente,^b Gonzalo Marcos^a

^a Servicio de Cardiología, Hospital San Pedro de Alcántara, Cáceres, Spain

^b Servicio de Radiología, Hospital San Pedro de Alcántara, Cáceres, Spain

Pneumomediastinum is a rare entity. Among the most common causes are trauma and iatrogenesis, but multiple etiologies have been described for this condition, including diabetic ketoacidosis, gastric or esophageal perforation, pneumonia, lung cancer, cocaine use, etc. and even some spontaneous cases.^{1,2}

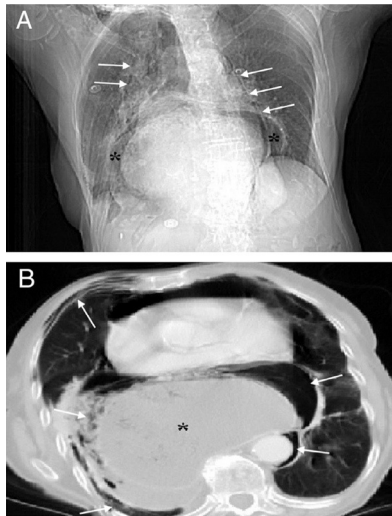


Fig. 1.

We report the case of a 96-year-old woman with a history of high blood pressure and hiatal hernia who presented with severe epigastric pain and coffee ground vomiting of 6 h duration. On physical examination, abdominal distention and epigastric tenderness were observed. Chest radiography revealed a gastric chamber distended into the chest cavity and pneumomediastinum. Thoracoabdominal CT (Fig. 1) showed gastric chamber distention at a thoracic level with gastroesophageal and gastroduodenal junction above the esophageal hiatus, accompanied by air and fluid collections in the mediastinum, along with subcutaneous emphysema. These findings were consistent with gastric perforation secondary to volvulus in a patient with giant hiatal hernia. Due to the advanced age of the patient, surgery was ruled out, and she died a few hours after admission.

References

1. Santalla Martínez M, Dacal Quintas R, Velázquez PM. Treatment with subcutaneous drainage in the pneumomediastinum and massive subcutaneous emphysema. Arch Bronconeumol. 2013;49:127–8.
2. Kikeeva A, Berrio Grajales D, García Pachón E. Spontaneous pneumomediastinum and pneumopericardium with respiratory failure. Arch Bronconeumol. 2011;47:318–9.

[☆] Please cite this article as: Garcipérez de Vargas FJ, Moyano Calvente SL, Marcos G. Hidroneumomediastino secundario a perforación de vólvulo gástrico en paciente con hernia de hiato gigante. Arch Bronconeumol. 2014 50:154.

* Corresponding author.

E-mail address: fj.garci@hotmail.com (F.J. Garcipérez de Vargas).