

adjusted antibiotic treatment, when possible, and surgical drainage are crucial. Drainage is required to evacuate the accumulated pus and to sterilize and close the pleural cavity, thus allowing good pulmonary mobility. Different procedures may be employed, such as closed drainage systems by tube thoracostomy, or partial costectomy, or open systems, such as open thoracostomy with the creation of a pleurocutaneous fistula that allows drainage without a tube. The timing of these treatments is not standardized, but the intravenous antibiotic should be maintained for a week and then oral treatment should be continued for 1–3 weeks, depending on the patient's clinical response.<sup>5</sup> With the combination of both treatments, a high cure rate is achieved with a low mortality rate (less than 5%); death, if it occurs, is usually secondary to the confluence of several mechanisms, such as respiratory failure, heart failure, mediastinitis, hematogenous spread or renal failure.<sup>1</sup>

## References

1. Akgül A, Örkü A, Örkü T, Yüksel M, Armen B. Approach to empyema necessitatis. *World J Surg*. 2011;35:981–4.

2. Primo V, Rueda C, Chiralt A, Solá J. Nódulo mamario por empiema necessitatis. *Cir Esp*. 2012;90:873.
3. Kono S, Nauser T. Contemporary empyema necessitatis. *Am J Med*. 2007;120:303–5.
4. Mizell K, Patterson K, Carter JE. Empyema necessitatis due to methicillin-resistant *Staphylococcus aureus*: case report and review of the literature. *J Clin Microbiol*. 2008;46:3534–6.
5. Llamas M, Domínguez I, Ovejero E, Pérez-Gala S, García-Díez A. Empyema necessitatis revisited. *Eur J Dermatol*. 2010;20:115–9.

Susana Pérez-Bru,<sup>a,\*</sup> David Martínez-Ramos,<sup>b</sup>  
José Luis Salvador-Sanchís<sup>b</sup>

<sup>a</sup> Servicio de Cirugía General y del Aparato Digestivo, Hospital Universitario Sant Joan, San Juan de Alicante, Alicante, Spain

<sup>b</sup> Servicio de Cirugía General y del Aparato Digestivo, Hospital General de Castellón, Castellón, Spain

\* Corresponding author.

E-mail addresses: susanaperezbru@gmail.com,  
susanabru.83@hotmail.com (S. Pérez-Bru).

## Idiopathic Lipoid Pneumonia Findings in Chest High Resolution Computed Tomography. A Case Report<sup>☆</sup>

### Hallazgos en la tomografía computarizada de tórax de alta resolución de la neumonía lipoidea idiopática. A propósito de un caso

To the Editor,

Lipoid pneumonia (LP) is an uncommon condition that occurs as a result of the deposit of exogenous or endogenous fatty materials in the lung tissue. The incidence of LP is between 1% and 2.5% according to some series of autopsies.<sup>1</sup>

We report the case of a 15-year-old male patient with a history of jaundice at the age of 4 days, febrile seizure at one year and 4 months, scarlatiniform syndrome at 5 years, erysipeloid rash at 7 years of age, and hip synovitis. He has been monitored by the pediatric department since he was 8 years old due to delayed growth and development, with episodes of coughing and exertional dyspnea. He was diagnosed with mild episodic asthma, and was treated with montelukast and albuterol as rescue medication, without improvement. The following analyses were performed: ANA, C3, C4, CD3, Nk, IgE, eosinophils, granulocyte function, immunoglobulins, TSH, test for celiac disease, sweat test, skin prick and radioallergosorbent test for food allergies; all results were normal. He has had contact with 2 canary birds from an early age, and with spray paints at 11–12 years of age (graffiti).

Upon admission to the pulmonology unit, the patient had dyspnea grade I–II. Physical examination revealed good coloration of the skin and mucous membranes, and finger clubbing. Baseline O<sub>2</sub> saturation was 93% and good vesicular breath sounds were perceived upon auscultation, with no added noises. Spirometry indicated FEV<sub>1</sub>: 44%, FVC: 47%, FEV<sub>1</sub>/FVC: 79, MMEF: 29%, although patient cooperation was incomplete. The chest X-ray showed an extensive bilateral alveolointerstitial pattern with

multilobar involvement. The examination was completed during hospitalization with high-resolution computed tomography (HRCT), in which marked alteration of the lung parenchyma was observed, with large ground-glass fields in all lobes, but predominantly basal. There was overlapping septal thickening, forming a crazy-paving pattern (Fig. 1). Furthermore, honeycombing areas were visible in the subpleural lung parenchyma at the level of both upper lobes, although predominantly in the right side.

In view of these findings, a transbronchial biopsy was performed. The histological study showed giant cells phagocytosing foreign body cholesterol crystals in the alveolar interstitium and alveolar spaces, along with both isolated and accumulated macrophages with microvacuolated cytoplasm. There was occasional eosinophilic pseudo-proteinaceous material in the alveolar spaces that was negative on PAS and Congo red staining. No microorganisms were observed. Histological findings were compatible with LP.

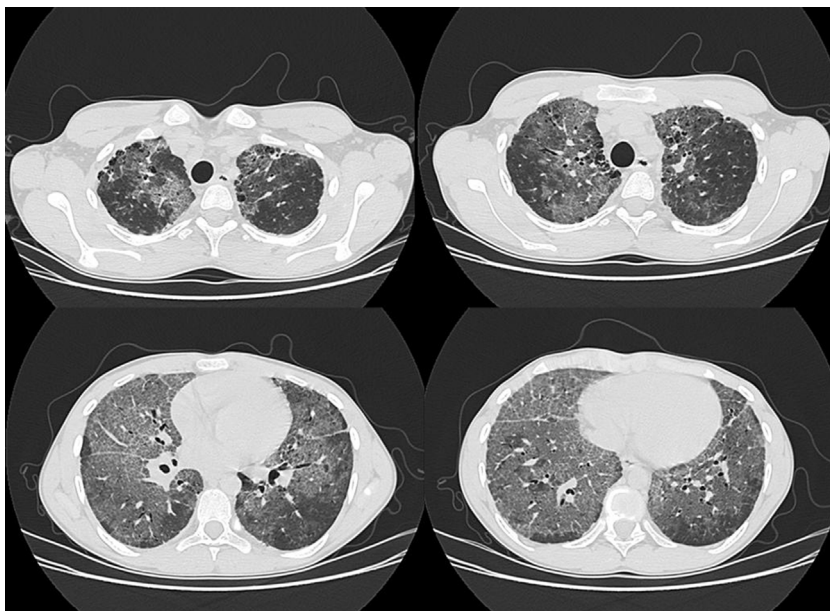
Currently the patient is receiving oral and inhaled corticosteroids, which have resulted in a clinical improvement, although the radiographic findings have shown no change.

In the absence of frequent use of laxatives, balms, oils or other lubricants, other causes of endogenous pneumonia should be assessed,<sup>1</sup> such as bronchial obstruction produced by a pulmonary tumor (clearly ruled out in our case), repeated episodes of respiratory fungal infection (not recorded in the patient's medical history nor suggested by histological or laboratory data), alveolar proteinosis (ruled out by pathology) and Niemann-Pick disease (mainly type B), in which crazy-paving pattern has also been described.<sup>2</sup> However, the patient did not present hepatosplenomegaly or any laboratory abnormality suggesting this possibility. Thus, in the absence of any other identifiable cause, this case was classified as idiopathic LP.<sup>3</sup>

The most common HRCT radiological findings in LP<sup>4,5</sup> are the presence of condensation with low attenuation coefficient (between –75 and –35 UH) that is very specific and prevalent in endogenous LP,<sup>1</sup> ground-glass opacities, crazy-paving pattern, and presence of centrilobular opacities. In addition, lung involvement is mainly basal.<sup>4</sup>

The crazy-paving pattern was initially described in alveolar proteinosis, although it was later shown to appear in

<sup>☆</sup> Please cite this article as: Eisman Hidalgo M, Nuñez-Delgado Y, García Espoña MÁ. Hallazgos en la tomografía computarizada de tórax de alta resolución de la neumonía lipoidea idiopática. A propósito de un caso. *Arch Bronconeumol*. 2014;50:83–84.



**Fig. 1.** Chest HRCT (axial slices) showing extensive, predominantly basal involvement of the lung parenchyma with the so-called crazy-paving pattern, associated with small areas of subpleural honeycombing in the upper lobes.

several processes,<sup>4</sup> including sarcoidosis, non-specific interstitial pneumonia, organizing pneumonia (both cryptogenic organizing pneumonia and bronchiolitis obliterans organizing pneumonia) pulmonary infections (mainly viral and mycoplasma), malignancies such as bronchoalveolar carcinoma, hemorrhage, pulmonary edema and LP.

#### Conflict of Interest

None of the named authors have conflicts of interest related to this manuscript.

#### References

1. Betancourt S, Martinez-Jimenez S, Rossi S, Truong M, Carrillo J, Erasmus J. Lipoid pneumonia: spectrum of clinical and radiologic manifestations. *Am J Roentgenol.* 2010;194:103-9.

2. Castañón-Martínez R, Fernández-Velilla M, González-Montaña V, Gómez-Carrera L, Torres-Sánchez MI. Afectación pulmonar en paciente adulto con enfermedad de Niemann-Pick tipo B. *Arch Bronconeumol.* 2012;48:213-5.
3. Chin NK, Hui KP, Cha TB. Idiopathic lipoid pneumonia in an adult treated with prednisolone. *Chest.* 1994;105:956-7.
4. Webb W, Müller NL, Naidich D. *Alta resolución en TC de pulmón.* 3.<sup>a</sup> ed. Madrid: Marban; 2003.
5. Gaerte SC, Meyer CA, Winer-Muram HT, Tarver RD, Conces DJ. Fat-containing lesions of the chest. *Radiographics.* 2002;22:S61-78.

Macarena Eisman Hidalgo,\* Yolanda Nuñez-Delgado,  
Miguel Ángel García Espona

*Servicio de Radiodiagnóstico, Empresa Pública Sanitaria Hospital de Poniente, El Ejido, Almería, Spain*

\* Corresponding author.

E-mail address: [macarenaeisman@hotmail.com](mailto:macarenaeisman@hotmail.com)  
(M. Eisman Hidalgo).