

Clinical Image

Chemotherapy-Induced Secondary Pneumothorax[☆]

Neumotórax secundario inducido por quimioterapia

Fernando Bazan,* Ivan Vollmer, Angel Gayete

Servicio de Radiodiagnóstico, Hospital del Mar, Parc de Salut Mar, Barcelona, Spain

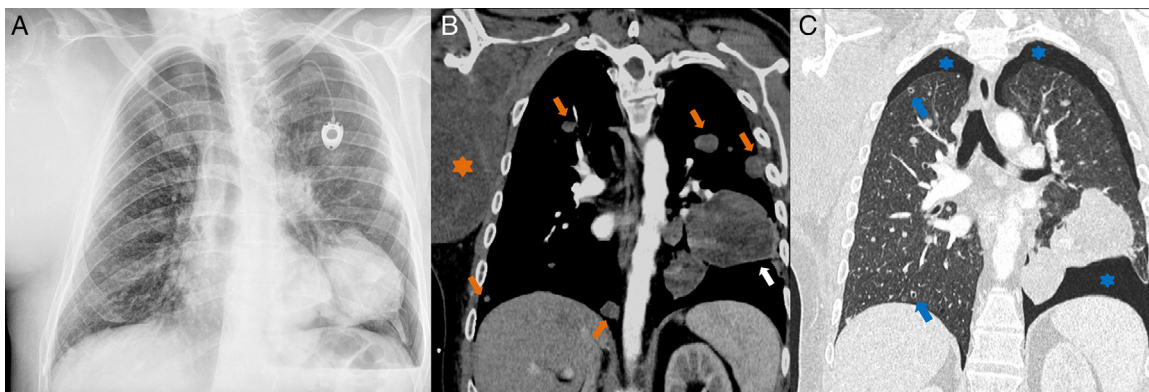


Fig. 1. Radiograph (A) and computed tomography (B, C) of the chest in which the sarcoma-axillary level right humerus (orange star) mass in the left lung (white arrow), several solid nodules (orange arrows) are visualized and cavitation (blue arrows) and mild bilateral pneumothorax (blue stars).

A male patient, 38 years of age, with history of synovial sarcoma of the right humerus, with local relapse and lung metastases, presented in the emergency department with moderate dyspnea (oxygen saturation 96%) and no other changes in vital signs. He had received his third chemotherapy session two days previously (temozolamide and bevacizumab).

A chest X-ray (Fig. 1A) and computed tomography (Fig. 1B, C) were performed which showed right humeral-axillary sarcoma, multiple lung metastases, some which were cavitated, and mild bilateral pneumothorax. In view of the radiological findings and the correlating clinical picture, a diagnosis was made of pneumothorax due to cavitation of metastases induced by chemotherapy, since the metastases were not cavitated in the previous examination.

The bilateral pneumothorax was treated conservatively and resolved fully 10 days later. Unfortunately, the patient died

several weeks later due to complications from his lung metastases.

Primary and metastatic lung neoplasms can cavitate spontaneously or after chemotherapy: if a cavitated lesion is located peripherally, it can open into the pleural space and cause spontaneous pneumothorax.^{1,2} The neoplasms that most frequently present this characteristic are the peripheral sarcomas: osteosarcoma, synovial sarcoma and angiosarcoma.^{1,2}

References

1. Fiorelli A, Vicidomini G, Napolitano F, Santini M. Spontaneous pneumothorax after chemotherapy for sarcoma with lung metastases: case report and consideration of pathogenesis. *J Thorac Dis.* 2011;3:138–40.
2. Hoag JB, Sherman M, Fasihuddin Q, Lund ME. A comprehensive review of spontaneous pneumothorax complicating sarcoma. *Chest.* 2010;138:510–8.

[☆] Please cite this article as: Bazan F, Vollmer I, Gayete A. Neumotórax secundario inducido por quimioterapia. *Arch Bronconeumol.* 2014;50:44.

* Corresponding author.

E-mail address: ferx.bazan@gmail.com (F. Bazan).