

Letters to the Editor

Septic Shock Due to *Rhodococcus equi* in a Patient With Chronic Myelomonocytic Leukemia[☆]**Shock séptico por *Rhodococcus equi* en paciente con leucemia mielomonocítica crónica**

To the Editor:

We describe a rare case of septic shock of pulmonary origin due to *Rhodococcus equi*, an emerging intracellular bacterium that causes zoonosis in our environment. Although generally transmitted to humans by inhalation, on this occasion contact with manure in an immunosuppressed patient with chronic myelomonocytic leukaemia (CMML) caused a serious lung infection.

Clinical Case

We present the case of a 79-year-old patient with a clinical history of myocardial infarction, heart failure and global respiratory failure. He had been diagnosed 12 months previously with CMML type 1, for which he had not been treated. He came into contact with the manure when using it as fertiliser.

He attended the emergency department due to a decreased level of consciousness, asthenia and drowsiness. Physical examination showed blood pressure 73/47 mmHg, heart rate 120 beats/min, mild fever and basal oxygen saturation of 86%. He was conscious, prone to bradypnoea and dehydrated. Laboratory tests revealed 59 900 leukocytes/mm³ with 90% neutrophils and 46 000 platelets/mm³. Previous tests carried out for regular monitoring of his CMML showed leukocytes 15 000/mm³. Chest X-ray showed a rounded high attenuation area in the right hemithorax, with no air bronchogram, measuring 5 cm × 4 cm, on the right parahilar region (Fig. 1a). Blood cultures were drawn and

intravenous imipenem treatment was initiated empirically, due to suspected sepsis and pulmonary mass.

Thoracoabdominal computed tomography (CT) was performed (Fig. 1b), showing a heterogeneous mass with marginal spiculation, 5 cm in diameter, located in the anterolateral segment of the right upper lobe, with wide pleural contact. Radiologically, the lesion was suggestive of lung neoplasm. Fine needle aspiration was carried out, revealing acute abscessing inflammation associated with a pattern of organizing pneumonia, with no evidence of malignancy. HIV serology was negative. Finally, blood cultures were positive for *R. equi*.

Patient progress was excellent with imipenem during his hospitalization and following sequential therapy at home with ciprofloxacin and oral rifampicin. Three months later, the pulmonary mass had disappeared and 12 months later the patient remained asymptomatic with periodic check-ups at the haematology clinic.

Discussion

The first infection caused by *R. equi* in man was described in 1967. It showed a chronic granulomatous process characterized by aggregates of PAS positive histocytes that contained inclusions known as Michaelis–Gutmann bodies (malacoplakia) and necrotizing abscesses associated with intracellular Gram positive cocci, characteristic of *R. equi* infection.¹ Despite this, malacoplakia is not specific to this infection, as *Mycobacterium tuberculosis*, *Pasteurella multocida* and *Escherichia coli* can cause histologically similar lesions, although not as often in immunocompromised patients.² The primary infection occurs in the lung in approximately 80% of cases, often presenting cavitated consolidation in the upper lobe.³ It is a rare pathogen in immunocompetent patients, which represent 10%–15% of cases, mainly renal transplant patients.² In

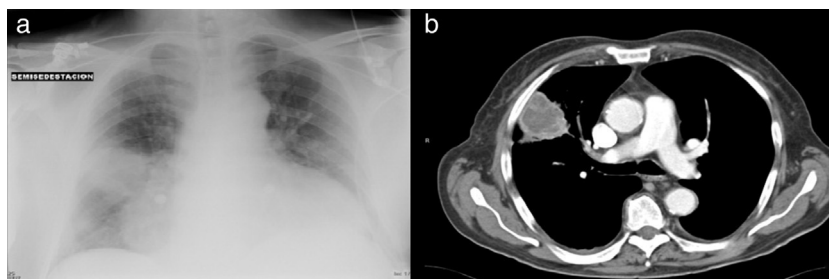


Fig. 1. Chest radiograph (a) and chest CT scan (b) right parahilar mass.

[☆] Please cite this article as: Josa Laorden C, Gómez del Valle C, Bucar Barjud M, Amores Arriaga MB, Torralba Cabeza MA, Pérez Calvo JI. Shock séptico por *Rhodococcus equi* en paciente con leucemia mielomonocítica crónica. Arch Bronconeumol. 2013;49:497–498.

2010, the first case was reported in which a patient with chronic lymphoid leukaemia developed cavitated pneumonia caused by this microorganism after receiving fluarabin treatment.⁴

It should be suspected in immunosuppressed patients who present with pneumonia with an insidious clinical course, pulmonary abscess, granulomatous lesions, brain abscess or fever of unknown origin. The radiological differential diagnosis should be made mainly with pneumonia due to *Pneumocystis jirovecci* or *Staphylococcus aureus*, central bronchogenic carcinoma and pulmonary tuberculosis. *R. equi* is usually susceptible to combined antibiotic therapies, which include macrolides, rifampicin, aminoglycosides and imipenem. Two or three antibiotics should always be combined; those with intracellular activity, such as rifampicin or azithromycin, are recommended. With respect to the prognosis, the mortality reaches 50% in HIV patients, 25% in other types of immunosuppression and 11% in immunocompromised patients.⁵

It is exceptionally observed in immunocompromised patients who do not have HIV, as in our case, where despite not being on active immunosuppressant treatment, the cellular immunosuppression caused by the myelomonocytic leukaemia and contact with the contaminated manure triggered this serious lung infection.

References

1. Romero A, Dominguez B, García-Gil D, Vergara de Campos A. Pulmonary malacoplakia associated with *Rhodococcus equi* infection in a patient with AIDS. *Enferm Infecc Microbiol Clin.* 2009;27:63-4.
2. Yamshchikov AV, Schuetz A, Lyon GM. *Rhodococcus equi* infection. *Lancet Infect Dis.* 2010;10:350-9.
3. Weinstock DM, Brown AE. *Rhodococcus equi*: an emerging pathogen. *Clin Infect Dis.* 2002;34:1379-85.
4. Gelfand MS, Cleveland KO, Brewer SC. *Rhodococcus equi* pneumonia in a patient with fludarabine-treated chronic lymphocytic leukemia and CD4-lymphopenia. *Am J Med Sci.* 2010;340:80-1.
5. Camponovo R, García P. *Rhodococcus equi*. *Rev Chil Infect.* 2006;23:155-6.

Claudia Josa Laorden,* Carmen Gómez del Valle,
Marina Bucar Barjud, Maria Beatriz Amores Arriaga,
Miguel Angel Torralba Cabeza, Juan Ignacio Pérez Calvo

Servicio de Medicina Interna, Hospital Clínico Universitario Lozano Blesa, Zaragoza, Spain

* Corresponding author.

E-mail address: claudiajosa@gmail.com (C. Josa Laorden).

Pulmonary Eosinophilia Caused by Testosterone Cypionate[☆]

Eosinofilia pulmonar por cipionato de testosterona

To the Editor,

We present a case of acute lung toxicity with eosinophilia due to testosterone cypionate, which to our knowledge is the first case described in the literature.

The patient was a 39-year-old male who presented with sudden onset dyspnoea, coughing with a little blood-stained sputum and feeling feverish. *Anamnesis*: no substance abuse, firefighter by profession. He was involved in bodybuilding during his spare time and had been using hormone supplements intermittently for 20 years. He had begun a new cycle of testosterone cypionate four weeks earlier, taking a weekly dose of 250 mg. On the *physical examination*, he was found to be in general poor health, with profuse sweating, tachypnoea with respiratory rate 28 bpm and temperature of 38 °C. Auscultation revealed fine crackles in both lung bases. *Arterial blood gases*: pH 7.44, PaCO₂ 34 mmHg, PaO₂ 62 mmHg. *Laboratory tests*: complete blood count, leukocytes 19,900/μl with predominantly neutrophils (88%, 17 600/μl),

lymphocytes (4%, 810/μl), eosinophils (0.2%, 40/μl), C-reactive protein 13.3 mg/l. Quick index 99%. D-dimer 575 ng/ml. Blood glucose, renal function and electrolytes are normal. Serum complement and immunoglobulins are normal. Auto-antibodies test is negative. *Chest computed tomography (CT) scan*: presence of areas of ground-glass opacity predominantly in bases and dependent regions, septal thickening (Fig. 1a). *Fibrobronchoscopy*: normal. Microbiological study of the bronchoalveolar lavage (BAL) and bronchial aspirate was negative. Pathological study of the BAL showed a smear with a haematic background and abundant cellularity consisting of alveolar macrophages, with a considerable number of atypical hyperplastic pneumocytes and abundant eosinophils (25%), compatible with a diagnosis of eosinophilia with atypical pneumocyte hyperplasia (Fig. 1b).

Initial treatment was prescribed with oxygen therapy, intravenous levofloxacin and anti-pyretics. On the second day of admission, the patient had symptomatic improvement with disappearance of the dyspnoea and control of the fever; the chest radiograph and arterial blood gases were normal on the fifth day. Two weeks later the patient was asymptomatic and had stopped

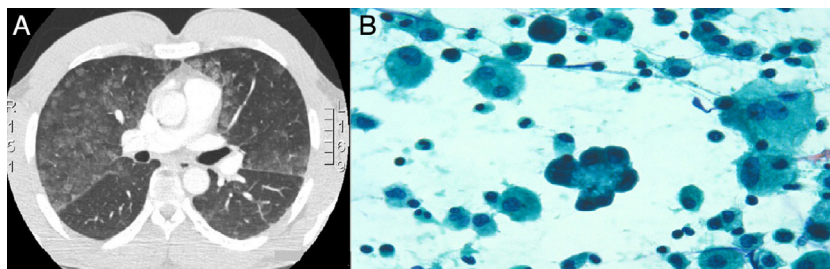


Fig. 1. (A) CT chest: ground glass opacities of dominance lower lobes. (B) Bronchoalveolar lavage hyperplastic pneumocytes and significant eosinophilia.

[☆] Please cite this article as: Monclou Garzón E, Carrión Valero F, Urbano Salcedo A. Eosinofilia pulmonar por cipionato de testosterona. *Arch Bronconeumol.* 2013;49:498-499.