

2010, the first case was reported in which a patient with chronic lymphoid leukaemia developed cavitated pneumonia caused by this microorganism after receiving fluarabin treatment.<sup>4</sup>

It should be suspected in immunosuppressed patients who present with pneumonia with an insidious clinical course, pulmonary abscess, granulomatous lesions, brain abscess or fever of unknown origin. The radiological differential diagnosis should be made mainly with pneumonia due to *Pneumocystis jirovecci* or *Staphylococcus aureus*, central bronchogenic carcinoma and pulmonary tuberculosis. *R. equi* is usually susceptible to combined antibiotic therapies, which include macrolides, rifampicin, aminoglycosides and imipenem. Two or three antibiotics should always be combined; those with intracellular activity, such as rifampicin or azithromycin, are recommended. With respect to the prognosis, the mortality reaches 50% in HIV patients, 25% in other types of immunosuppression and 11% in immunocompromised patients.<sup>5</sup>

It is exceptionally observed in immunocompromised patients who do not have HIV, as in our case, where despite not being on active immunosuppressant treatment, the cellular immunosuppression caused by the myelomonocytic leukaemia and contact with the contaminated manure triggered this serious lung infection.

## References

- Romero A, Dominguez B, García-Gil D, Vergara de Campos A. Pulmonary malacoplakia associated with *Rhodococcus equi* infection in a patient with AIDS. *Enferm Infecc Microbiol Clin*. 2009;27:63-4.
- Yamshchikov AV, Schuetz A, Lyon GM. *Rhodococcus equi* infection. *Lancet Infect Dis*. 2010;10:350-9.
- Weinstock DM, Brown AE. *Rhodococcus equi*: an emerging pathogen. *Clin Infect Dis*. 2002;34:1379-85.
- Gelfand MS, Cleveland KO, Brewer SC. *Rhodococcus equi* pneumonia in a patient with fludarabine-treated chronic lymphocytic leukemia and CD4-lymphopenia. *Am J Med Sci*. 2010;340:80-1.
- Camponovo R, García P. *Rhodococcus equi*. *Rev Chil Infect*. 2006;23:155-6.

Claudia Josa Laorden,\* Carmen Gómez del Valle,  
Marina Bucar Barjud, Maria Beatriz Amores Arriaga,  
Miguel Angel Torralba Cabeza, Juan Ignacio Pérez Calvo

Servicio de Medicina Interna, Hospital Clínico Universitario Lozano Blesa, Zaragoza, Spain

\* Corresponding author.

E-mail address: [claudiajosa@gmail.com](mailto:claudiajosa@gmail.com) (C. Josa Laorden).

## Pulmonary Eosinophilia Caused by Testosterone Cypionate<sup>☆</sup>

### Eosinofilia pulmonar por cipionato de testosterona

To the Editor,

We present a case of acute lung toxicity with eosinophilia due to testosterone cypionate, which to our knowledge is the first case described in the literature.

The patient was a 39-year-old male who presented with sudden onset dyspnoea, coughing with a little blood-stained sputum and feeling feverish. *Anamnesis*: no substance abuse, firefighter by profession. He was involved in bodybuilding during his spare time and had been using hormone supplements intermittently for 20 years. He had begun a new cycle of testosterone cypionate four weeks earlier, taking a weekly dose of 250 mg. On the *physical examination*, he was found to be in general poor health, with profuse sweating, tachypnoea with respiratory rate 28 bpm and temperature of 38 °C. Auscultation revealed fine crackles in both lung bases. *Arterial blood gases*: pH 7.44, PaCO<sub>2</sub> 34 mmHg, PaO<sub>2</sub> 62 mmHg. *Laboratory tests*: complete blood count, leukocytes 19,900/μl with predominantly neutrophils (88%, 17 600/μl),

lymphocytes (4%, 810/μl), eosinophils (0.2%, 40/μl), C-reactive protein 13.3 mg/l. Quick index 99%. D-dimer 575 ng/ml. Blood glucose, renal function and electrolytes are normal. Serum complement and immunoglobulins are normal. Auto-antibodies test is negative. *Chest computed tomography (CT) scan*: presence of areas of ground-glass opacity predominantly in bases and dependent regions, septal thickening (Fig. 1a). *Fibrobronchoscopy*: normal. Microbiological study of the bronchoalveolar lavage (BAL) and bronchial aspirate was negative. Pathological study of the BAL showed a smear with a haematic background and abundant cellularity consisting of alveolar macrophages, with a considerable number of atypical hyperplastic pneumocytes and abundant eosinophils (25%), compatible with a diagnosis of eosinophilia with atypical pneumocyte hyperplasia (Fig. 1b).

Initial treatment was prescribed with oxygen therapy, intravenous levofloxacin and anti-pyretics. On the second day of admission, the patient had symptomatic improvement with disappearance of the dyspnoea and control of the fever; the chest radiograph and arterial blood gases were normal on the fifth day. Two weeks later the patient was asymptomatic and had stopped

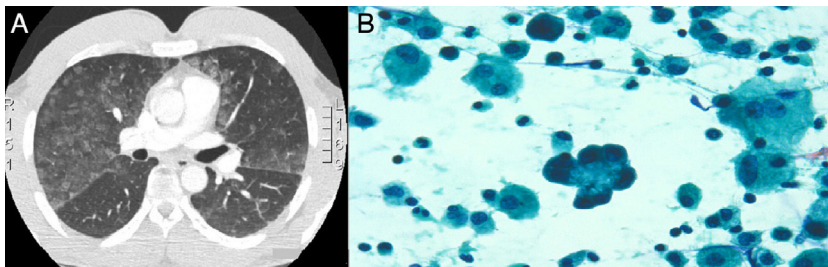


Fig. 1. (A) CT chest: ground glass opacities of dominance lower lobes. (B) Bronchoalveolar lavage hyperplastic pneumocytes and significant eosinophilia.

<sup>☆</sup> Please cite this article as: Monclou Garzón E, Carrión Valero F, Urbano Salcedo A. Eosinofilia pulmonar por cipionato de testosterona. *Arch Bronconeumol*. 2013;49:498-499.

using hormone supplements. The respiratory function examination, including a diffusion test and chest CT, was normal.

In the clinical setting, androgens are mainly used in testosterone replacement therapy in male hypogonadism.<sup>1</sup> The use of testosterone cypionate, despite being banned in competition, is well known in sport for achieving greater strength and enhanced performance, and in bodybuilding for obtaining a rapid increase in muscle mass. In a literature search performed on Pneumotox<sup>2</sup> and MEDLINE up to February 2012, we did not find any association between the use of testosterone cypionate and lung toxicity. However, Ramos Villalobos et al.<sup>4</sup> reported a case similar to ours caused by the use of methenolone, another anabolic substance used in bodybuilding.

The causal relationship with the drug, presence of infiltrates and confirmation of tissue eosinophilia by BAL led us to consider the possibility of lung toxicity,<sup>3</sup> having ruled out other infectious, vascular, autoimmune and immunological conditions. In fact, in our case, there was a temporal relationship to the start of four weeks testosterone cypionate therapy from the first dose, and the symptomatology coincided with the recent use of the following dose, which corresponded to the patient according to the cycle that he had been following. Furthermore, he improved rapidly when the drug was withdrawn, with radiology and respiratory function returning to normal. It is important to highlight that systemic corticosteroids were not used.

As often happens with drug-induced lung toxicity, the patient was admitted with suspected community-acquired pneumonia, although this diagnosis was not confirmed either by microbiological studies or the subsequent evolution. In drug-induced lung disease, high resolution CT shows histological findings that resemble those in other entities such as infection and pulmonary fibrosis.<sup>5</sup> The finding of eosinophilia in the BAL reinforced the hypothesis of drug toxicity.<sup>6</sup>

In conclusion, the current case together with the case reported recently by Ramos Villalobos et al.<sup>4</sup> could provide evidence to indicate that the use of testosterone-derived anabolic substances for sport can cause lung toxicity. Attention should be paid in the future to the use of these substances and their possible relationship with physiopathological changes that lead to lesions in the lung parenchyma.

#### Conflict of Interests

The authors declare that they have no conflict of interests.

#### References

1. Jubiz W, Cruz EA. Hipogonadismo masculino: causas, genética, diagnóstico y tratamiento. *Colom Med.* 2007;38:84–91.
2. Available from: [www.pneumotox.com](http://www.pneumotox.com) [accessed 11.02.12].
3. Camus PH, Foucher P, Bonniaud PH, Ask K. Drug-induced infiltrative lung disease. *Eur Respir J.* 2001;32 Suppl.:S93–100.
4. Ramos Villalobos G, Gullón Blanco J, Gonzalez Martin I. Toxicidad pulmonar por metenolona: a propósito de un caso. *Arch Bronconeumol.* 2009;45:622–3.
5. Ellis SJ, Cleverley JR, Müller NL. Drug-induced lung disease, high-resolution CT findings. *Am J Roentgenol.* 2000;175:1019–24.
6. Cottin V, Cordier JF. Eosinophilic pneumonias. *Allergy.* 2005;60:841–57.

Erick Monclou Garzón,<sup>a,\*</sup> Francisco Carrión Valero,<sup>a</sup>  
Andrea Urbano Salcedo<sup>b</sup>

<sup>a</sup> *Servicio de Neumología, Hospital Clínico Universitario de Valencia, Valencia, Spain*

<sup>b</sup> *Servicio de Anatomía Patológica, Hospital Clínico Universitario de Valencia, Valencia, Spain*

\* Corresponding author.

E-mail address: [emonclou@hotmail.com](mailto:emonclou@hotmail.com) (E. Monclou Garzón).