



Case Report

Chest Wall Reconstruction With Methacrylate Prosthesis in Poland Syndrome[☆]

Elisabet Arango Tomás,* Carlos Baamonde Laborda, Javier Algar Algar, Angel Salvatierra Velázquez

Unidad de Gestión Clínica de Cirugía Torácica y Trasplante Pulmonar, Hospital Universitario Reina Sofía, Córdoba, Spain

ARTICLE INFO

Keywords:

Poland syndrome
Reconstruction with methyl methacrylate prosthesis
Chest wall reconstruction

ABSTRACT

Poland syndrome is a rare congenital malformation. This syndrome was described in 1841 by Alfred Poland at Guy's Hospital in London. It is characterized by hypoplasia of the breast and nipple, subcutaneous tissue shortages, lack of the costosternal portion of the pectoralis major muscle and associated alterations of the fingers on the same side. Corrective treatment of the chest and soft tissue abnormalities in Poland syndrome varies according to different authors. We report the case of a 17-year-old adolescent who underwent chest wall reconstruction with a methyl methacrylate prosthesis. This surgical procedure is recommended for large anterior chest wall defects, and it prevents paradoxical movement. Moreover it provides for individual remodeling of the defect depending on the shape of the patient's chest.

© 2012 SEPAR. Published by Elsevier España, S.L. All rights reserved.

Reconstrucción torácica con prótesis de metacrilato en el síndrome de Poland

RESUMEN

El síndrome de Poland es una malformación congénita infrecuente. Se trata de una anomalía descrita en 1841 por Alfred Poland en el Guy's Hospital de Londres, caracterizada por hipoplasia de la mama y el pezón, escasez de tejido subcutáneo y ausencia de la porción costoesternal del músculo pectoral mayor, que se asocia a alteraciones de los dedos de la mano del mismo lado. La corrección de las anomalías del tórax y los tejidos blandos en el síndrome de Poland varía según el autor. Presentamos el caso de una adolescente de 17 años en el que se elige una prótesis de metilmetacrilato para la reconstrucción de la pared torácica. Este procedimiento quirúrgico está recomendado en grandes defectos de la parte anterior del tórax e impide el movimiento paradójico de la misma. Además nos permite una remodelación individual del defecto de acuerdo con la forma del tórax.

© 2012 SEPAR. Publicado por Elsevier España, S.L. Todos los derechos reservados.

Palabras clave:

Síndrome de Poland
Reconstrucción con prótesis de metilmetacrilato
Reconstrucción de la pared torácica

Introduction

Poland syndrome is a rare congenital malformation. It was first described in 1841 by Alfred Poland at Guy's Hospital in London,¹ and is characterized by hypoplasia of the breast and nipple, scarcity of subcutaneous tissue and absence of the costosternal portion of the pectoralis major muscle, associated with alterations of the fingers on the same side. Corrective treatment of the chest and soft tissue abnormalities in Poland syndrome varies according to the author. We present the case of a 17-year-old adolescent who underwent chest wall reconstruction with a methyl methacrylate prosthesis. This surgical procedure is recommended for large anterior chest wall defects, and prevents paradoxical movement.

Moreover, it enables individual remodeling of the defect depending on the shape of the patient's chest.

Clinical Observation

We report the case of a 17-year-old adolescent who was referred from the pediatric department for right Poland syndrome reconstruction.

Physical Examination

On physical examination, the patient presented chest asymmetry with excavation of the right hemithorax, and had undergone surgery on the right hand for syndactyly and clinodactyly. Paradoxical movement of the right hemithorax and hypertelorism were also observed. He reported retrosternal pain on deep inspiration, fatigue and mild dyspnea on exertion. Cardiopulmonary auscultation revealed a non-displaced apex beat.

[☆] Please cite this article as: Arango Tomás E, et al. Reconstrucción torácica con prótesis de metacrilato en el síndrome de Poland. Arch Bronconeumol. 2013;49:450–2.

* Corresponding author.

E-mail address: eli.piano@hotmail.com (E. Arango Tomás).

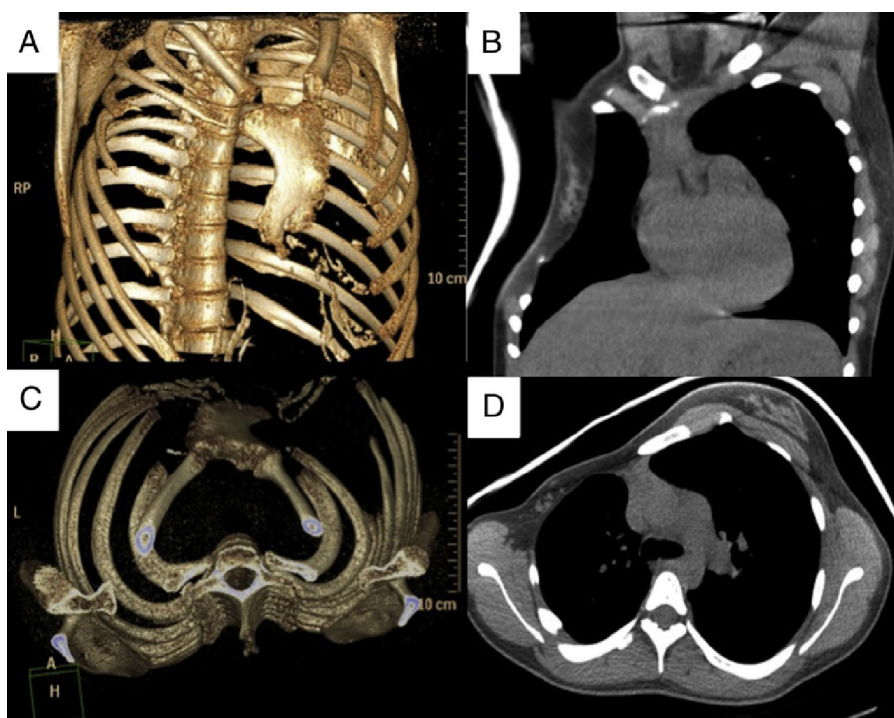


Fig. 1. 3D reconstruction of the chest wall defect: (A) anteroposterior view with rotation to the left; (B) craniocaudal view. View the defect on chest CT (mediastinal window): (C) coronal slice; (D) axial slice.

Chest Radiograph

Chest X-ray showed asymmetry of both hemithorax due to the decreased size of the right one, given the absence of pectoral muscles on that side.

Chest and 3D Computed Tomography

Imaging studies showed agenesis of the right pectoralis major and minor muscles and ipsilateral costal abnormalities, with hypoplasia of the third, fourth and fifth costal arches. Hypoplasia of the right lung and mammary gland was also observed. The arterial branch, originating in the abdominal artery and supplying the posterior-basal segment of the right lower lobe, was abnormal (finding confirmed by angio-TC) (Fig. 1).

Ventilation/Perfusion Scintigraphy

Scanning showed homogeneous distribution of both tracers, with no ventilation or perfusion defects.

Lung Function Tests

Results were consistent with mild restrictive lung disease (FVC 2620 ml (69%), FEV₁ 2560 ml/s (80%), IT 98).

Due to the severity of the Poland syndrome in the patient, it was decided to use a joint approach with plastic surgery. Surgery was performed by anterior thoracotomy under general anesthesia and orotracheal intubation. Neither a pleural opening nor resection of hypoplastic costal fragments was required. Complete chest wall reconstruction was carried out by stabilization with a preformed methyl methacrylate prosthesis and covered with a right latissimus dorsi myocutaneous flap with a skin island for recreation of the areola-nipple complex (Fig. 2) in the subsequent breast reconstruction and symmetrization. The patient progressed well

post-operatively, meeting discharge criteria on the seventh day post-surgery.

Six months later, a 350 cc tissue expander was implanted subcutaneously and filled intraoperatively with 90 cc by the plastic surgery team. A third surgical procedure was then performed 6 months later to remove the expander in the right breast with inferior and superior capsulotomy before inserting a Mentor® CPG™ 323 345 cc breast prosthesis; dissection of a subpectoral pocket was carried out in the left breast to insert a Mentor® CPG™ 322 165 cc breast implant. The post-operative period was uneventful and the patient was discharged on the fourth day with no complications.

She does not report any respiratory symptoms at present and is satisfied with the esthetic result. No paradoxical chest movements have been observed in the post-surgery follow-up.

Discussion

Poland syndrome is a rare congenital malformation, with an incidence of one case in every 30 000–40 000 newborns. It is characterized by hypoplasia or absence of the breast or nipple, hypoplasia of subcutaneous tissue, absence of the costosternal portion of the pectoralis major muscle, absence of the pectoralis minor muscle and absence of costal cartilages or ribs 2, 3, and 4 or 3, 4, and 5. The chest wall defect is often associated with a lung hernia. Clinical manifestations are extremely variable and are seldom all seen in a single case.² Its etiopathogenesis appears to be multifactorial, and the main theory suggests abnormal migration of the embryonic tissues that form the pectoral muscles, causing hypoplasia of the subclavian artery and reduced blood flow in the pectoral region. Most cases are sporadic, although a familial factor has been described in its etiology.³ Seventy-five percent of cases have abnormalities in the right hemithorax. When Poland syndrome occurs on the left side and is associated with dextrocardia, some hypotheses argue that mechanical factors during embryonic life could explain this strong association.⁴ Hypoplasia of the sternocostal portion of the pectoralis major is the most widely described feature, and

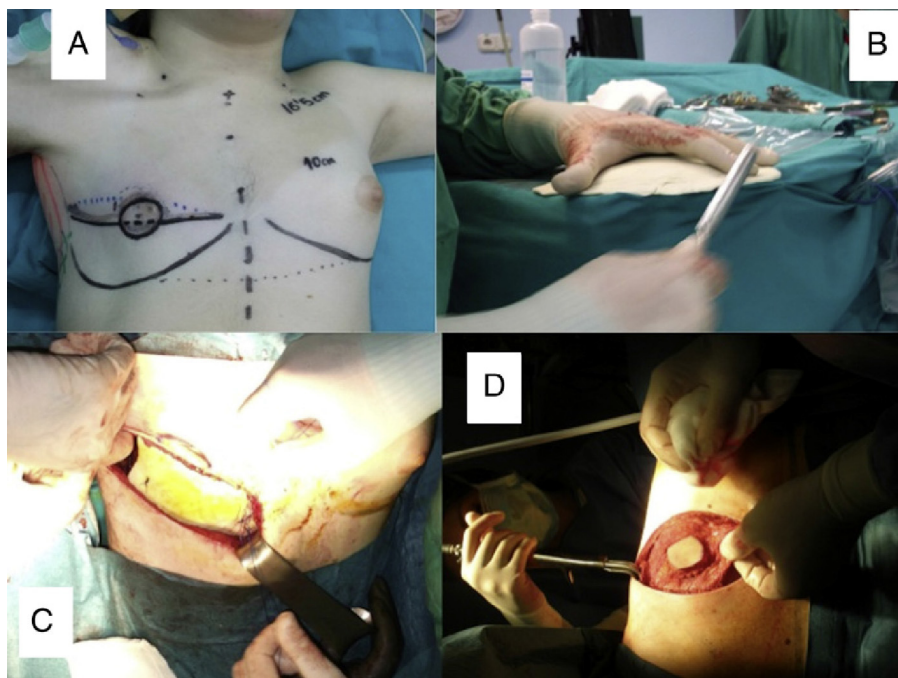


Fig. 2. (A) Surgical site markings. (B) Construction and remodeling of the methacrylate prosthesis on the table. (C) Complete reconstruction of the chest wall defect by stabilization with a preformed methyl methacrylate prosthesis. (D) Cover with right latissimus dorsi flap with skin island for subsequent reconstruction of the areola-nipple complex.

is often associated with homolateral breast hypoplasia. Another associated condition is syndactyly, so that 10% of patients with syndactyly present findings of the syndrome. Surgical treatment of Poland syndrome is indicated in cases in which there is unilateral depression of the chest wall with a risk of progression, lack of protection of the lung or heart, paradoxical movement of the chest wall, breast hypoplasia or aplasia in women, or in cases in which there is a cosmetic defect due to lack of the pectoralis major muscle in men.⁵ Corrective treatment of chest and soft tissue abnormalities in Poland syndrome differs among authors. Many recommend a latissimus dorsi flap combined with a breast implant in severe cases.⁶ If a prosthesis is to be used, the size and site of the lesion must be taken into account when choosing it; rigid prostheses are preferred for sternal and parasternal defects and soft prostheses for lateral defects.⁷ Losken et al.⁸ reported a higher frequency of lateral defects that required stabilization with prostheses, compared with anterior and posterior defects. The use of prostheses is recommended when in doubt, as they do not appear to increase septic complications or foreign body reactions. The choice of a methyl methacrylate prosthesis for chest wall reconstruction with or without muscle flaps can be performed safely and effectively. This surgical procedure is recommended in large anterior chest wall defects and prevents paradoxical movement, reducing the need for mechanical ventilation and improving lung function in the post-operative period.^{9,10} The use of these methacrylate prostheses enables individualized remodeling of the defect depending on the shape of the patient's chest. The final decision on the type of prosthesis to be used depends on the policy of the unit. In our case, we opted for this type of prosthesis due to the large anterior defect; furthermore, construction and remodeling of the prosthesis on the table allowed us better configuration of the prosthesis according to the shape of the chest wall, resulting in better functional outcomes and preventing injuries related with the heat emitted by the methyl

methacrylate during the polymerization process. There are many techniques for subsequent reconstruction of anomalous breast volume, but the deformities in Poland syndrome are a challenge. Some authors¹¹ recommend the omental flap because it improves the esthetic result, with outcomes that seem superior to any other reconstructive option. Depending on the quality of the soft tissues, the expansion can be an alternative or temporary solution during growth.⁴ The repair will depend on the patient's anatomical type and sex.¹²

References

- Poland A. Deficiency of the pectoral muscles. *Guy Hosp Rep.* 1841;6:191–3.
- Urschel Jr HC. Poland syndrome. *Semin Thorac Cardiovasc Surg.* 2009;21:89–94.
- Sierra Santos L, González Rodríguez MP. Poland syndrome: description of two patients in the same family. *Ann Pediatr (Barc).* 2008;69:49–51.
- Torre M, Baban A, Buluggiu A, Costanzo S, Bricco L, Lerone M, et al. Dextrocardia in patients with Poland syndrome: phenotypic characterization provides insight into the pathogenesis. *J Thorac Cardiovasc Surg.* 2010;139:1177–82.
- Folkin AA, Robicsek F. Poland's syndrome revisited. *Ann Thorac Surg.* 2002;74:2218–25.
- Baratte A, Bodin F, del Pin D, Wilk A, Bruant C. Poland's syndrome in women: therapeutic indications according to the grade. A propos of 11 cases and review of the literature. *Ann Chir Plast Esthet.* 2011;56:33–42.
- Kiliç D, Findikioğlu A, Bilen A, Hatipoğlu A. Mersilene mesh-methyl methacrylate sandwich graft reconstruction for repair of chest wall defects. *Tuberk Toraks.* 2006;54:363–9.
- Losken A, Thourani VH, Carlson GW, Jones GE, Culbertson JH, Miller JJ, et al. A reconstructive algorithm for plastic surgery following extensive chest wall resection. *Br J Plast Surg.* 2004;57:295–302.
- Thomas PA, Brouchet L. Prosthetic reconstruction of the chest wall. *Thorac Surg Clin.* 2010;20:551–8.
- Lee SY, Lee SJ, Lee CS. Sternum resection and reconstruction for metastatic renal cell cancer. *Int J Surg Case Rep.* 2011;2:45–6.
- Dos Santos Costa S, Blotta RM, Mariano MB, Meurer L, Edelweiss MI. Aesthetic improvements in Poland's syndrome treatment with omentum flap. *Aesthetic Plast Surg.* 2010;34:634–9.
- Seyfer AE, Fox JP, Hamilton CG. Poland syndrome: evaluation and treatment of the chest wall in 63 patients. *Plast Reconstr Surg.* 2010;126:902–11.