



Case Report

Diagnostic Imaging of Pulmonary Embolism Using Endobronchial Ultrasound[☆]Ayşegül Şentürk,^{*} Emine Argüder, Elif Babaoğlu, Habibe Hezer, H. Canan Hasanoğlu

Department of Chest Diseases, Ankara Atatürk Training and Research Hospital, Ankara, Turkey

ARTICLE INFO

Article history:

Received 26 July 2012

Accepted 30 August 2012

Available online 1 May 2013

Keywords:

Diagnostic imaging

Pulmonary

Thromboembolism

Endobronchial

Ultrasound

ABSTRACT

Endobronchial ultrasound (EBUS) is a new technique that can be used for the diagnostic imaging of central pulmonary thromboembolism (PE). In eight cases at our clinic, EBUS was used because of mediastinal lymphadenopathies or paramediastinal nodular lesions and at the same time images of a PE were obtained by means of EBUS. The PE was diagnosed before the EBUS with computed tomography (CT) of the lungs in all cases (5 women and 3 men). The repletion defects of all the cases compatible with a PE were clarified with CT-angiography. EBUS may be an alternative method for the diagnosis of PE, since it can indicate the presence of a thrombus in the central pulmonary arteries in hemodynamically stable cases.

© 2012 SEPAR. Published by Elsevier España, S.L. All rights reserved.

Diagnóstico por la imagen del tromboembolismo pulmonar mediante ecografía endobronquial

RESUMEN

La ecografía endobronquial (EBUS) es una nueva técnica que puede utilizarse para el diagnóstico por la imagen del tromboembolismo pulmonar (TEP) central. En 8 casos de nuestra clínica se utilizó la EBUS a causa de adenopatías mediastínicas o lesiones nodulares paramediastínicas, y al mismo tiempo se obtuvieron imágenes de un TEP mediante la EBUS. El TEP se diagnosticó antes de la EBUS mediante tomografía computarizada (TC) pulmonar en todos los casos (5 mujeres y 3 varones). Los defectos de repleción de todos los casos compatibles con un TEP se esclarecieron mediante angio-TC. La EBUS puede ser un método alternativo para el diagnóstico del TEP, ya que puede indicar la presencia de un trombo en arterias pulmonares centrales en casos en los que la hemodinámica es estable.

© 2012 SEPAR. Publicado por Elsevier España, S.L. Todos los derechos reservados.

Palabras clave:

Técnicas de diagnóstico por la imagen

Pulmonar

Tromboembolismo

Endobronquial

Ecografía

Introduction

Pulmonary thromboembolism (PE) is a medical disorder related with sudden occlusion of the pulmonary artery. It has a high mortality and morbidity rate. PE can be erroneously diagnosed in patients with comorbidities. The systematic use of multislice computed tomography (CT) angiography of the chest is the technique of choice for the diagnosis of PE. The use of contrast solutions and radiation

are its main limitations in cases of renal failure and in pregnancy.^{1,2} Therefore, other diagnostic tests are essential in these situations (Figs. 1 and 2).

Endobronchial ultrasound (EBUS) is a new diagnostic technique in pulmonary medicine. By using ultrasound on the tip of the bronchoscope, the tissue surrounding the respiratory system can be evaluated and invasive techniques applied. The main indications for EBUS are mediastinal lymphadenopathies and central masses. Its use enables both histopathological diagnosis of the mass (malignant disease, tuberculosis, sarcoidosis) and staging of malignant disease to be easily determined³ (Tables 1 and 2).

Some articles have recently been published on the use of EBUS as a diagnostic method for central PE.^{4–6} In this paper, we evaluated PE in eight patients using EBUS, and have assessed the importance of this technique in the diagnosis of PE.

[☆] Please cite this article as: Şentürk A, et al. Diagnóstico por la imagen del tromboembolismo pulmonar mediante ecografía endobronquial. Arch Bronconeumol. 2013;49:268–71.

^{*} Corresponding author.

E-mail address: asenturk1967@yahoo.com (A. Şentürk).

Table 1
Patient Characteristics.

	Age	Sex	CT scan results	Pulmonary arterial pressure, mmHg	Histopathological diagnosis
Case 1	37	F	<ul style="list-style-type: none"> • PE • 24 mm×16 mm paramediastinal solid nodular lesion in the left upper lobe 	40–45	Adenocarcinoma
Case 2	61	F	<ul style="list-style-type: none"> • PE • Mediastinal lymphadenopathies • Cardiomegaly 	50–55	No biopsy
Case 3	50	F	<ul style="list-style-type: none"> • PE • Mediastinal lymphadenopathies • Pleuritis 	–	Necrotizing granulomatous inflammation
Case 4	51	F	<ul style="list-style-type: none"> • PE • Mediastinal lymphadenopathies • 1 cm×2 cm solid nodular lesion in the right lung 	45	Necrotizing granulomatous inflammation
Case 5	82	M	<ul style="list-style-type: none"> • PE • Mediastinal+hilar lymphadenopathies • 13 mm solid nodular lesion in the left upper lobe 	40	Squamous metaplasia
Case 6	50	M	<ul style="list-style-type: none"> • PE • Mediastinal lymphadenopathies • Infarct in the right lower lobe 	35	Adenocarcinoma
Case 7	49	M	<ul style="list-style-type: none"> • PE • Mediastinal lymphadenopathies • Pleuritis • Axillary lymphadenopathies • Intra-abdominal lymphadenopathies 	–	Mucinous adenocarcinoma
Case 8	24	F	<ul style="list-style-type: none"> • PE • Mediastinal lymphadenopathies 	–	Lymphoma

Clinical Findings*Case 1*

A 37-year-old woman attended the emergency department with cough and hemoptysis. The chest computed tomography (CT) scan showed a 24 mm×16 mm solid nodular paramediastinal lesion in the left upper lobe, and the bilateral presence of a thrombus in the pulmonary arteries. Endobronchial ultrasound-guided fine needle aspiration (EBUS-FNA) was used to diagnose the solid nodular lesion, and a PE was observed in the bilateral central pulmonary arteries.

Case 2

A 61-year-old woman underwent surgery for a meniscal tear. After the operation, she suffered a massive pulmonary embolism and thrombolytic treatment was applied. Mediastinal lymph nodes were also observed on the chest CT scan. Six days after thrombolytic treatment, the patient was hemodynamically stable, and EBUS was used to examine the lymph nodes. Since the images of the lymph nodes had benign echographic characteristics, FNA was not performed. During the EBUS, the presence of bilateral pulmonary arterial thrombi was observed.

Table 2

Identification of Thrombi by CT Scan and by EBUS.

	Location of thrombi on the CT scan	Location of thrombi on the EBUS
Case 1	Bilateral central PA	Bilateral central PA
Case 2	Bilateral central PA	Bilateral central PA
Case 3	Left lower lobe artery	Left lower lobe artery
Case 4	Right upper lobe artery	Right upper lobe artery
Case 5	Left main PA	Left main PA
Case 6	Bilateral central PA	Bilateral central PA
Case 7	Bilateral central PA	Bilateral central PA
Case 8	Left main PA	Left main PA

PA: pulmonary artery.

Case 3

A 50-year-old woman attended the emergency department for sudden onset of dyspnea and fatigue. The chest CT scan revealed the presence of a thrombus in the left lower lobe artery, as well as 2 cm mediastinal, hilar and subcarinal lymph nodes. EBUS-FNA of the nodes was performed; during the EBUS, the thrombus was seen in the left lower lobe artery. Caseous necrosis was diagnosed in the histopathological examination.

Case 4

A 51-year-old woman attended hospital for dyspnea and chest pain. The chest CT scan revealed the presence of a 2 cm solid nodular lesion in the right lung, mediastinal lymphadenopathies and a PE in the right upper lobe artery. EBUS-FNA of the lesion and lymph nodes was performed; during the EBUS, the thrombus was seen in the right upper lobe artery. Necrotizing granulomatous inflammation was identified in the histopathological examination.

Case 5

An 82-year-old man attended hospital for dyspnea and chest pain. The chest CT scan revealed a 13 mm solid nodular lesion in the left upper lobe, together with mediastinal and hilar

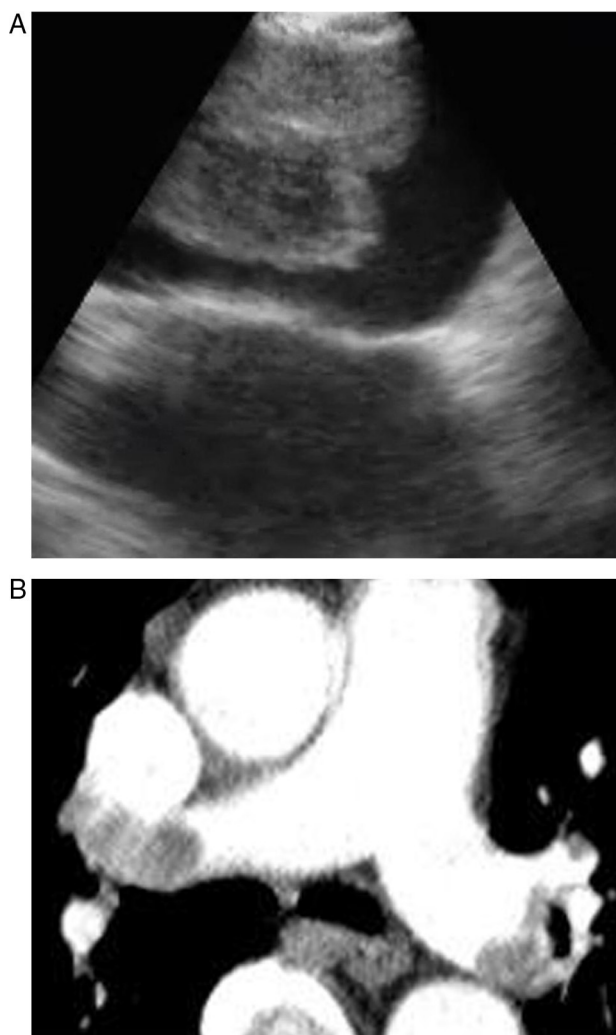

Figure 1. (A-B) Images of an embolism in the right pulmonary artery on the EBUS.

lymphadenopathies and a PE in the left main pulmonary artery. EBUS-FNA of the lesion and lymph nodes was performed; during the EBUS, the thrombus was seen in the left main pulmonary artery. Squamous metaplasia was observed in the histopathological examination.

Case 6

A 50-year-old male attended the emergency department for hemoptysis and chest pain. The chest CT scan revealed an infarct in the right lower lobe, together with mediastinal lymphadenopathies and a bilateral PE in the central pulmonary arteries. EBUS-FNA of the lymph nodes was performed; during the EBUS, a thrombus was seen in the bilateral central pulmonary arteries. The histopathological examination indicated the presence of an adenocarcinoma.

Case 7

A 49-year-old male attended the emergency department for hemoptysis, chest pain and neck swelling. The chest CT scan revealed mediastinal, axillary lymphadenopathies, minimal bilateral pleuritis and a PE in the bilateral central pulmonary arteries. EBUS-FNA of the lymph nodes was performed; during the EBUS, a thrombus was seen in the bilateral central pulmonary arteries. Mucinous adenocarcinoma was observed in the histopathological examination.

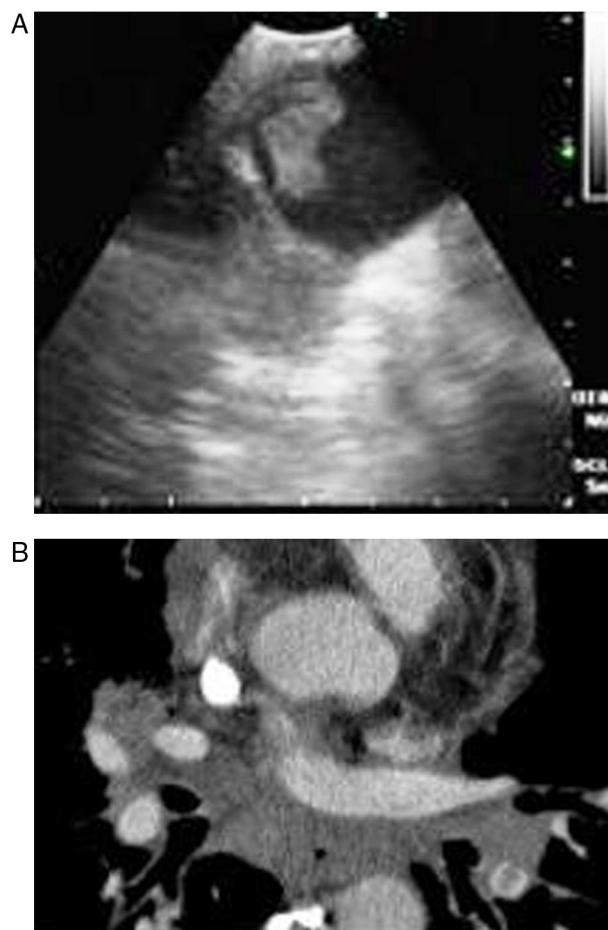


Figure 2. (A-B) Bilateral embolism in the central pulmonary artery in the chest CT scan.

Case 8

A 24-year-old woman attended hospital with a one-month history of cough and chest pain. Multiple lymph nodes and a thrombus in the superior vena cava were observed on the chest CT scan. EBUS-FNA was used for the diagnosis. During the EBUS examination, in addition to the thrombus in the superior vena cava, the presence of a thrombus in the right upper pulmonary artery was also observed. Histopathological examination of the lymph node biopsies indicated the presence of a B-cell lymphoma.

Discussion

PE is a common lung condition which is difficult to diagnose, and is the leading life-threatening pulmonary emergency. Patients with PE usually experience sudden pleuritic chest pain with breathing difficulties, but sometimes may have non-specific symptoms that can cause the diagnosis of PE to be delayed or indeed not established at all. This delay in diagnosis is the most significant factor in PE mortality. Thus, patients in whom PE is suspected must be evaluated and diagnosed quickly. There are no accurate non-invasive tests.^{1,2} Multislice CT angiography of the chest has recently emerged as the method of choice for the diagnosis of PE. The increased number of detectors enables peripheral thrombi to be easily visualised.⁷ However, the radiation dose increases with the number of detectors, examination area and thickness of the slice. Furthermore, an iodinated contrast solution, which is nephrotoxic, is required for the angiography. As a result, CT angiography is not an appropriate method in pregnant women, patients with renal

failure and patients allergic to contrast, so other diagnostic tests must be used to establish the presence of a PE. According to the PIOPED II study, CT angiography cannot be used in 24% of patients with PE due to contraindications.² Ventilation/perfusion (V/Q) scintigraphy is another diagnostic test used for PE. Radioactive solutions must also be used for this examination. V/Q scintigraphy is appropriate in patients in whom PE is suspected, and who have a normal chest X-ray and normal basic cardiopulmonary characteristics. If the chest X-ray is abnormal, the diagnostic value of the scintigraphy is reduced.⁸ Magnetic resonance imaging can also be used to visualize the thrombus in the pulmonary artery; movement artifacts, allergy to gadolinium and inapplicability in emergency situations are its main disadvantages.⁹ Approximately 70% of patients with PE have deep vein thrombosis (DVT). The diagnosis of DVT is important information for initiating anticoagulant treatment in patients in whom PE is suspected. However, discarding DVT does not discard the presence of a PE. There are no definitive diagnostic tests with minimal complications that can be applied in all cases. Consequently, many diagnostic tests must be used in combination.^{1,2}

EBUS is generally used for the biopsy of mediastinal and hilar lymphadenopathies or masses. The pulmonary arteries are around 5 mm in the tracheobronchial zone. Thus, EBUS can visualize them easily. We used a convex ultrasound probe (CP) (Olympus EBUS-CV-180, Tokyo, Japan) for the bronchoscopic evaluation. The external diameter of the CP-EBUS is 6.9 mm. It has a 2.0 mm working channel and a 30 degree oblique anterograde viewing optic. The maximum penetration of the linear ultrasound transducer is 50 mm, and it is connected to a processor that enables the flow of the mediastinal and hilar vessels to be visualised.¹⁰

Casoni et al. used the EBUS in a patient who presented a suspicious low density intra-arterial lesion on the pulmonary angiography, and for the first time published the diagnosis of a PE.⁴ Aumiller et al. incidentally diagnosed PEs in three patients during EBUS examinations to stage lung cancer. A multicenter study was later started to evaluate the presence of PE using CP-EBUS in the first 24 h following a diagnosis of PE by CT angiography. Thrombi were easily detected in the pulmonary arteries in 28 out of 32 patients. A total of 97 of the 101 thrombi diagnosed using CT angiography were confirmed with EBUS (96% sensitivity). EBUS enables the pulmonary trunk, main pulmonary arteries and lobar arteries to be visualized. One of the four thrombi that could not be visualized was in the middle lobe artery, and three were in the left upper lobe artery. None of the patients suffered any complications during the study. As a result, the authors reached the conclusion that EBUS was a feasible diagnostic tool for detecting central PE.⁵ Following this study, many cases were published describing the use of EBUS in the diagnosis of PE.^{6,11–13}

In our study, all patients were hemodynamically stable and were sedated during the bronchoscopy. EBUS was carried out using an oral approach, with conscious sedation in all patients. Arterial blood pressure, pulse rate and oxygen saturation were constantly recorded during all the procedures. The main pulmonary arteries were visualized after evaluating the mediastinal

lymphadenopathies in all cases. The bronchoscopist knew the location of the filling defects observed in the pulmonary arteries on the CT scan. Permeable pulmonary arteries did not show echoes. In our cases, when echogenic zones were visualized, the bronchoscopist confirmed the presence of the thrombus using the Doppler mode.

In conclusion, we evaluated PE using EBUS easily and reliably. PE guidelines do not refer to EBUS in relation to the diagnosis of PE. Since CT angiography cannot be applied in a significant number of patients, EBUS-guided imaging diagnosis of the thrombi could be a good alternative in hemodynamically stable patients for the diagnosis of PE. Furthermore, in intensive care units, transferring some patients to the CT unit is a major problem, so EBUS could be useful in these cases for diagnosing PE. Moreover, EBUS can visualize the central vasculature and enable vascular malignant diseases to be easily differentiated from PE. However, additional single-blind, randomized, controlled studies will be necessary, since in our study, as well as in the one by Aumiller et al., the bronchoscopists knew the location of the PE in the CT angiography.⁵

Conflict of Interest

The authors declare no conflict of interest.

References

1. Abunasser J, Tejada JP, Foley RJ. The diagnosis and management of pulmonary embolism. *Conn Med.* 2012;76:5–14.
2. Hunsaker AR, Lu MT, Goldhaber SZ, Rybicki FJ. Imaging in acute pulmonary embolism with special clinical scenarios. *Circ Cardiovasc Imaging.* 2010;3:491–500.
3. Sheski FD, Mathur PN. Endobronchial ultrasound. *Chest.* 2008;133:264–70.
4. Casoni GL, Gurioli C, Romagnoli M, Poletti V. Diagnosis of pulmonary thromboembolism with endobronchial ultrasound. *Eur Respir J.* 2008;32:1416–7.
5. Aumiller J, Herth FJ, Krasnik M, Eberhardt R. Endobronchial ultrasound for detecting central pulmonary emboli: a pilot study. *Respiration.* 2009;77:298–302.
6. Cetinkaya E, Yilmaz A, Özgül A, Onur S, Gençoğlu A, Altın S. A case of pulmonary embolism confirmed by endobronchial ultrasound. *Tuberk Toraks.* 2011;59:318–20.
7. Stein PD, Fowler SE, Goodman LR, Gottschalk A, Hales CA, Hull RD, et al. Multi-detector computed tomography for acute pulmonary embolism. *N Engl J Med.* 2006;354:2317–27.
8. Miniati M, Sostman HD, Gottschalk A, Monti S, Pistoletti M. Perfusion lung scintigraphy for the diagnosis of pulmonary embolism: a reappraisal and review of the prospective investigative study of acute pulmonary embolism diagnosis methods. *Semin Nucl Med.* 2008;38:450–61.
9. Hochegger B, Ley-Zaporozhan J, Marchiori E, Irion K, Souza Jr AS, Moreira J, et al. Magnetic resonance imaging findings in acute pulmonary embolism. *Br J Radiol.* 2011;84:282–7.
10. Herth FJ, Eberhardt R, Vilmann P, Krasnik M, Ernst A. Real-time endobronchial ultrasound guided transbronchial needle aspiration for sampling mediastinal lymph nodes. *Thorax.* 2006;61:795–8.
11. Egea CJ, Ribas FJ, Juste M. Pulmonary thromboembolism observed by endobronchial ultrasound (EBUS). *Arch Bronconeumol.* 2011;47:164–5.
12. Sanz-Santos J, Andreo F, García-Olivé I, Remón J, Monsó E. Diagnosis of acute pulmonary embolism by endobronchial ultrasound as an incidental finding. *Respiration.* 2011;81:150–1.
13. Blanc AL, Jardin C, Faivre JB, Le Rouzic O, Do Cao C, Benhamed L, et al. Pulmonary artery tumour-embolism diagnosed by endobronchial ultrasound-guided transbronchial needle aspiration. *Eur Respir J.* 2011;38:477–9.