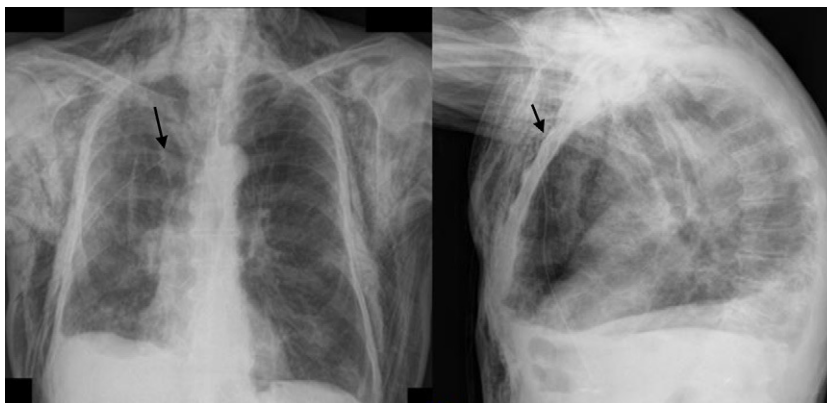



**Fig. 2.** Posteroanterior and lateral chest radiography showing massive accumulation of air in the subcutaneous tissue. The proximal end of the subcutaneous drain can be observed in the third right intercostal space (arrows).

and *pulsus paradoxus*. Hamman's sign only appears in 12% of cases.<sup>2</sup> Diagnosis is confirmed on chest radiograph by the presence of air separating mediastinal structures or surrounding them and subcutaneous emphysema, while less frequent signs may also be identified, such as the spinnaker-sail sign, pneumopericardium, etc.<sup>3</sup> The differential diagnosis includes acute coronary syndrome, pericarditis, pneumothorax, pulmonary thromboembolism, rupture of the tracheobronchial tree and Boerhaave syndrome. In most cases, there is complete resolution of the symptoms within 4 days. Nevertheless, there are cases that may involve compression of pulmonary or mediastinal veins, which simulates cardiac tamponade. These cases, which Macklin calls "malignant pneumomediastinum",<sup>4</sup> require fast action that should be directed at immediately evacuating the air accumulated in the mediastinum. Massive accumulation of air in the subcutaneous tissue can also compromise the life of the patient due to pneumatic compression of the thorax, causing progressive hypoxemia and hypercapnia. The use of subcutaneous drains can be very useful in these cases; they are effective almost immediately and can be withdrawn in a few days. In selecting the type of drain, one must take into account their availability and the training of the staff for their insertion. Another important factor is the characteristics of each type of catheter, as smaller-caliber tubes are more comfortable but entail a greater risk of obstruction, and wider tubes are permeable for a longer period of time but can cause patient discomfort.<sup>5</sup>

## References

- Romero KJ, Trujillo MH. Spontaneous pneumomediastinum and subcutaneous emphysema in asthma exacerbation: the Macklin effect. *Heart Lung*. 2010;39:444–7.
- Hamman L. Spontaneous mediastinal emphysema. *Bull Johns Hopkins Hospital*. 1939;64:1–21.
- Zylak CM, Standen JR, Barnes GR, Zylak CJ. Pneumomediastinum revisited. *Radiographics*. 2000;20:1043–57.
- Macklin MT, Macklin CC. Malignant interstitial emphysema of the lungs and mediastinum as an important occult complication in many respiratory diseases and other conditions: an interpretation of the clinical literature the light of laboratory experiment. *Medicine (Baltimore)*. 1944;23:281–358.
- Sucena M, Coelho F, Almeida T, Gouveia A, Hespanhol V. Enfisema subcutáneo maçivo. Tratamento con drenos subcutáneos. *Rev Portuguesa Pneumol*. 2010;16:321–9.

Mariluz Santalla Martínez,<sup>a,\*</sup> Raquel Dacal Quintas,<sup>b</sup>  
Pedro Marcos Velázquez<sup>b</sup>

<sup>a</sup> *Servicio de Neumología, Hospital Comarcal de Monforte de Lemos, Lugo, Spain*

<sup>b</sup> *Servicio de Neumología, Complejo Hospitalario Universitario de Ourense, Ourense, Spain*

\* Corresponding author.

E-mail address: [marussantalla@gmail.com](mailto:marussantalla@gmail.com) (M. Santalla Martínez).

## Infections by Gram-Negative Bacilli in Patients With Pulmonary Arterial Hypertension Treated With Intravenous Prostacyclin<sup>☆</sup>

### *Infecciones por gramnegativos en pacientes con hipertensión arterial pulmonar tratados con prostacilinas intravenosas*

Dear Editor,

I have read with great interest the original article by López Medrano et al.<sup>1</sup> regarding the high incidence of bacteremia due to Gram-negative bacteria (GNB) in patients with pulmonary arterial hypertension (PAH) treated with intravenous (IV) treprostinil compared with IV epoprostenol. This is a known finding in

the literature and has been confirmed in a Spanish center with extensive experience in the management of PAH. They also suggest initial empirical therapeutic management until the pathogen is correctly identified. In their conclusions, the authors invite us to carefully weigh the risks and benefits of treatment with IV treprostinil.

Recently, Kitterman et al.<sup>2</sup> have published data about the incidence of bloodstream infection in 1146 patients with PAH from the REVEAL Registry in the United States. They had been treated with either IV epoprostenol or treprostinil, and a greater incidence of infection due to GNB was found in the IV treprostinil group (0.20 vs 0.03 per 1000 days of treatment,  $P < .001$ ). However, this US series shows that the rate of infection has dropped drastically in recent years since the publication and approval of the Clinical Practice Guidelines for the prevention of bacteremia due to central venous catheter in the treatment of PAH with prostanoids.<sup>3</sup> Our own center had also experienced a reduction in the rates of infection in recent years since guidelines were adopted,

<sup>☆</sup> Please cite this article as: Gómez Sánchez MA. Infecciones por gramnegativos en pacientes con hipertensión arterial pulmonar tratados con prostacilinas intravenosas. *Arch Bronconeumol*. 2013;49:128–9.

but this analysis is not reflected in the paper by López Medrano et al.<sup>1</sup>

In other studies aimed at reducing these infections, the use of a high-pH diluent (like epoprostenol) and additional measures for venous catheter care have been shown to be effective.<sup>4–6</sup> The design of the Kitterman et al. study cannot discern between the superiority of one or another measure to reduce the number of bloodstream infections. Given that in Europe it is not possible to prepare treprostinil with a high-pH solvent, patients must be educated to avoid infections through simple but effective techniques such as strict compliance with proper hygiene, placement of the bacterial filter not in the perfusion line, the introduction of a closed connector (closed-hub system) and, above all, maintaining central venous catheter connections clean and dry at all times.

Finally, as for the conclusions of López Medrano et al.,<sup>1</sup> the decision to use one or another form of IV prostacyclin is based on the results of an observational, non-controlled study with a small sample population, with no reference to the changes in practice that may have taken place from the introduction of local standards for catheter care, as previously indicated. A more extensive, controlled study designed to this effect is necessary, as it has been suggested by Clinical Practice Guidelines with regards to recommendations and level of evidence.

Improved treatment management with parenteral prostacyclin is one of the current challenges that could have repercussions on the morbidity, mortality and general quality of life of patients with PAH.

## References

1. López-Medrano F, Fernandez Ruiz M, Ruiz Cano MJ, Barrios E, Vicente-Hernandez M, Aguado JM, et al. Alta incidencia de bacteriemia por bacilos gramnegativos en pacientes con hipertensión pulmonar tratados con treprostinil por vía intravenosa. Arch Bronconeumol. 2012; <http://dx.doi.org/10.1016/j.arbres.2012.06.005>. Epub ahead print.
2. Kitterman N, Poms A, Miller DP, Lombardi S, Farber HW, Barst RJ. Bloodstream infections in patients with pulmonary arterial hypertension treated with intravenous prostanoids: insights from the REVEAL REGISTRY®. Mayo Clin Proc. 2012;87:825–34.
3. Doran AK, Ivy DD, Barst RJ, Hill N, Murali S, Benza RL, Scientific Leadership Council of the Pulmonary Hypertension Association. Guidelines for the prevention of central venous catheter-related blood stream infections with prostanoid therapy for pulmonary arterial hypertension. Int J Clin Pract Suppl. 2008;160:5–9.
4. Rich JD, Glassner C, Wade M, Coslet S, Arneson C, Doran A, et al. The effect of diluent pH on bloodstream infection rates in patients receiving IV treprostinil for pulmonary arterial hypertension. Chest. 2012;141:36–42.
5. Ivy DD, Calderbank M, Wagner BD, Dolan S, Nyquist AC, Wade M, et al. Closed-hub systems with protected connections and the reduction of risk of catheter-related bloodstream infection in pediatric patients receiving intravenous prostanoid therapy for pulmonary hypertension. Infect Control Hosp Epidemiol. 2009;30:823–9.
6. Akagi S, Matsubara H, Ogawa A, Kawai Y, Hisamatsu K, Miyaki K, et al. Prevention of catheter-related infections using a closed hub system in patients with pulmonary arterial hypertension. Circ J. 2007;71:559–64.

Miguel Angel Gómez Sánchez

Unidad de Insuficiencia Cardíaca, Trasplante e Hipertensión Pulmonar, Servicio de Cardiología, Hospital Universitario 12 de Octubre, Madrid, Spain

E-mail address: [mgomez.s.hdoc@salud.madrid.org](mailto:mgomez.s.hdoc@salud.madrid.org)

## Pulmonary Sequestration<sup>☆</sup>

### Secuestro pulmonar

Dear Editor,

A pulmonary sequestration is a lung tissue mass that is not connected with the central respiratory tract that receives its arterial blood supply from the systemic circulation.

We present the case of a 76-year-old woman, reporting with no personal history of interest, with an incidental finding of a left retrocardiac mass during a routine pre-operative workup. The study was extended to include computed tomography (CT) with intravenous contrast, which revealed a well-outlined soft tissue mass in the postero-inferior region of the left hemithorax (Fig. 1A) that was supplied with arterial blood from the descending thoracic aorta (Fig. 1B) and drained into the left hemiazygos vein (Fig. 1C and D).

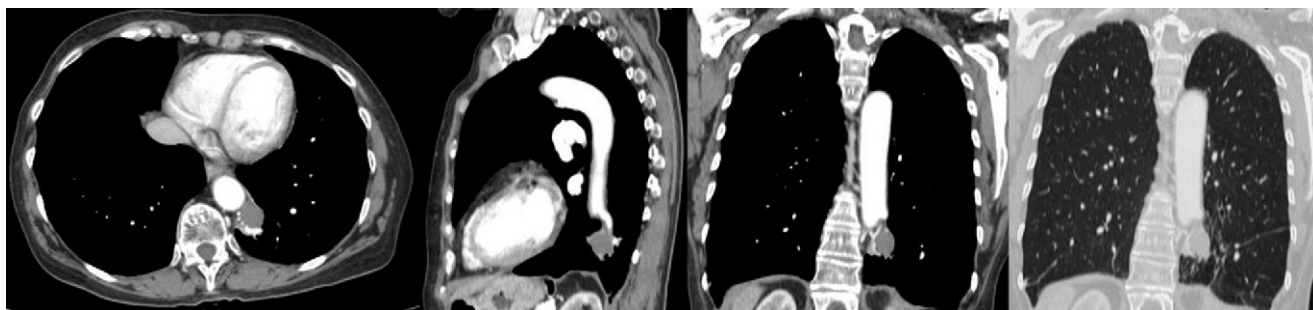


Fig. 1. Computed tomography study with intravenous contrast.

Pulmonary sequestrations are divided into two types: intralobar and extralobar. Intralobar sequestrations are acquired lesions, possibly resulting from chronic bronchial obstruction or pneumonia. 98% occur in the lower lobes and they are characterized by not having their own pleura.<sup>1</sup> The arterial irrigation comes from an artery of the systemic circulation system, while the venous drainage is through the pulmonary circulation. The highest incidence of intralobar sequestration is found in young adults, and symptoms usually include repeated infections.

Extralobar sequestrations are congenital lesions that are mostly detected in children, although they may also be detected during the prenatal period using ultrasound.<sup>2,3</sup> 60% are located in the left hemithorax and they are characterized by having their own pleura. Arterial blood is supplied by the systemic circulation, while the venous return is what differs from intralobar sequestration as it is done through the general circulation. Extralobar sequestrations are usually asymptomatic, although they are frequently associated with other congenital

<sup>☆</sup> Please cite this article as: Mayoral-Campos V, et al. Secuestro pulmonar. Arch Bronconeumol. 2013;49:129-30.