

4. Woywodt A, Matteson EL. Wegener's granulomatosis—probing the untold past of the man behind the eponym. *Rheumatology (Oxford)*. 2006;45:1303–6.
5. Rosen MJ, Irwin R. Dr. Friedrich Wegener and the ACCP, Revisited. *Chest*. 2007;132:1723–4.
6. Falk RJ, Jennette C. ANCA disease: where is this field heading? *J Am Soc Nephrol*. 2010;21:745–52.
7. NSDAP membership card of Dr. Max Clara, 1935. Archive: Bundesarchiv, Berlin. Signature: BArch (former BDC), NSDAP-Zentralkartei.
8. Clara M. Zur Histobiologie des Bronchalepithels [On the histobiology of the bronchial epithelium]. *Z mikrosk anat Forsch*. 1937;41:321–47.
9. Woywodt A, Lefrak S, Matteson E. Tainted eponyms in medicine: the “Clara” cell joins the list. *Eur Respir J*. 2010;36:706–8.
10. Winkelmann Y, Noack T. The Clara cell: a “Third Reich eponym”? *Eur Respir J*. 2010;36:722–7.
11. Müller R. Untersuchungen über das Vorkommen von Vitamin C im Hoden des Menschen [Investigations of the occurrence of vitamin C in the human testis]. *Z mikr anat Forsch*. 1942;52:440–54.
12. Hildebrandt S. Anatomy in the Third Reich: an outline. Part 1. National socialist politics, anatomical institutions, and anatomists. *Clin Anat*. 2009;22: 883–93.
13. Rosner I. Reiter's syndrome versus reactive arthritis: Nazi-phobia or professional concerns? *Isr Med Assoc J*. 2008;10:296–7.
14. Woywodt A, Matteson E. Should eponyms be abandoned? Yes. *BMJ*. 2007;335:424.

Joaquim Gea,^{a,b,c,*} Mauricio Orozco-Levi,^{b,c,d} Rafel Aguiló^a

^a *Servicios de Neumología y Cirugía Torácica, Hospital del Mar, Instituto de Investigación del Hospital del Mar (IMIM), Barcelona, Spain*

^b *Departamento de Ciencias Experimentales y de la Salud, Universidad Pompeu Fabra, Barcelona, Spain*

^c *Centro de Investigación Biomédica en Red de Enfermedades Respiratorias, Instituto de Salud Carlos III, Bunyola, Mallorca, Spain*

^d *Servicio de Medicina Respiratoria, Fundación Cardiovascular de Colombia, Bucaramanga, Colombia*

* Corresponding author.

E-mail address: jgea@parcdesalutmar.cat (J. Gea).

Treatment With Subcutaneous Drainage in the Pneumomediastinum and Massive Subcutaneous Emphysema^{*}

Tratamiento con drenajes subcutáneos en el neumomediastino y enfisema subcutáneo masivo

Dear Editor,

Pneumomediastinum (PM) and subcutaneous emphysema (SE) are generally benign entities with a self-limiting course. There is a potential risk for complications due to massive accumulation of air that could compromise the life of the patient by interfering with respiratory mechanics and complicating venous return. In these cases, a less aggressive and effective therapeutic option is the use of subcutaneous drains. We present the case of a 75-year-old male with PM and massive SE that was resolved with this type of drains.

A 75-year-old male with GOLD grade IV COPD, who had undergone upper right lobectomy for pulmonary epidermoid carcinoma, came to our emergency room due to COPD exacerbation. The patient was admitted to hospital and evolved favorably during the first 72 h. On the fourth day of hospitalization, after the exertion of defecating, he presented dyspnea and left pleuritic chest pain. Upon examination, subcutaneous emphysema was found in the apical region of the left hemithorax. Chest radiography confirmed the presence of air in the subcutaneous tissue. The patient was treated with rest, oxygen therapy and analgesia, but the subcutaneous emphysema extended throughout the thorax, face, eyelids and abdomen. Thoracic CT showed the presence of PM and massive SE with no evidence of pneumothorax, pulmonary emphysema and post-surgical absence of the left upper pulmonary lobe (Fig. 1). After 48 h, the patient presented symptoms of thoracic discomfort, sweating and presyncope, and electrocardiogram demonstrated paroxysmal atrial fibrillation. In this situation, it was decided to insert a right subcutaneous drain (Fig. 2). The patient's symptoms improved almost immediately, and the drain was able to be withdrawn 5 days later. Over the following 6 months, the patient presented no relapse.

^{*} Please cite this article as: Santalla Martínez M, et al. Tratamiento con drenajes subcutáneos en el neumomediastino y enfisema subcutáneo masivo. *Arch Bronconeumol*. 2013;49:127–8.

PM and SE are usually caused by a iatrogenic or traumatic trigger, although on occasion they may be secondary to an abrupt increase in intra-alveolar pressure, which is a phenomenon known as the Macklin effect.¹ The incidence of PM is low although underdiagnosed because its symptoms are non-specific and the radiological signs are difficult to identify. Typical symptoms at onset include chest pain, dyspnea and subcutaneous emphysema, and occasionally cervical pain, odynophagia, dysphagia, dysphonia

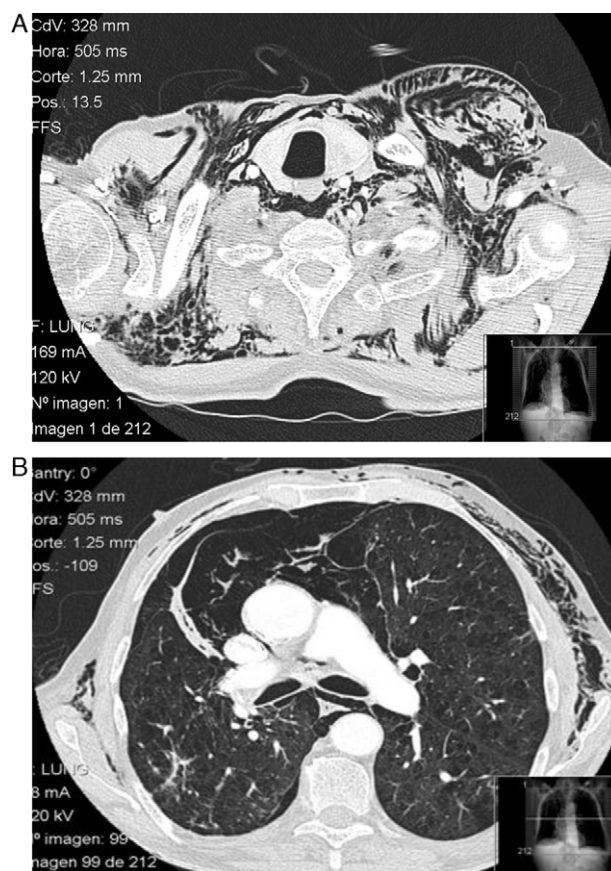


Fig. 1. (A and B) Thoracic CT image showing the presence of gas in the subcutaneous and mediastinal tissue.

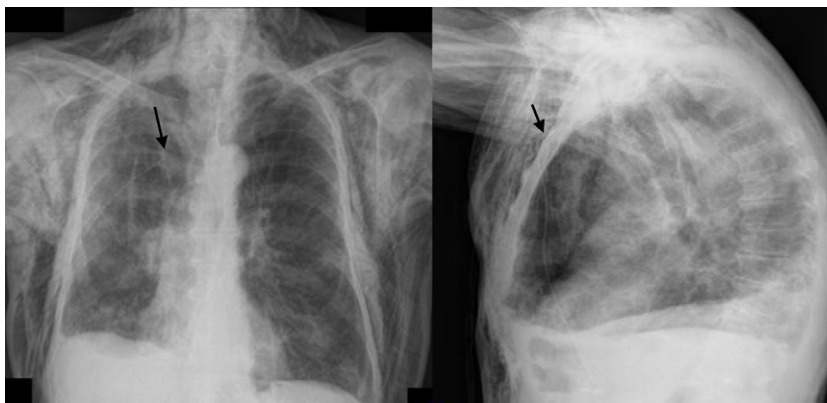

Fig. 2. Posteroanterior and lateral chest radiography showing massive accumulation of air in the subcutaneous tissue. The proximal end of the subcutaneous drain can be observed in the third right intercostal space (arrows).

and *pulsus paradoxus*. Hamman's sign only appears in 12% of cases.² Diagnosis is confirmed on chest radiograph by the presence of air separating mediastinal structures or surrounding them and subcutaneous emphysema, while less frequent signs may also be identified, such as the spinnaker-sail sign, pneumopericardium, etc.³ The differential diagnosis includes acute coronary syndrome, pericarditis, pneumothorax, pulmonary thromboembolism, rupture of the tracheobronchial tree and Boerhaave syndrome. In most cases, there is complete resolution of the symptoms within 4 days. Nevertheless, there are cases that may involve compression of pulmonary or mediastinal veins, which simulates cardiac tamponade. These cases, which Macklin calls "malignant pneumomediastinum",⁴ require fast action that should be directed at immediately evacuating the air accumulated in the mediastinum. Massive accumulation of air in the subcutaneous tissue can also compromise the life of the patient due to pneumatic compression of the thorax, causing progressive hypoxemia and hypercapnia. The use of subcutaneous drains can be very useful in these cases; they are effective almost immediately and can be withdrawn in a few days. In selecting the type of drain, one must take into account their availability and the training of the staff for their insertion. Another important factor is the characteristics of each type of catheter, as smaller-caliber tubes are more comfortable but entail a greater risk of obstruction, and wider tubes are permeable for a longer period of time but can cause patient discomfort.⁵

References

- Romero KJ, Trujillo MH. Spontaneous pneumomediastinum and subcutaneous emphysema in asthma exacerbation: the Macklin effect. *Heart Lung*. 2010;39:444–7.
- Hamman L. Spontaneous mediastinal emphysema. *Bull Johns Hopkins Hospital*. 1939;64:1–21.
- Zylak CM, Standen JR, Barnes GR, Zylak CJ. Pneumomediastinum revisited. *Radiographics*. 2000;20:1043–57.
- Macklin MT, Macklin CC. Malignant interstitial emphysema of the lungs and mediastinum as an important occult complication in many respiratory diseases and other conditions: an interpretation of the clinical literature the light of laboratory experiment. *Medicine (Baltimore)*. 1944;23:281–358.
- Sucena M, Coelho F, Almeida T, Gouveia A, Hespanhol V. Enfisema subcutáneo maçivo. Tratamento con drenos subcutáneos. *Rev Portuguesa Pneumol*. 2010;16:321–9.

Mariluz Santalla Martínez,^{a,*} Raquel Dacal Quintas,^b
Pedro Marcos Velázquez^b

^a *Servicio de Neumología, Hospital Comarcal de Monforte de Lemos, Lugo, Spain*

^b *Servicio de Neumología, Complejo Hospitalario Universitario de Ourense, Ourense, Spain*

* Corresponding author.

E-mail address: marussantalla@gmail.com (M. Santalla Martínez).

Infections by Gram-Negative Bacilli in Patients With Pulmonary Arterial Hypertension Treated With Intravenous Prostacyclin[☆]

Infecciones por gramnegativos en pacientes con hipertensión arterial pulmonar tratados con prostacilinas intravenosas

Dear Editor,

I have read with great interest the original article by López Medrano et al.¹ regarding the high incidence of bacteremia due to Gram-negative bacteria (GNB) in patients with pulmonary arterial hypertension (PAH) treated with intravenous (IV) treprostinil compared with IV epoprostenol. This is a known finding in

the literature and has been confirmed in a Spanish center with extensive experience in the management of PAH. They also suggest initial empirical therapeutic management until the pathogen is correctly identified. In their conclusions, the authors invite us to carefully weigh the risks and benefits of treatment with IV treprostinil.

Recently, Kitterman et al.² have published data about the incidence of bloodstream infection in 1146 patients with PAH from the REVEAL Registry in the United States. They had been treated with either IV epoprostenol or treprostinil, and a greater incidence of infection due to GNB was found in the IV treprostinil group (0.20 vs 0.03 per 1000 days of treatment, $P<.001$). However, this US series shows that the rate of infection has dropped drastically in recent years since the publication and approval of the Clinical Practice Guidelines for the prevention of bacteremia due to central venous catheter in the treatment of PAH with prostanoids.³ Our own center had also experienced a reduction in the rates of infection in recent years since guidelines were adopted,

[☆] Please cite this article as: Gómez Sánchez MA. Infecciones por gramnegativos en pacientes con hipertensión arterial pulmonar tratados con prostacilinas intravenosas. *Arch Bronconeumol*. 2013;49:128–9.