

primary bone tumor or metastasis, but it should be suspected when the pain is continuous, even at rest, and there is no improvement with analgesic therapy. When given pain with these characteristics, simple radiography should be taken of the affected region, as it is a test that provides much information. At middle age, and mainly over the age of 60, the differential diagnosis initially includes a metastatic origin, and then a primary tumor such as giant-cell tumor or osteosarcoma. Among the lung tumor types, non-small-cell lung cancer most frequently presents bone metastasis, most of which (66%) are detected at the time of the initial diagnosis.² When these lesions are metastatic, their management varies depending on possibilities for survival. Even though the prognosis is very poor, surgery of the area, especially if the hip is involved, provides the patient with much better mobility and a high quality of life. The best surgical option is complete resection of the metastasis, especially when it is a single metastasis, and substitution of the bone defect by implanting a megaprosthesis. The components are generally cemented for fast bone incorporation and to be able to rapidly make the patient mobile.^{3,4}

Funding

The authors declare having received no source of funding.

Conflict of Interests

The authors declare having no conflict of interests regarding this paper.

References

1. Clarke HD, Damron TA, Sim FH. Head and neck replacement endoprotheses for pathologic proximal femoral lesion. *Clin Orthop*. 1998;353:210–7.
2. Al Husaini H, Wheatley P, Clemons M, Frances A. Prevention and management of bone metastases in lung cancer: a review. *J Thorac Oncol*. 2009;4:251–9.
3. Mankin HJ, Francis J. Total femur replacement procedures in tumor treatment. *Clin Orthop*. 2005;438:60–4.
4. Shinichiro N, Katsuyuki K. More than 10 years of follow-up of two patients after total femur replacement for malignant bone tumor. *Int Orthop*. 2000;24:176–8.

Jose Pablo Puertas García-Sandoval, Antonio Valcárcel Díaz,*
Jose Andrés Calatayud Mora

Unidad de Tumores, Servicio de Cirugía Ortopédica y Traumatología, Hospital Universitario Virgen de la Arrixaca, El Palmar, Murcia, Spain

* Corresponding author.

E-mail address: AVD1981@HOTMAIL.COM (A. Valcárcel Díaz).

Thyroid Cyst Diagnosed by Endobronchial Ultrasound-guided Transbronchial Needle Aspiration in a Patient With Lung Cancer[☆]

Diagnóstico de quiste tiroideo mediante ultrasonografía endobronquial sectorial con punción-aspiración en un paciente con cáncer de pulmón

Dear Editor,

We present the case of a 69-year-old patient, ex-smoker, diabetic and dyslipidemic, who was referred from another center with the diagnosis of pulmonary adenocarcinoma obtained with bronchoscopy that demonstrated a tumor in the orifice of the anterior segmental bronchus of the right upper lobe. Positron-emission tomography CT (PET-CT) confirmed a paramediastinal mass with increased uptake (SUVmax. 15 g/ml) in the RUL compatible with a malignant tumor, right lower paratracheal lymphadenopathy with a fatty center with no FDG uptake and a right upper paratracheal lesion measuring 8 mm, which was discretely hypermetabolic (Fig. 1A and B) and interpreted as a lymphadenopathy. Given these findings, the mass was staged as T3NxM0. As the patient was a candidate for radical surgical treatment, it was considered necessary to obtain samples in order to rule out N2 affectation.

Sectorial endobronchial ultrasound (Olympus BF-UC 180F, Olympus, Tokyo, Japan) revealed a right lower paratracheal lymphadenopathy measuring 13 mm × 10 mm with a fatty center (Fig. 1C) that was aspirated and resulted negative for malignant cells; in addition, there was a hypoechoic nodule in the upper right paratracheal region (practically subglottic), measuring 8 mm × 7 mm (Fig. 1D), which Doppler ruled out as a possible blood

vessel. The ultrasound characteristics of said lesion were suggestive of a cyst, and needle aspiration obtained a liquid that the pathological analysis demonstrated to have follicular cells in plaques and groups, abundant macrophages and hemosiderophages on a background of colloid material, all of which were compatible with a thyroid cyst.

The existence of false positives from PET-CT in the mediastinal staging of lung cancer requires cytohistologic confirmation based on minimally invasive techniques such as ultrasound bronchoscopy. In this direction, recently published studies report a negative predictive value of PET-CT of 95%.¹

Most thyroid nodules detected in patients with pulmonary neoplasm are usually benign lesions. Nonetheless, thyroid metastases in lung cancer have been described by some authors.² It is for this reason that cytological confirmation is essential when given a patient with malignant lung disease.

Thyroid cysts are nodules with liquid content, located in the thyroid and differentiated from the rest of the parenchyma. Some papers have been published about the clinical implications and recommended management in neoplastic patients in whom uptake is detected by PET in the thyroid. The prevalence of this finding ranges between 1.2% and 4.3% of cases. The risk for malignancy of these lesions can reach 33%, corresponding with thyroid carcinomas (medullar or papillary), and in no case was it a metastasis of a primary neoplasm. In addition, the value of the SUVmax is not useful in order to differentiate between the benign or malignant nature of these lesions; therefore, cytohistologic confirmation is highly recommended.^{3,4}

After reviewing the literature to date, we have only identified one single case published in a patient with small-cell lung cancer.⁵

We would like to emphasize the importance of confirming positive PET-CT findings in the mediastinum in patients with lung cancer, as well as the usefulness of sectorial endobronchial ultrasonography for the identification and complication-free needle-aspiration of thyroid cysts.

[☆] Please cite this article as: Sánchez-Font A, et al. Diagnóstico de quiste tiroideo mediante ultrasonografía endobronquial sectorial con punción-aspiración en un paciente con cáncer de pulmón. *Arch Bronconeumol*. 2012;49:38–9.

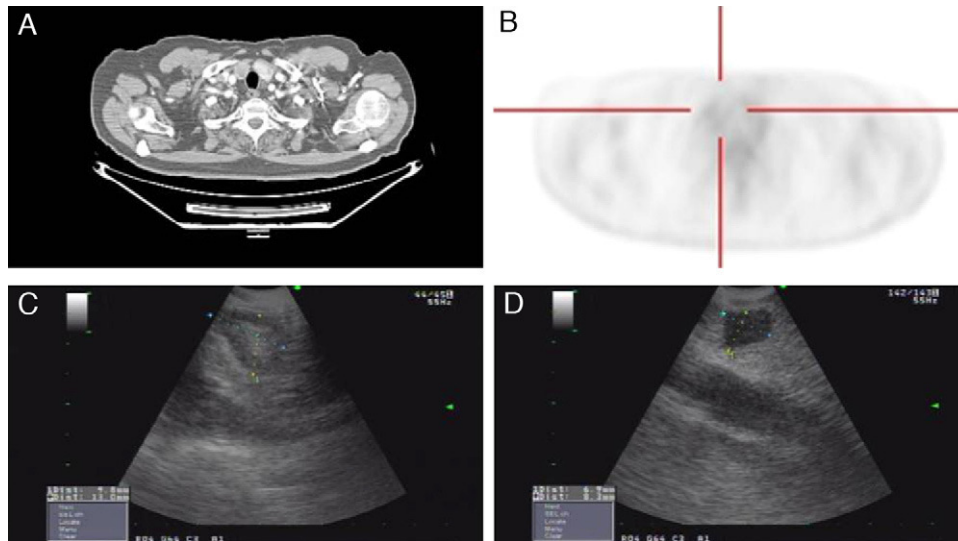


Fig. 1. (A) Axial chest CT slice in the mediastinal window showing an upper right paratracheal nodule. (B) The cross-sectional PET-CT slice shows evidence of a right upper paratracheal lesion that is discretely hypermetabolic. (C) Ultrasound image of the lower right paratracheal lymphadenopathy, measuring 13 mm × 10 mm, with a fatty center. (D) Subglottic hypoechoic nodular image, measuring 8 mm × 7 mm, corresponding with a thyroid cyst.

References

- Darling GE, Maziak DE, Inculet RI, Gulenchyn KY, Driedger AA, Ung YC, et al. Positron emission tomography-computed tomography compared with invasive mediastinal staging in non-small cell lung cancer: results of mediastinal staging in the early lung positron emission tomography trial. *J Thorac Oncol.* 2011;6:1367–72.
- Aron M, Kapila K, Verma K. Role of fine-needle aspiration cytology in the diagnosis of secondary tumors of the thyroid—twenty years' experience. *Diagn Cytopathol.* 2006;34:240–5.
- Wong C, Lin M, Chicco A, Benson R. The clinical significance and management of incidental focal FDG uptake in the thyroid gland on positron emission tomography/computed tomography (PET/CT) in patients with non-thyroidal malignancy. *Acta Radiol.* 2011;52:899–904.
- Ho TY, Liou MJ, Lin KY, Yen TC. Prevalence and significance of thyroid uptake by F-FDG PET. *Endocrine.* 2011;40:303.
- Steinfort DP, Irving LB. Endobronchial ultrasound staging of thyroid lesion in small cell lung carcinoma. *Thorac Cardiovasc Surg.* 2010;58:128–9.

Albert Sánchez-Font,^{a,*} Sergio Peralta,^b Víctor Curull^a

^a Servei de Pneumologia, Hospital del Mar-IMIM (Parc de Salut Mar), CIBERES (ISC III), Universitat Autònoma de Barcelona, Universitat Pompeu Fabra, Barcelona, Spain

^b Servei d'Oncologia Mèdica, Hospital Universitari Sant Joan de Reus, Universitat Rovira i Virgili, Reus, Tarragona, Spain

* Corresponding author.

E-mail address: ASanchezF@parcdesalutmar.cat
(A. Sánchez-Font).