

## Letters to the Editor

**Pleural Mesothelioma Secondary to Radiotherapy: A Rare Association<sup>☆</sup>****Mesotelioma pleural secundario a radioterapia: una asociación infrecuente**

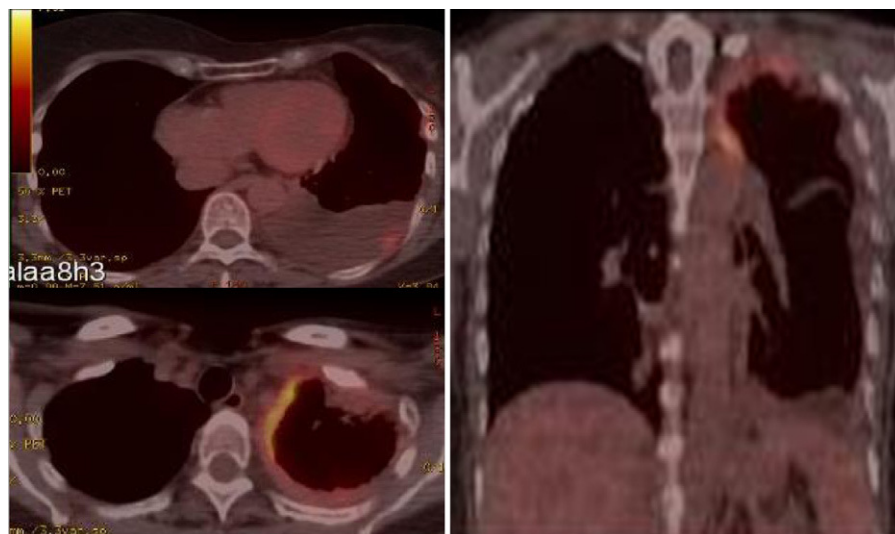
Dear Editor,

Pleural mesothelioma is a rare malignant tumor associated with exposure to asbestos in more than 70% of cases, although it has also been reported to be related with the SV40 virus, genetic alterations and exposure to radiotherapy, fundamentally for oncologic treatments.<sup>1</sup>

We present the case of a 60-year-old woman who was referred to our pleural pathology outpatient unit due to left pleural effusion. She reported having left-side chest pain with pleuritic characteristics that had been evolving over the course of 8 weeks, with dry cough and general deterioration. Physical exploration included lung auscultation characterized by left basal hypophonesis. The patient had no history of smoking, is a housewife and neither she nor her family members had any type of toxic environmental or occupational exposure, and specifically had no exposure to asbestos. Likewise, her residence was not located near any industries related with asbestos or any other possible asbestos sources. Ten years earlier, she had been treated for infiltrating ductal carcinoma of the breast by means of mastectomy, chemotherapy and radiotherapy. Analyses revealed: ESR 90 mm/h, CRP 42.9 mg/l,

fibrinogen 656 mg/dl and CA 15.3 44.1 U/ml. Tuberculin prick test was negative. After diagnostic thoracentesis, the liquid met characteristics for lymphocytic exudate, with an ADA of 21 IU/l and negative cytology for malignancy. Pleural biopsy with an Abrams needle guided by thoracic ultrasound obtained fragments of pleural and musculoskeletal tissue with no pathologic alterations. Positron emission tomography/computed tomography (PET/CT) showed hyper-uptake in the left apical pleura and in the left basal subpleural area with maximum SUV of 6.8 and 3.8 g/ml, respectively (Fig. 1). Given the lack of diagnosis, we performed a CT-guided transthoracic fine-needle aspiration in the area of greatest hyper-uptake on the PET/CT, and cytology showed evidence of the presence of atypical mesothelial proliferation. The final anatomical pathology diagnosis was obtained by pleural biopsy from video-assisted thoracoscopy after having obtained a fragment of tissue compatible with epithelial-type pleural malignant mesothelioma.

Oncologic treatments increase the survival of cancer patients. These individuals have twice as much risk of developing a second tumor at some time in their lives due to factors such as genetic predisposition, exposure to carcinogenic factors like tobacco smoke and oncologic treatments based on radiotherapy and chemotherapy. The relationship between exposure to radiotherapy and pleural mesothelioma has been documented in the literature in cases or series of clinical cases. They have been reported after receiving radiotherapy as treatment of Hodgkin's disease, followed by Wilms' tumor and lung, ovarian and breast cancer, as in the case that we have described.<sup>2</sup>



**Fig. 1.** PET/CT fusion imaging demonstrating 2 foci of pathologic hypermetabolism in the left pleural apical area (SUV 6.8 g/ml) and in the left basal subpleural region (SUV 3.8 g/ml).

<sup>☆</sup> Please cite this article as: Lourido-Cebreiro T, et al. Mesotelioma pleural secundario a radioterapia: una asociación infrecuente. Arch Bronconeumol. 2012;48:482–3.

There are differences in the latency for developing mesothelioma after exposure to radiotherapy as well as in the age of presentation compared with asbestos-related mesothelioma. After a review of the published literature,<sup>2-4</sup> we have identified 6 cases reporting malignant pleural mesothelioma induced by radiotherapy used for the treatment of breast cancer. The time interval between the radiation and the appearance of the mesothelioma ranged between 10 and 30 years, and the mean age at presentation of the mesothelioma was 55. In asbestos-related mesotheliomas, there is a greater time interval between the exposure and the appearance of the tumor (usually 30-40 years) and patients also present older ages.

The diagnosis is difficult, especially in cases with no history of exposure to asbestos and due to the need for a large tissue sample for the anatomic pathology study. Although pleural cytology or cytological puncture can guide the diagnosis, a technique is required to provide a biopsy fragment of optimal size. Thus, thoracoscopy is the diagnostic technique of choice.<sup>5</sup> PET/CT can direct the area for biopsy as it identifies tumor areas thanks to the greater greediness of neoplastic cells for glucose. In the case described, its contribution is demonstrated. Given our patient's characteristics and history and despite the fact that the initial diagnostic suspicion was pleural metastasis of breast carcinoma, the stepwise diagnostic study based on recommendations<sup>6</sup> essentially would not have varied even if mesothelioma was considered among the main suspected diagnoses.

We present a case of pleural mesothelioma secondary to radiotherapy used as a treatment for breast cancer. In spite of the limited frequency of pleural mesothelioma associated with radiotherapy due to breast carcinoma, we should consider this diagnostic pos-

sibility in patients with pleural thickening indicative of tumor affection and a history of thoracic radiotherapy. The application of the diagnostic protocol based on guidelines has been shown to be useful.

## References

- Montes I, Abu Shams K, Alday E, Carretero Sastre JL, Ferrer Sancho J, Freixa Blanxart A, et al. Normativa sobre asbesto y sus enfermedades pleuropulmonares. Arch Bronconeumol. 2005;41:153-68.
- Zablotska LB, Angevine AH, Neugut AI. Therapy-induced thoracic malignancies. Clin Chest Med. 2004;25:217-24.
- Witherby SM, Butnor KJ, Grunberg SM. Malignant mesothelioma following thoracic radiotherapy for lung cancer. Lung Cancer. 2007;57:410-3.
- Shannon VR, Nesbitt JC, Libshitz HI. Malignant pleural mesothelioma after radiation therapy for breast cancer. Cancer. 1995;76:437-41.
- Scherpereel A, Astoul P, Baas P, Berghmans T, Clayson H, Vuyst P, et al. Guidelines of the European Respiratory Society and the European Society of Thoracic Surgeons for the management of malignant pleural mesothelioma. Eur Respir J. 2010;35:479-95.
- Koeglenberg CF, Diacon AH. Pleural controversy: close needle pleural biopsy or thoracoscopy, which thoracoscopy, which first? Respirology. 2011;16:738-46.

Tamara Lourido-Cebreiro, Virginia Leiro-Fernández,\*  
Alberto Fernández-Villar

Unidad de Técnicas Broncopleurales, Servicio de Neumología,  
Complejo Hospitalario Universitario de Vigo (CHUVI), Vigo,  
Pontevedra, Spain

\* Corresponding author.

E-mail address: [virginia.leiro.fernandez@sergas.es](mailto:virginia.leiro.fernandez@sergas.es)  
(V. Leiro-Fernández).

<http://dx.doi.org/10.1016/j.arbr.2012.09.006>

## Spontaneous Pneumomediastinum: Is It a Sign of Severity, or Does It Depend on the Underlying Respiratory Process?\*

### El neumomediastino espontáneo: ¿indica «gravedad» o esta depende del proceso respiratorio subyacente?

Dear Editor,

With regard to the question we pose in the title, we would like to comment on spontaneous pneumomediastinum (SPM).

We have read with great interest the recently published Letter to the Editor, "A Child With Severe Pneumomediastinum and ABCA3 Gene Mutation: A Puzzling Connection".<sup>1</sup> We are interested in the relationship described between mutations of the ABCA3 gene and certain pulmonary pathologies associated with alterations in the surfactant. However, we disagree with the transcendental role that the authors attribute to SPM and its status of severity, which we believe to be inaccurate. Furthermore, we believe that what should be explored is the relationship between these genetic alterations and the pulmonary pathology that leads to the SPM, as the latter is just a consequence (presence of air in the mediastinum with no known cause).

SPM is a rare pathology in children and adults.<sup>2,3</sup> It is observed as a consequence of an increase in intra-alveolar pressure, alveolar rupture and migration of the air dissecting the peribronchial and perivascular sheaths of the pulmonary hilum, extending to the mediastinum.<sup>2-5</sup> This, at the same time, can propagate towards

the subcutaneous, endothoracic and peritoneal tissue, and even to the spinal canal. This mechanism is also known as the "Macklin effect", as Macklin was able to demonstrate this experimentally in 1937 by inflating the bronchi of cats. A few years later, Hamman made the first clinical report.<sup>4</sup>

Predisposing conditions that have been described include asthma, interstitial pulmonary diseases, COPD, bronchiectasis, lung cysts and lung cancer, among others. An increase in intra-alveolar pressure produced, for example, during vomiting, the inhalation of toxins, intense cough, physical exercise or childbirth, together with bronchopulmonary infections or the ingestion of a foreign body, may trigger an SPM.<sup>5</sup> The patient who was reported had presented acute respiratory infection associated with cough.<sup>1</sup>

SPM is considered a process with little clinical impact and a good prognosis.<sup>2-5</sup> It requires no more than oxygen therapy, analgesia, follow-up and treatment of the underlying cause, after which it completely resolves in a matter of a few days. Poor patient evolution is usually caused by the associated underlying lung disease. Tension pneumothorax and pneumopericardium are the exceptions: these should be considered severe and required specific treatment (emergency drainage).<sup>3,6</sup>

In our setting, pneumomediastinum and later subcutaneous emphysema are often a cause for panic in patients, family members and even some health-care staff, which may sometimes lead to inappropriate behavior and treatment. We therefore believe that it is important to clarify the true meaning of SPM.

## References

- Copertino M, Barbi E, Poli F, Zennaro F, Ferrari M, Carrera P, et al. Neumomediastino grave y mutación del gen ABCA3 en un niño: una relación enigmática. Arch Bronconeumol. 2012;48:137-40.

\* Please cite this article as: Rombolá CA, et al. El neumomediastino espontáneo: ¿indica «gravedad» o esta depende del proceso respiratorio subyacente? Arch Bronconeumol. 2012;48:483-4.