

with no apparent complications, and the patient was therefore discharged four days later.

Subcutaneous emphysema as a complication of oral surgery is infrequent (in a prospective study of 100 complications due to molar extraction, there were no patients with this pathology).² It is produced by the entrance of air in the facial planes of the face and neck through the area of the wisdom tooth extraction. Factors that predispose patients to emphysema have been described, the most frequent of these being the use of a drill³ (with air and water turbines) in up to 80% of cases, which introduces pressurized air at up to 16 mmHg. The roots of the first, second and third molars are directly connected with the sublingual and submandibular space. Meanwhile, the sublingual space is connected to the pterygomandibular, parapharyngeal and retropharyngeal spaces. Under pressure, the air enters through the molar roots to the retropharyngeal space, which is connected to the mediastinum. The symptoms may vary depending on the quantity of air, its location and the presence or absence of infection. Thus, we may find anywhere from a simple, self-limiting, subcutaneous emphysema that is practically asymptomatic to, if deeper planes are dissected, pneumomediastinum, pneumothorax or pneumopericardium that, when associated with infection, can cause cellulitis, Lemierre syndrome and mediastinitis.^{3,4} The majority of patients, however, are paucisymptomatic, like our patient. On physical examination, there are characteristic crepitations to palpation of the thoracic and cervical regions, and Hamman's sign may also be present³ (synchronic crunching with heartbeats), while there may be hypoventilation in the lung fields and deviation of the trachea if there is pneumothorax. The differential diagnosis is established with angioedema, anaphylactic reaction, hematoma and cellulitis.^{3,5} The diagnosis is radiological, using simple radiography in order to demonstrate the presence of air and CT to rule out associated collections. Emergency surgical decompression is required if there is cardiovascular collapse or obstruction of the airway, but this is uncommon. If the patient is asymptomatic, conservative treatment is recommended, with hospitalization under observation and prophylactic antibiotics in order to rule out the development of an infection. This is necessary because the use of non-sterile air and water during molar extraction has been described as a risk factor for infection.⁶ In most cases, the subcutaneous emphysema will begin to disappear in 3–5 days. It is important to advise patients to avoid high intraoral pressures as this could increase the introduction of air into the cervical area.

We conclude that the development of subcutaneous emphysema and pneumomediastinum during wisdom tooth extraction is a very uncommon complication, but that it should be kept in mind if an air turbine is used.

Funding

This article has been partially financed by the FFIS (Fundación para la Formación e Investigación Sanitaria de la Región de Murcia, Grupo FFIS-008).

Conflicts of Interest

The authors declare having no conflicts of interest.

References

1. Kunkel M, Morbach T, Kleis W, Wagner W. Third molar complications requiring hospitalization. *Oral Surg Oral Med Oral Pathol Oral Radiol Endod.* 2006;102:300–6.
2. Kunkel M, Kleis W, Morbach T, Wagner W. Severe third molar complications including death—lessons from 100 cases requiring hospitalization. *J Oral Maxillofac Surg.* 2007;65:1700–6.
3. Abadal JM, Álvarez MJ, De la Torre J, Guerra AB. Emfisema subcutáneo y neumomediastino secundarios a extracción dental. *Radiología.* 2002;44:27–9.
4. Chen S-C, Lin F-Y, Chang K-J. Subcutaneous emphysema and pneumomediastinum after dental extraction. *Am J Emerg Med.* 1999;17:678–80.
5. Ouahes N, Petit A, Poirier F, Sigal-Nahum M. Subcutaneous emphysema and pneumomediastinum following dental extraction. *Dermatology.* 1993;186:264–5.
6. Gamboa Vidal CA, Vega Pizarro CA, Almeida Arriagada A. Subcutaneous emphysema secondary to dental treatment: case report. *Med Oral Patol Oral Cir Bucal.* 2007;12:76–8.

Pilar Guillén-Paredes,^{a,*} Vania Novoa-Juiz,^b
Luis Carrasco-González^a

^a *Servicio de Cirugía General y Digestiva, Hospital Universitario Morales Meseguer, Murcia, Spain*

^b *Servicio de Otorrinolaringología, Hospital Universitario Morales Meseguer, Murcia, Spain*

* Corresponding author.

E-mail address: magirapi@hotmail.com (P. Guillén-Paredes).

doi:10.1016/j.arbr.2012.03.003

Osteonecrosis of the Jaw in a Patient With Advanced Non-Small-Cell Lung Cancer Receiving Bevacizumab[☆]

Osteonecrosis mandibular en un paciente con cáncer de pulmón no microcítico avanzado tratado con bevacizumab

Dear Editor:

Osteonecrosis of the jaw (ONJ) occurs in up to 18% of patients being treated with bisphosphonates due to bone metastases.¹ Recent evidence suggests that bevacizumab, a new antiangiogenic drug, could alone induce ONJ and that the combination of both drugs can increase the risk for ONJ.^{2,3} We present herein a case

of ONJ attributed to bevacizumab in a patient with advanced lung cancer, and we review the recent understanding on this subject.

A 57-year-old male was diagnosed with non-small-cell lung cancer. At the time of the diagnosis, the patient presented bone metastases in the right femur and iliac bone, and he received palliative radiotherapy combined with 4 mg of intravenous zoledronic acid once a month. At the same time, combined chemotherapy was begun with cisplatin (75 mg/m²) and paclitaxel (75 mg/m²) every 3 weeks. After completing 3 cycles, treatment with bevacizumab was added at a dose of 15 mg/kg every 3 weeks up to a total of 8 cycles. While the patient received this new treatment for 3 weeks, he reported low-grade fever with pain in the right jaw and painless swelling of the right eyelid. The patient used dentures and had mentioned no recent history of oral or dental surgery. Upon examination, we observed an area of uncovered bone at the back of the right jaw measuring 1.8 cm × 0.5 cm, which had a necrotic appearance with inflammation of the surrounding soft tissue (Fig. 1). The samples obtained with a swab of the area of the necrotic bone were

[☆] Please cite this article as: Katsenos S, et al. Osteonecrosis mandibular en un paciente con cáncer de pulmón no microcítico avanzado tratado con bevacizumab. *Arch Bronconeumol.* 2012;48:218–9.

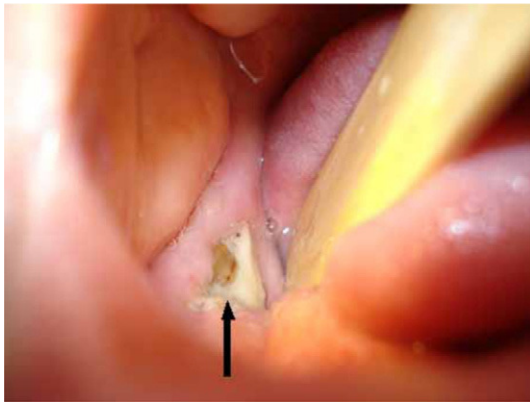


Fig. 1. Area of the uncovered bone at the back of the right jaw (black arrow).

negative for bacteria. Maxillofacial CT ruled out metastatic disease. The administration of bevacizumab and bisphosphonates was suspended, and the patient was treated with ampicillin-sulbactam 3 times a day for 21 days, while using mouthwash with 0.2% chlorhexidine. We observed remission of the inflammation and facial edema and an improvement, although without complete coverage of the exposed alveolar bone. As no other obvious cause was identified, we continued to presume that the most likely origin of the lesion was related to the medication (bevacizumab).

ONJ is a slowly developing process (over the course of 6 weeks) that is characterized by the exposure of the mandibular or maxillary bone in patients treated with bisphosphonates. Several risk factors have been identified, such as the administration of nitrogenous bisphosphonates, a prolonged treatment period, the concomitant use of corticosteroids, dental surgery and trauma caused by artificial dentures. However, its exact production mechanism is still not clear. Two main hypotheses have been suggested: osteoclast inhibition induced by the bisphosphonates and excessive suppression of bone metabolism and its antiangiogenic properties.¹

Vascular endothelial growth factor is overexpressed in different human tumors and it is also essential for osteogenic differentiation and bone formation. Bevacizumab, a monoclonal antibody that targets VEGF, exerts an intense anti-tumor effect, but, in combination with bisphosphonates, it induces ONJ with greater frequency (16%).^{2,4} In addition, treatment with bevacizumab alone has been related with ONJ in few case presentations.³

Osteonecrosis may also be caused by local radiotherapy, chemotherapy with corticosteroid content, diabetes, renal

osteodystrophy vasculitis or peripheral vascular disease.¹ In the present case, bevacizumab seems to be the product responsible for the lesion, and this is supported by the time association observed between the start of the administration of this drug and the appearance of the ONJ (12 weeks after starting administration). A possible synergic effect of the bisphosphonates could not be ruled out. Nevertheless, in that case one would have expected the presence of more evident clinical manifestations of ONJ before initiating the administration of bevacizumab. Microtrauma caused by artificial dentures of the patient may have also played a role by affecting the local microvascular integrity.

To date, no treatment has been established as being the most effective. Medical ozone (O₃) administered in an oily suspension may be a promising treatment, but the approach that is currently used is conservative.⁵ Proper oral hygiene, preventative measures and the avoidance of invasive dental interventions should be a part of standard patient care before initiating treatment with bevacizumab.

References

- Migliorati CA, Epstein JB, Abt E, Berenson JR. Osteonecrosis of the jaw and bisphosphonates in cancer: a narrative review. *Nat Rev Endocrinol.* 2011;7:34–42.
- Van Poznak C. Osteonecrosis of the jaw and bevacizumab therapy. *Breast Cancer Res Treat.* 2010;122:189–91.
- Estilo CC, Fornier M, Farooki A, Carlson D, Bohle 3rd G, Huryn JM. Osteonecrosis of the jaw related to bevacizumab. *J Clin Oncol.* 2008;26:4037–8.
- Christodoulou C, Pervena A, Klouvas G, Galani E, Falagas ME, Tsakalos G, et al. Combination of bisphosphonates and antiangiogenic factors induces osteonecrosis of the jaw more frequently than bisphosphonates alone. *Oncology.* 2009;76:209–11.
- Ripamonti CI, Cislighi E, Mariani L, Maniezzo M. Efficacy and safety of medical ozone (O₃) delivered in oil suspension applications for the treatment of osteonecrosis of the jaw in patients with bone metastases treated with bisphosphonates: preliminary results of a phase I–II study. *Oral Oncol.* 2011;47:185–90.

Stamatis Katsenos,^{a,*} Charalampos Christophylakis,^b Konstantinos Psathakis^a

^a Department of Pneumology, Army General Hospital of Athens, Atenas, Greece

^b Department of Medical Oncology, Army General Hospital of Athens, Atenas, Greece

* Corresponding author.

E-mail address: skatsenos@yahoo.gr (S. Katsenos).

doi:10.1016/j.arbr.2012.03.004