

Tension Pneumothorax as an Unusual Cause of Isolated Pulmonary Histiocytosis in Paediatrics

Neumotórax a tensión como causa infrecuente de histiocitosis pulmonar aislada en pediatría

To the Editor:

In Langerhans cell histiocytosis (LCH), there may be two forms of lung affection: one as part of a multiorgan LCH and another as isolated pulmonary affection (IPLCH).¹ We present a case of childhood LCH that is exceptional due to its clinical presentation and exclusively pulmonary affection.

The patient is a 6-year-old male, with no personal or family history of interest, who suddenly began to have pain in the left hemithorax and progressive respiratory difficulty. AP chest Rx (fig. 1A) revealed left tension pneumothorax requiring thoracocentesis. Thoracic HRCT (fig. 1B) showed an interstitial infiltrate with multiple nodules and cysts. Given the suspicion for interstitial pulmonary disease, bronchoalveolar lavage (BAL) and lung biopsy by means of video-assisted thoracoscopy were both performed. The histological and immunohistochemical study of the biopsy and BAL confirmed the diagnosis of LCH. Afterwards, affection of other organs was ruled out. The patient completed chemotherapy following LCH-III group I protocol (systemic disease with affection of risk organ). Seventeen months after the diagnosis, the patient remains asymptomatic, with a mildly restrictive pattern (FVC 71%, FEV1 98%, FEV1/FVC 110%) and slightly lower diffusion test (DLCO 72%).

The lung is an organ that is commonly affected in adults with LCH, and isolated lung affection is more frequent than the combined form.¹⁻⁴ In children, however, LCH usually involves other organs, and IPLCH is extremely rare,^{1,3,4} with a maximal incidence of 1-3 yrs.⁵ Pulmonary LCH in adults occurs almost exclusively in smokers,^{1,2,4}

while in children the association with tobacco smoke is not clear.^{1,4} About 25% of cases are asymptomatic and are diagnosed with a radiograph that had been ordered for another reason.² Two-thirds of patients present respiratory or constitutional symptoms.^{2,6} Spontaneous pneumothorax occurs in only 10-20% of cases.³ Physical examination is usually normal,² although a reduced vesicular murmur,⁶ rhonchus or wheezing can also be found.^{2,6} At diagnosis, lung function can be either normal² or show a variable pattern depending on the anatomical lesions and duration of the disease.² In the initial stages, radiology shows well-defined bilateral peribronchial nodules, mainly in the upper and middle lobes.^{3,6} In later stages, the nodules evolve into cysts smaller than 10 mm in diameter (reticular pattern),^{3,6} or even into pulmonary fibrosis (honeycomb lung or pulmonary emphysema).^{2,3,6} HRCT is the imaging technique of choice when given the suspicion of pulmonary LCH.² The definitive diagnosis requires the identification of LC granulomas in the tissue involved.² Generally it is necessary to recur to lung biopsy, usually by means of video-assisted thoracoscopy² guided by HRCT.² Electron microscopy shows the so-called Birbeck granules as being more numerous than in normal LC.^{2,3} The confirmation of the cell type is done by using immunohistochemical staining with monoclonal antibodies against the membrane antigen CD1a. The differential diagnosis should be done for with lymphangioleiomyomatosis, pneumopathy caused by reflux, sarcoidosis, Wegener, etc.⁶ There are no real data on the efficiency of the different therapeutic regimes.² The avoidance of tobacco smoke, both active and pasivo,¹ plays a crucial role in the treatment of IPLCH in adults.^{2,5} In the case of pneumothorax, it is necessary to drain it or even use pleurodesis.² Lung transplantation can be a therapeutic option in cases of severe respiratory failure or pulmonary hypertension^{2,6} as the disease can recur^{1,2} within the first year.² Although IPLCH in children is not usually associated with a poor prognosis,⁴ a long-term follow-up is necessary to evaluate its course, radiological changes and lung function every 3-6 months.^{2,3}

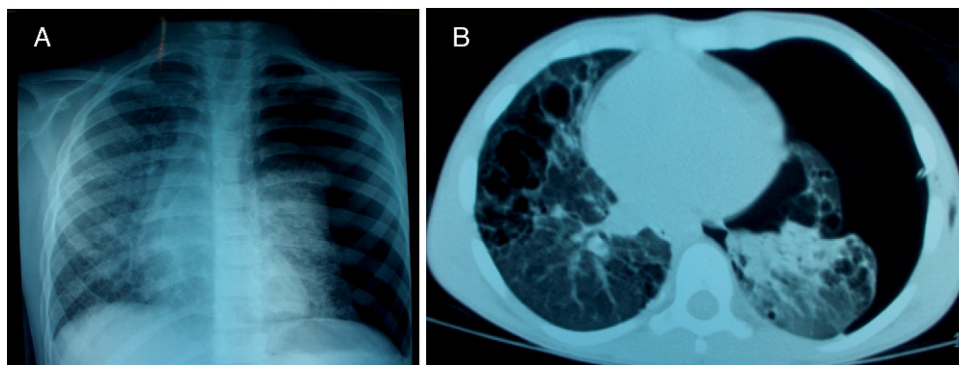


Figure 1. A) Anteroposterior chest radiograph with numerous cysts and nodules and collapsed left lung secondary to left tension pneumothorax; B) Pulmonary HRCT: interstitial infiltrate with multiple nodules and cysts and left tension pneumothorax.

References

1. Adams EP, Saucedo D, Oliver J, Cecalupo A. Isolated Pulmonary Langerhans Cell Histiocytosis in a 17-year-old Male. *J Pediatr Hematol Oncol.* 2007;29:121-4.
2. Tazi A. Adult pulmonary Langerhans' cell histiocytosis. *Eur Respir. J.* 2006;27:1272-85.
3. Alavi S, Ashena Z, Paydar A, Hemmati N. Langerhans cell histiocytosis manifesting as recurrent simultaneous bilateral spontaneous pneumothorax in early infancy. *Pediatrics International.* 2007;49:1020-2.
4. Aydin GB, Kibar E, Han Ü, Kale Y, Aslan A, Kose G. Pulmonary Langerhans Cell Histiocytosis in an Infant: Can Passive Smoking Accelerate the Disease Progress? *Pediatric Pulmonology.* 2007;42:565-7.
5. Nagy B, Soós G, Nagy K, Dezső B. Natural Course of Isolated Pulmonary Langerhans' Cell Histiocytosis in a Toddler. *Respiration.* 2008;75:215-20.
6. Leatherwood DL, Heitkamp DE, Emerson RE. Best Cases from the AFIP: Pulmonary Langerhans Cell Histiocytosis. *RadioGraphics.* 2007;27:265-8.

Catalina Márquez-Vega,^{a,*} Isabel Delgado-Pecellín,^b
Gema Ramírez Villar^a

^aUnidad de Oncología Pediátrica. Hospital Infantil Virgen del Rocío, Sevilla, Spain

^bUnidad de Neumología Pediátrica, Hospital Infantil Virgen del Rocío, Sevilla, Spain

*Corresponding author.

E-mail address: catimarquez@gmail.com (C. Márquez-Vega).

Primary Pulmonary Mucinous Cystadenocarcinoma: Presentation of a Case and a Review of the Literature

Cistoadenocarcinoma gigante mucinoso primario de pulmón: presentación de un caso y revisión de la literatura

To the Editor:

Pulmonary mucinous tumors are an infrequent entity, and the malignant presentations (cystadenocarcinoma and mucoepidermoid) are more frequent than the benign forms (cystadenoma or mucus gland adenoma),² presenting in patients near their fifties, with no clear difference between sexes.² There are only 20 cases reported of the cystadenocarcinoma subtype in the literature.

We present the case of a 67-year-old woman with moderate COPD, smoker of 30 pack-years. After treatment of what seemed to be a respiratory infection, thoracic computed tomography (CT) revealed a solid mass in the right upper lobe (RUL) that was 3.6 cm in diameter, with ipsilateral lymphadenopathies. A study was carried out with bronchoscopy, biopsy and PET, with no conclusive results. No surgical treatment was carried out at this time.

Afterwards, the patient did not attend periodic follow-up visits, and remained asymptomatic. Six years later, she presented with constitutional and respiratory infection symptoms. A new study was initiated of the lung mass with CT, revealing complete occupation of the RUL, persisting lymphadenopathies, mediastinal invasion and pleural effusion (fig. 1). FNAC demonstrated abundant mucinous material; two bronchoscopies showed evidence of complete stenosis of RUL and the bronchial biopsies were reported to be non-atypical bronchial mucus with a slight increase of the seromucous glands, with BAL and bronchial brushing negative for malignancy. Thick-needle lung biopsy showed fibrous tissue with no evidence of tumor. PET gave evidence of peripheral pathological captation of the mass and the lymphadenopathies, with no affectation at other levels. Echoendoscopy and mediastinoscopy were carried out, finding necrotizing granulomas with no signs of malignancy. Given the high suspicion for neoplasm and the lack of diagnostic confirmation, thoracotomy was performed and intraoperative biopsies taken until sufficient tumor tissue was visualized for the diagnosis, confirming the unresectability of the mass. The definitive diagnosis was mucinous primary pulmonary cystadenocarcinoma. The patient died six months after having received chemotherapy.

The spectrum of this type of neoplasm is extensive, having been described with multiple denominations.^{1,2} Perhaps the simplest classification is to group these tumors in accordance with the WHO into three entities: mucinous cystadenoma (localized cystic mass, full of mucus and surrounded by well-defined columnar mucinous epithelial wall), mucinous cystic tumor with atypia (invasive growth of the subjacent tissue with significant atypia and marked pseudostratification) and mucinous cystadenocarcinoma (cystic adenocarcinoma with abundant production of mucus that follows a pattern similar to that described in ovarian, breast and pancreatic tumors).¹ In most cases, the findings are incidental, asymptomatic and with no compromised lung function.³ They are generally slow-developing, although cases have been described of progression, and even of metastasis and recurrences.^{1,2} Radiography and thoracic CT are essential for the diagnosis.² Their confirmation is made by means of pathologic anatomy.⁵ The differential diagnosis is extensive, including bronchogenic cyst, mucus gland adenoma, mucoepidermoid carcinoma, mucinous bronchoalveolar carcinoma or mucinous adenocarcinoma metastasis. Treatment is based on complete resection of the tumor. Radiotherapy and chemotherapy seem to play a limited role in non-resectable tumors. The general prognosis is good,^{4,5} with an approximate survival rate of 75% at 5 years and 50% at 10 years.

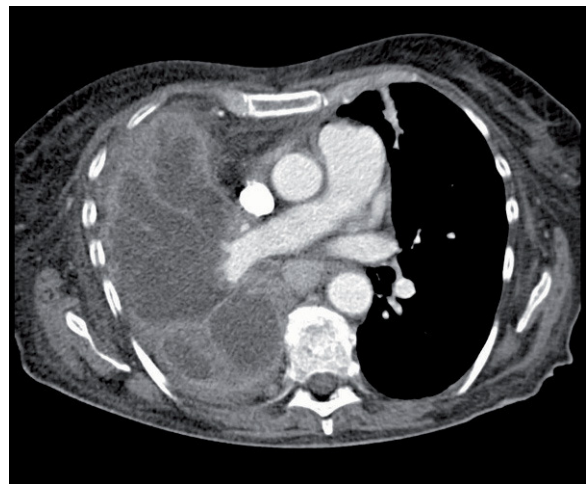

Figure 1. CT showing complete occupation of the RUL, persistent lymphadenopathies, mediastinal invasion and pleural effusion.