



Clinical Note

Pulmonary Pure Yolk-Sac Tumor. A Rare Anatomopathological Entity

Maria Elena Ramírez Gil,^{a,*} Primitivo Martínez Vallina,^a Patricia Menal Muñoz,^a Jorge Hernández Ferrández,^a Guillermo Muñoz Gonzalez,^b Juan José Rivas de Andrés^a

^aServicio de Cirugía Torácica, Hospital Universitario Miguel Servet, Zaragoza, Spain

^bServicio de Anatomía Patológica, Hospital Universitario Miguel Servet, Zaragoza, Spain

ARTICLE INFO

Article history:

Received March 8, 2010

Accepted March 23, 2010

Keywords:

Germ-cell tumors

Yolk-sac tumor

Lung

Palabras clave:

Tumores germinales

Tumores seno endodérmico

Pulmón

ABSTRACT

The most frequent location for non-metastatic germ cell tumors is the anterior mediastinum. Primary lung germ cell tumors are an exception in the medical literature, limited to just a few cases of choriocarcinomas and rare cases of yolk-sac tumors. In this paper, we report a case of a pulmonary yolk-sac tumor with atypical characteristics of diagnosis and treatment.

© 2010 SEPAR. Published by Elsevier España, S.L. All rights reserved.

Tumor del seno endodérmico primario de pulmón. Una rara entidad anatomopatológica

RESUMEN

La localización intratorácica más frecuente para los tumores germinales no metastáticos es el mediastino anterior. Los tumores de células germinales primarios de pulmón son una excepción en la literatura limitándose a algunos casos de coriocarcinomas y raros casos de tumores del seno endodérmico. En este artículo, se presenta un caso de tumor del seno endodérmico primario de pulmón de características atípicas en cuanto a la manera de diagnóstico y al tratamiento practicado.

© 2010 SEPAR. Publicado por Elsevier España, S.L. Todos los derechos reservados.

Introduction

Extragonadal germ-cell tumors are rare, especially located in the lung parenchyma. Within these tumors, primary endodermal sinus tumors of the lung are even rarer in the literature. This article reports an atypical case of presentation of this type of lesions.

Case Report

The patient is a 70-year-old male with a history of chronic atrial fibrillation, coxarthrosis and ex-smoker (40 packs/year). He had undergone surgery in June 2005 for stage-pT3N2M0 rectal adenocarcinoma, specifically anterior rectal resection with termino-

terminal anastomosis and later adjuvant treatment with chemo- and radiotherapy. In November 2006, left frontal basocellular carcinoma was resected.

In February 2008, follow-up CT of the colon neoplasm detected a nodule suspicious for metastasis of the colon adenocarcinoma, and the patient was remitted to our consultation for surgical resection evaluation.

CT revealed a bilobulated nodular lesion measuring 2 cm in diameter in the RUL adjacent to the mediastinum behind the right carotid artery, with no observance of any other parenchymatous lesions or lymphadenopathies of a pathological size or lesions at any other level. Likewise, PET was performed, where a single captation was found at the level of the RUL coinciding with the lesion on CT.

In April 2008, the patient underwent atypical resection of the nodule by small right thoracotomy. The postoperative period was incident-free, and the patient was discharged from the hospital 3 days later.

*Corresponding author.

E-mail address: meramirezgil@yahoo.es (M.E. Ramírez Gil).

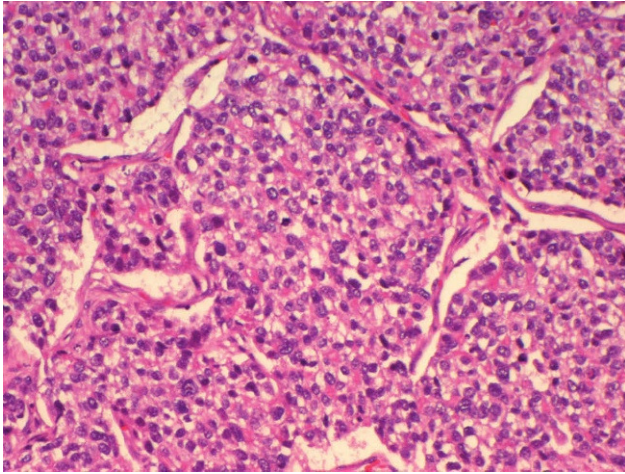


Figure 1. TDE H.E. 100×: detail of the lung neoplasia, presenting a solid pattern, with cytoarchitectural features of vitelline differentiation (H.E., 100×).

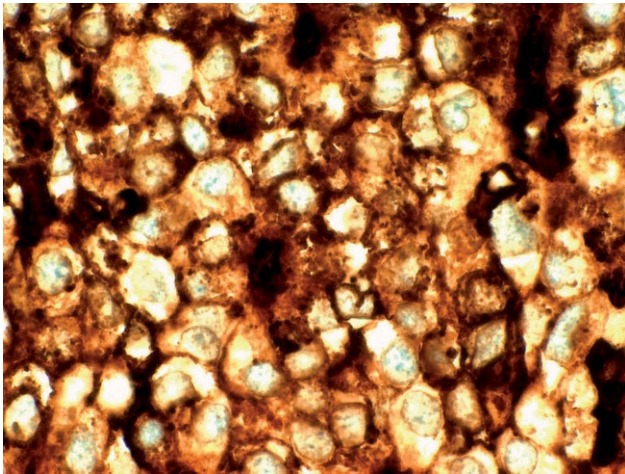


Figure 2. TDE AFP 400×: immunostaining for alpha-fetoprotein, showing intense cytoplasmic expression in the neoplastic cells. (AFP, 400×).

The pathological anatomy report determined a 35-mm epithelial neoplasia, with a glandular habit, clear cells and foci of coagulative necrosis (fig. 1) with free surgical margins. The immunophenotyping, done with a DAKO Autostainer and EnVision detection system for all the antibodies, showed expression of pan-keratin AE1/AE3, alpha-fetoprotein (fig. 2), EMA, CK8 and placental alkaline phosphatase at the level of the proliferating neoplastic cells, which did not express etaHCG, chromogranin, cytokeratin 7, cytokeratin 20, vimentin, smooth muscle actin, PSA, CEA, or CD10. Due to morphology, this immunophenotyping was not ascribable to a metastasis of the colorectal neoplasm, while suggesting a malignant epithelial tumor of a germ cell strain with a yolk sac pattern. Thus, the definitive anatomopathologic diagnosis was endodermal sinus tumor.

After receiving the pathological anatomy report, we performed an extension study including testicular ultrasound and abdominal CT,

discovering no pathological findings in any of the tests. Likewise, alpha-fetoprotein and beta-HCG levels were analyzed. In the case of alpha-fetoprotein, the post-surgery level was 60.7 (reference value <15) and decreased in follow-up controls until reaching levels within the range of normal, and are currently at 5.9. As for the beta-HCG levels, these have been normal after surgery and throughout the follow-up until today. Given the absence of findings in the extension studies carried out after surgery, the diagnosis made was primary yolk sac tumor of the lung.

The patient is currently asymptomatic, with no signs of relapse of any neoplasia on imaging tests and with all tumor markers within normal ranges.

Discussion

Malignant germ-cell tumors are usually located in the gonads. Extragenital germ-cell tumors are typically located in midline structures and, especially, the anterior mediastinum. Germinal cell tumors, and particularly pure endodermal sinus tumors, very rarely appear as primary lung tumors.

In the literature we have consulted, the cases published of primary pure endodermal sinus tumors of the lung are exceptional. In all cases, the patients were young (under the age of 50)¹⁻³ and had large lung masses. In contrast, our patient was older in age and, due to the previous neoplasia characteristics and later follow-up, the tumor was diagnosed at a very early stage, and it was initially suspected that it was a metastasis of the patient's previous digestive neoplasm.

In our case, the serum levels of alpha-fetoprotein and beta-HCG were studied after surgery, given the lack of suspicion of this type of tumor. Initially, increased alpha-fetoprotein was detected, but these levels normalized after a time. This fact is also reported by the authors of the other cases found in the bibliography.⁴ As in the other cases, the current follow-up of the patient includes, in addition to imaging tests, analysis of the serum levels of this hormone.

In the literature published, all the patients received treatment with adjuvant chemotherapy with bleomycin, cisplatin and etoposide. In one case,⁵ neoadjuvant chemotherapy was used, given the large size of the lesion. In our case, after being evaluated by the oncology unit, we decided not to apply other adjuvant treatments.

Despite the lack of data appearing in the literature and the lack of standardization in the treatment of these patients, surgical resection of these tumors seems to be indicated, followed by neoadjuvant chemotherapy, with good initial survival. In cases of large masses with presurgical histological diagnosis, the use of neoadjuvant chemotherapy could be indicated in order to reduce the size of the tumor and facilitate complete surgical resection.

References

1. Inoue H, Iwasaki M, Ogawa J, Shohtsu A, Abe Y, Satoh S, et al. Pure Yolk-sac tumor of the lung. *Thorac cardiovasc surg.* 1993;41:249-51.
2. Basoglu A, Sengul AT, Buyukkarabacak YB, Yetim TD, Yildiz L. Pure yolk-sac tumor of the lung. *Asian Cardiovasc Thorac Ann.* 2008;16:410-1.
3. Abdel-Rahman AR, Ebied EN, Nouh MA, Gal AA, Mansour KA. Primary yolk sac tumor of the lung. *Ann Thorac Surg.* 2009;87:1925-6.
4. Oshika Y, Matsukuma S, Hashimoto H, Takeo H, Sato K, Tanaka Y. Bophagic pulmonarty blastoma with a lesion of yolk sac tumor. *Gen Thorac Cardiovasc Surg.* 2007;55(6):243-7.
5. Chen CH, Chen TC, Huang WC, Chen TY, Liu HC. An unusual successfully treated case of pulmonary yolk sac tumor. *Ann Thorac Surg.* 2008;85:656-8.