

## Letters to the Editor

**Empyema Caused by *Legionella Pneumophila*\******Empiema por Legionella pneumophila***

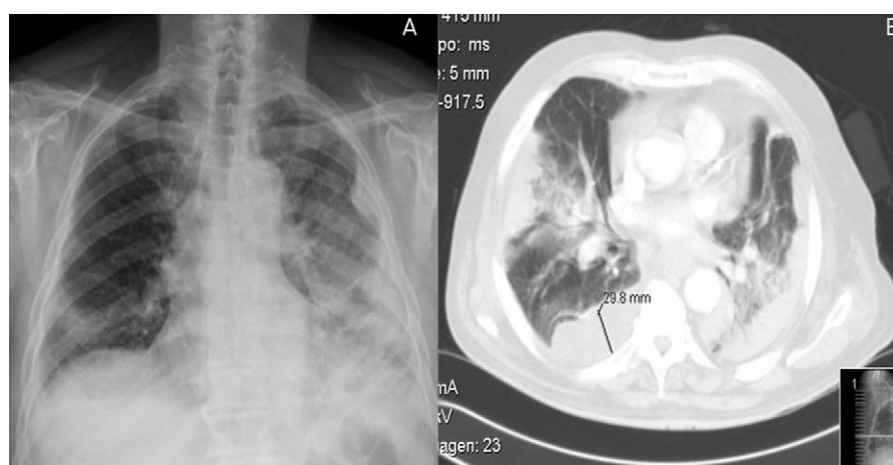
Dear Editor:

In *Legionella* infections, pleural affection is not infrequent, but the formation of empyema and the isolation of the microorganism in the pleural liquid are considered exceptional.<sup>1</sup>

A 65-year-old male, ex-smoker of 40 pack-years with no other history of interest, was admitted due to dyspnea, cough with very little expectoration of mucus and pleuritic-type pain in the left hemithorax that had been evolving over the previous 5 days without fever. Upon physical examination, we observed tachypnea; pulmonary auscultation revealed diminished vesicular murmur and wet crackles in the lower third of both hemithoraces as well as pleural friction rub in the lower third of the left hemithorax. The blood analysis showed evidence of leukocytosis (21 800/mm<sup>3</sup>) with neutrophilia (95%); C reactive protein, 34 mg/dl. Posteroanterior radiography revealed left pleural thickening, bilateral alveolar-interstitial pattern, condensation in both pulmonary bases and blunting of the left costophrenic angle (Fig. 1A). Thoracic computed tomography (CT) 48 h later demonstrated extensive bilateral alveolar condensation with predominantly right pleural effusion, several left pleural collections and inflammatory lymphadenopathies (Fig. 1B). Given the presence of acute-phase reactants and the radiological findings, antibiotic treatment was begun with intravenous levofloxacin and beta-lactams, and after the CT bronchoscopy was performed, which was compatible with an acute suppurative

process, and thoracocentesis, which showed a purulent exudate, with a pH of 7.22; 22 730 leukocytes/mm<sup>3</sup>; 73% neutrophils; 27% lymphocytes; glucose, 110 mg/dl; LDH, 2371 U/l, and proteins, 4.5 g/dl. Right thoracic drainage was begun with the instillation of 100 000 IU of urokinase and the emission of 500 ml over the course of 3 days. Organized left pleural effusion was treated conservatively as there was limited pleural space. The *Legionella* antigens in urine were positive, and 7 days later *L. pneumophila* growth was observed in the pleural liquid on BCYE $\alpha$  medium and later confirmed by PCR-STB (*sequence-based typing*). The other tests (bronchial aspirate culture, protected telescoping catheter, blood cultures) were negative. The evolution of the patient was favorable, with progressive remission of the symptoms and of the pulmonary infiltrates.

Disease caused by *Legionella* usually runs its course with cough, fever, anorexia, myalgia, cephalalgia and pleuritic pain in one-third of patients, in addition to other non-pulmonary manifestations. A small amount of pleural effusion has been reported in 10%–50% of the patients, and this may precede the development of the parenchymatous process. Empyema due to *L. pneumophila* and the isolation of the germ in the pleural liquid are both uncommon in the literature.<sup>1,2</sup> Few cases have been reported that run their course with pneumonia and empyema due to this microorganism, especially in immunosuppressed patients and transplant recipients.<sup>3,4</sup> Winn and Myerowitz<sup>5</sup> studied the necropsies of 74 patients diagnosed with legionellosis with pleural effusion and only in 5 cases was the volume more than 200 ml, with findings for empyema in 2 cases. *Legionella* cultures in BCYE $\alpha$  have been the gold standard for the diagnosis of legionellosis, with a sensitivity from 20% to 95% and specificity near 100%.<sup>6</sup> Rarely have positive cultures been obtained



**Figure 1.** Posteroanterior chest X-ray (A) and computed tomography (B) show extensive alveolar infiltrates predominantly in the left hemithorax and several organized pleural collections in a patient with empyema due to *Legionella pneumophila*.

\* Please cite this article as: Ferrufino E, et al. Empiema por *Legionella pneumophila*. Arch Bronconeumol. 2012;48:102–3.

from the pleural liquid as in our case. We conclude that, although empyema due to *L. pneumophila* is infrequent, it should be taken into consideration and, therefore, in geographical regions with a high prevalence, *Legionella* should be included in the protocol of invasive respiratory sample studies.

## References

- Ribera E, Ferrer A, Gelabert R, Xercavins M, Martínez-Vázquez JM. Pleural empyema caused by *Legionella pneumophila*. *Med Clin (Barc)*. 1989;92:605–7.
- Tan MJ, Tan JS, Hamor RH, File Jr TM, Breiman RF. The radiologic manifestations of Legionnaire's disease. The Ohio Community-Based Pneumonia Incidence Study Group. *Chest*. 2000;117:398–403.
- Gómez J, Cuesta F, Zamorano C, García Lax F. Pleural empyema in *Legionella pneumophila* nosocomial pneumonia in a patient with systemic lupus erythematosus. *Med Clin (Barc)*. 1992;99:358–9.
- Zamarrón Sanz C, Novoa García D, Fernández Vázquez E, Sánchez Guisande D, Pérez del Molino M, Gómez Ruiz D. Pulmonary abscess and pleural empyema caused by *Legionella pneumophila* in kidney transplant recipient. *Ann Med Interne*. 1993;10:547–8.
- Winn WC, Myerowitz RL. The pathology of the *Legionella* pneumonias. *Hum Pathol*. 1981;12:401–22.
- Den Boer JW, Yzerman EP. Diagnosis of *Legionella* infection in Legionnaires's disease. *Eur J Clin Microbiol Infect Dis*. 2004;23:871–8.

Eddy Ferruffino,<sup>a</sup> Carla Mejía,<sup>a</sup> Victoria Ortiz de la Tabla,<sup>b</sup> Eusebi Chiner<sup>a,\*</sup>

<sup>a</sup> Sección de Neumología, Hospital Universitario San Juan de Alicante, San Juan de Alicante, Alicante, Spain

<sup>b</sup> Sección de Microbiología, Hospital Universitario San Juan de Alicante, San Juan de Alicante, Alicante, Spain

\* Corresponding author.

E-mail address: [chiner\\_eus@gva.es](mailto:chiner_eus@gva.es) (E. Chiner).

doi:10.1016/j.arbr.2011.10.005

## Hiccups Induced by Midazolam During Sedation in Flexible Bronchoscopy<sup>☆</sup>

### Hipo inducido por midazolam durante la sedación en fibrobronoscopia

Dear Editor:

Midazolam is one of the most frequently used benzodiazepines for the conscious sedation used during bronchoscopy. It is highly satisfactory and tolerated by the patients without contraindications,<sup>1</sup> and it reduces the difficulty in performing the bronchoscopy technique by making it shorter. Its properties include its acting as a sedative, amnesiac, muscle relaxant, anxiolytic and anti-convulsive.<sup>2</sup> Despite being such a safe drug, it is necessary to know its possible risks in order to provide proper patient care and to optimize its use.

We performed flexible bronchoscopy on a 49-year-old non-smoker female patient who had previously occasionally taken benzodiazepines at home with no adverse effects. The patient was being studied due to mild hemoptoic expectoration with no other accompanying symptoms but with a bilateral pulmonary micronodular pattern on chest radiography. We administered 2 mg of 2% topical intranasal lidocaine and 2 mg of midazolam intravenously. Approximately one minute after the administration of the midazolam, we observed a case of adult hiccup that did not resolve after the intravenous administration of 10 mg of metoclopramide. It did, however, stop immediately after the later administration of 1 mg of intravenous flumazenil; therefore, we can establish the relationship with the drug. It was necessary to perform a second bronchoscopy in the same patient in which, once again, 3 mg of midazolam was administered after the previous perfusion of metoclopramide, and no hiccup episode occurred on this occasion. The final diagnosis obtained was advanced-stage lung adenocarcinoma.

Although it has been reported that various types of drugs are able to induce hiccup infrequently, especially corticosteroids and benzodiazepines (dexamethasone, methylprednisolone, chloridiazepoxide and midazolam among others),<sup>3</sup> it has been considered that there is little scientific evidence to definitively attribute the association to any one of them.<sup>4</sup> Nevertheless, in children a

significant incidence of hiccupping has been observed after the administration of midazolam, especially in those of younger ages.<sup>5</sup>

Although we know that benzodiazepines act on the central nervous system, the mechanism by which midazolam induces hiccup as an adverse reaction has not been clearly explained.<sup>6</sup> It seems to be related with the GABA neurotransmitters, which it stimulates to produce multiple effects, but this is not exactly clear.

In our case, the rapid response to flumazenil makes it quite likely that the appearance of hiccup can be attributed to midazolam.

We believe it is interesting to report that the presence of hiccup during bronchoscopy may be due to the use of midazolam and, if required, it may be easily reverted with flumazenil as this is a competitive antagonist of the receptors of short-acting benzodiazepines. In addition, it seems worthy to note that, as we have observed in our experience, the drug may be used once again in the same patient without major risk.

## References

- Ni YL, Lo YL, Lin TY, Fang YF, Kuo HP. Conscious sedation reduces patient discomfort and improves satisfaction in flexible bronchoscopy. *Chang Gung Med J*. 2010;33:443–52.
- Cases Viedma E, Pérez Pallarés J, Martínez García MA, López Reyes R, Sanchís Moret F, Sanchís Aldás JL. Eficacia del midazolam para la sedación en la broncoscopia flexible. Un estudio aleatorizado. *Arch Bronconeumol*. 2010;46:302–9.
- Giudice M. Drugs may induce hiccups in rare cases. *Can Pharm J*. 2007;140:124–6.
- Thompson DF, Landry JP. Drug-induced hiccups. *Ann Pharmacother*. 1997;31:367–9.
- Marhofer P, Glaser C, Krenn CG, Grabner CM, Semsroth M. Incidence and therapy of midazolam induced hiccups in paediatric anaesthesia. *Paediatr Anaesth*. 1999;9:295–8.
- Bagheri H, Cismondo S, Montastruc JL. Drug-induced hiccup: a review of the France pharmacologic vigilance database. *Therapie*. 1999;54:35–9.

Marta Arroyo-Cózar,<sup>a,\*</sup> Justo Grau Delgado,<sup>a</sup> Tanya Gabaldón Conejos<sup>b</sup>

<sup>a</sup> Servicio de Neumología, Hospital General Universitario de Elche, Elche, Alicante, Spain

<sup>b</sup> Servicio de Anestesia y Reanimación, Hospital General Universitario de Elche, Elche, Alicante, Spain

\* Corresponding author.

E-mail address: [m.arroyo.cozar@hotmail.com](mailto:m.arroyo.cozar@hotmail.com) (M. Arroyo-Cózar).

doi:10.1016/j.arbr.2011.11.007

<sup>☆</sup> Please cite this article as: Arroyo-Cózar M, et al. Hipo inducido por midazolam durante la sedación en fibrobronoscopia. *Arch Bronconeumol*. 2012;48:103.