

Table 1
Management of Bilateral ED According to Different Authors.

	Biopsy	Unilateral Treatment	Synchronic Bilateral Treatment	Sequential Bilateral Treatment
Bennett (1988)				✓
Machens (1992)			✓	
Hoffman (1996)				✓
Hsieh (1999) [2 cases]	✓		✓	
Müller (1999)			✓	
Turna (2002)				✓
Kara (2002)			✓	
Fibla (2007)		✓		
Benhima (2008)	✓	✓		
Kourda (2009)		✓		
Martínez (2011)				✓

together with others that are hyperintense in strata alternating with the fibrous layers.¹

Classically, there was an indication for the need to carry out biopsy.^{1,2,5} Today, due to the greater specificity of the imaging tests in making the diagnosis, this need has been relegated to the exceptional atypical presentation that can make more difficult the differential diagnosis with pathologies such as sarcoma, desmoid tumors, lipoma, fibroma, schwannoma or hemangioma.^{2,6}

Surgical treatment is usually reserved for symptomatic cases larger than 5 cm.^{1,2,6} In our cases, surgery was indicated sequentially due to the metachronic presentation in the first case and in order to avoid greater patient morbidity in the second. In the literature, synchronic as well as sequential or unilateral approaches (not contralateral) have been used (Table 1), each with favorable evolution and with no relapses. We may therefore conclude that

the method of choice is that which best fits the characteristics and needs of the patient.

In conclusion, it is suffice to state that bilaterality in ED, although rare, is possible and should be contemplated at the time of diagnosis.

References

1. Kourda J, Ayaddi-Kadour A, Merai S, Hantous S, Miled KB, Mezni FE. Bilateral elastofibroma dorsi. A case report and review of literature. *Orthop Traumatol Surg Res.* 2009;95:383-7.
2. Benhima MA, Bouyarmane H, Arssi M, Gourram H, Fnini S, Hassoun J, et al. Bilateral dorsal elastofibroma. *Chirurgie de la main.* 2008;27:266-8.
3. Kara M, Dikmen E, Kara SA, Atasoy P. Bilateral elastofibroma dorsi: proper positioning for an accurate diagnosis. *Eur J Cardiothorac Surg.* 2002;22:839-41.
4. Turna A, Yilmaz MA, Ürer N, Bedirhan MA, Gürses A. Bilateral elastofibroma dorsi. *Ann Thorac Surg.* 2002;73:630-2.
5. Hsieh SC, Shih TT, Li YW. Bilateral elastofibroma dorsi. Two case reports. *Clin Imaging.* 1999;23:47-50.
6. Hoffman JK, Klein MH, McInerney VK. Bilateral elastofibroma: a case report and review of the literature. *Clin Orthop Relat Res.* 1996;325:245-50.

Néstor J. Martínez Hernández,^{a,*} Santiago Figueroa Almanzar,^a Antonio Arnau Obrer^{a,b}

^a *Servicio de Cirugía Torácica, Consorci Hospital General Universitari de València, Valencia, Spain*

^b *Professor of Surgery, Universidad de Valencia, Valencia, Spain*

* Corresponding author.

E-mail address: nessmartinez@gmail.com

(N.J. Martínez Hernández).

doi:10.1016/j.arbr.2011.05.008

Tuberculous Pseudotumor of the Rhinopharynx*

Pseudotumor de rinofaringe tuberculoso

To the Editor:

Tuberculosis is a predominantly pulmonary disease, although practically all organs and systems can be affected given the hematogenous dissemination of the bacillus. Isolated tuberculosis of the upper aerodigestive tract is rare and is normally associated with primary pulmonary disease.¹ This is an underestimated location due to the oligosymptomatic presentation and to the difficulty for exploring this anatomical region.² We present the case of rhinopharyngeal tuberculosis secondary to pulmonary tuberculosis that was diagnosed by the histopathologic analysis of the nasopharyngeal pseudotumor that was presented.

The patient is a 25-year-old woman with a history of smoking and weekend alcohol consumption. She consulted with her primary care physician due to symptoms of odynophagia with asthenia and weight loss that had been evolving over several weeks. Initially, she was diagnosed with infectious mononucleosis and was prescribed antibiotics. Days later, she was seen by an otorhinolaryngologist due to persistence of the symptoms, now in addition to suppuration and otalgia of the left ear. She began corticosteroid treatment after being diagnosed with chronic pharyngitis. After losing 8 kg in 3 months, the appearance of nighttime sweating and hemoptoic sputum, she was once again seen in otorhinolaryngology in order

to rule out the otorhinolaryngological origin of the hemoptysis. On exploration, a vegetative mass was observed in the nasopharyngeal region, or cavum (Fig. 1A). Upon cervical palpation, several inflammatory laterocervical lymphadenopathies were detected. A biopsy was taken from the lesion observed in the nasopharynx, and the results demonstrated granulomatous disease with tuberculous necrosis in exudative phase. Chest radiography showed bronchogenic dissemination lesions on both upper lobes, coexisting with miliary dissemination (Fig. 1B). Mantoux came back negative twice, as did the sputum sample. In the Ziehl-Neelsen culture of the biopsied tissue, *Mycobacterium complex* sensitive to major tuberculostatics was isolated. The rest of the exploration was normal. The patient was treated with rifampicin, isoniazid and pyrazinamide for 4 months and rifampicin and isoniazid for 2 more months, with complete remission of the disease.

Tuberculosis of the upper aerodigestive tract almost always represents an evolution of advanced pulmonary tuberculosis and can affect the larynx, pharynx and epiglottis.³ These locations are generally resistant to the infection due to the cleansing and inhibitory action of saliva on the tuberculous bacillus,⁴ in addition to other influential factors (saprophyte flora, striated pharyngeal musculature). Symptoms include dysphonia and odynophagia, in addition to chronic expectoration. The clinical signs are varied, from ulcers to pseudotumors and secretory otitis.¹ Some authors describe the lesions that are observed in the pharynx as a group of granulations (miliary tuberculosis) that are similar to "grains of semolina" or "fish eggs".⁵ The base diagnosis should be based on the demonstration of tuberculous mycobacteria using cultures in special mediums (Lowenstein-Jensen, Middlebrook). The presence of acid-fast bacilli with auramine or Ziehl-Neelsen staining is suggestive of

* Please cite this article as: García-Lliverós A, et al. Pseudotumor de rinofaringe tuberculoso. *Arch Bronconeumol.* 2011;47:537-8.

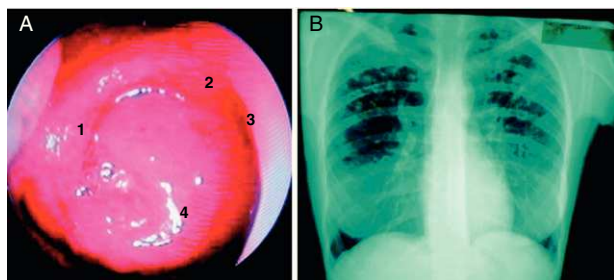


Fig. 1. (A) Image of a tumor mass in the rhinopharynx taken with nasal endoscopy: (1) Tubaric ring; (2) Choanal arch; (3) rear edge of the nasal septum; (4) TB pseudotumor. (B) Chest radiography: bronchogenic dissemination lesions in both upper lobes that coexist with miliary dissemination.

tuberculosis, but it is not pathognomonic.¹ It is very important to evaluate the disease as a whole, without obviating the different anatomical regions that may be affected by this pathology. On the other hand, the rhinopharynx is the anatomical location of varied benign and malignant tumor lesions. What is unusual about this case is that the tumor was tuberculous. In conclusion, this case illustrates the variety of possible clinical manifestations of pulmonary tuberculosis, as well as the histopathological diversity of the rhinopharynx, with the diagnostic and therapeutic difficulties that this implies.

Conflict of Interest

The authors declare having no conflict of interests.

References

1. Raviglione MC, O'Brien RJ, Kasper DL, Braunwald E, Fauci AS, Hauser SL, editors. Tuberculosis. Harrison. McGraw-Hill Professional; 2004. p. 1066-76.
2. Irriberry M, Zenarruzabeitia E, Irarragorri J. Tuberculosis de cavum: a propósito de un caso. Arch Bronconeumol. 2001;37:216-7.
3. Sá LC, Meirelles RC, Atherino CC, Fernandes JR, Ferraz FR. Laryngo pharyngeal tuberculosis. Braz J Otorhinolaryngol. 2007;73:862-6.
4. Chakravarti A, Pal S, Sahni JK. Primary tuberculosis of tonsil and posterior oropharyngeal wall. Indian J Tuberc. 2008;55:48-50.
5. Srirompotong S, Yimtae K. Tuberculosis in the upper aerodigestive tract and human immunodeficiency virus coinfections. J Otolaryngol. 2003;32:230-3.

Ainhoa García-Lliberós,* Miguel Armengot, Consuelo Calabuig

Hospital General Universitario, Facultat de Medicina, Universitat de Valencia, Valencia, Spain

* Corresponding author.

E-mail address: ainhoa.glliberos@gmail.com (A. García-Lliberós).

doi:10.1016/j.arbr.2011.06.008