

With COPD patients there is a series of circumstances which make this type of conversations easier, for example the patient's trust in their doctor and the numerous opportunities offered by routine consultations during stable phases of the disease. It is important to take advantage of this to find a moment and pause, to talk about the future, about the patient's personal wishes in the event of becoming seriously ill or at times of uncertainty, in order to plan the end of their life according to their values and preferences. Health care professionals need ongoing training in end-of-life problems and advance care planning. If the model of good practice is to become more deliberative and participative, it will be necessary to improve the patients' involvement in decision-making, which nowadays rarely happens. Therefore, the first step is to improve the quality of the information process, a basic requirement to start making decisions.

Funding

Research assistance from the Respira foundation, SEPAR GRANTS 2002.

References

1. Couceiro A, Pandiella A. La EPOC: un paradigma para el uso de directivas previas y la planificación anticipada de decisiones. Arch Bronconeumol. 2010;46:325-31.
2. Saralegui I, Corral E, Urturi JA, Labaien F, Pérez C, Martín A, et al. What do chronic obstructive pulmonary disease patients know about mechanical ventilation? Intensive Care Med. 2004;30(Suppl 1):S102.
3. Roter DL, Larson S, Fischer GS, Arnold RM, Tulskey JA. Experts practice what they preach. A descriptive study of best and normative practices in end-of-life discussions. Arch Intern Med. 2000;160:3477-85.
4. Johnson SC. Advance Directives: from the perspective of the patient and the physician. J R Soc Med. 1996;89:568-70.
5. Schaberg DR. Managing patients with chronic bronchitis: from primary prevention to advance directives. Hosp Pract (Minneapolis). 2000;35:43-50.
6. Gallo JJ, Straton JB, Klag MJ, Meoni LA, Sulmasy DP, Wang NY, et al. Life-sustaining treatments: what do physicians want and do they express their wishes to others? J Am Geriatr Soc. 2003;51:961-9.

Iñaki Saralegui

Servicio de Medicina Intensiva, Hospital Santiago, Vitoria, Spain

E-mail address: inaki.saralegui@osakidetza.net

Diaphragmoplasty with Patch on the Hepatic Hydrothorax due to Pleuroperitoneal Fistula

Diafragmoplastia con parche en el hidrotórax hepático debido a fístula pleuroperitoneal

To the Editor:

Hepatic hydrothorax (HH) due to a pleuroperitoneal fistula (PPF) is a rare entity. Due to large amounts of pleural fluid, it frequently causes dyspnea and electrolytic imbalances. Its diagnosis is suspected in patients with confirmed cirrhosis and portal hypertension suffering from unilateral pleural effusion, in general found on the right side.¹ We report the case of a patient with HH due to a PPF, which was detected as a transdiaphragmatic defect by scintigraphy using Tc99-labelled macroaggregated albumin. Repair surgery was performed through a right thoracotomy and a mesh was applied, which we called a diaphragmoplasty.

The patient was referred to our clinic with dyspnea that had started 3 months earlier, opacity in the lower right lung, and the presence of pleural fluid, detected with a chest x-ray. The patient's medical records revealed a 7-year history of cirrhosis. The patient had undergone insertion of a small-calibre catheter to drain the pleural cavity and an incomplete pleurodesis with talc. There was no vesicular respiration in the lower area of the right hemithorax. We also inserted a small-calibre catheter for drainage. After 12 h, 3500 ml of liquid had been drained. The suspected diagnosis was HH. Twenty milliliters of diluted methylene blue was administered in the peritoneal cavity. In the following 20 minutes the liquid flowed out of the chest catheters. The scan after the administration of Tc99-labelled macroaggregated albumin showed the location and size of the transdiaphragmatic defect. After the 6th minute of the scan, the contrast medium moved to the right hemithorax from the hepatic area (Figure a, b). The defect was located in the posterolateral

segment of the diaphragm. When the thoracotomy was performed, the diaphragm had stopped working. In the posterolateral area there was no muscle tissue in an area of 3×4 cm. This defective area had a fibrotic structure. The patient was treated with diaphragmoplasty through the right thoracotomy. The surgical treatment consisted of: 1) right thoracotomy, complete exploration of the right diaphragm; 2) marking the defective area; 3) placing a layer over the defective area; 4) suturing the layer; and 5) reconstruction of the whole area of the diaphragm with a mesh (Figure c). The defect in the diaphragm component was corrected with a wide 1.4 mm thick Gore-Tex® patch (W. L. Gore & Associates, Flagstaff, AZ) using continuous suture (2-0 Prolene, Ethicon, Somerville, United States). The patch was trimmed to reduce the fold in the diaphragm. The diaphragmoplasty is shown in detail in the diagram (Figure d). The postoperative course was uneventful from a surgical viewpoint and the patient made a full recovery.

HH can be defined as the pathological migration of large quantities of ascitic fluid through the diaphragm in patients without any other underlying disease apart from cirrhosis of the liver.² However, it is usual to find proof of these effects with non-invasive imaging techniques. The rarity of detecting these defects of the diaphragm is explained below. Diaphragm defects can be divided into 4 types: Type 1: large; type 2: small; type 3 and 4: smaller.³ For diaphragm defect types 1-3, drainage and pleurodesis, or a peritoneovenous shunt can be performed. However, type-4 defects require surgical correction. A few case studies have described the satisfactory surgical correction of the defects of the diaphragm responsible for the fluid migration into the pleural cavity.⁴ The authors used video-assisted thoracoscopy to correct the defects in the diaphragm, as well as pleurodesis. Six of the cases made a complete recovery and there were no relapses.⁵ Furthermore, reinforcing the diaphragm with the pleura or a mesh seems to be a promising treatment for refractory HH.⁶ However, migration through the diaphragm may continue. Of course, the suggested treatment is a liver transplant. In conclusion,

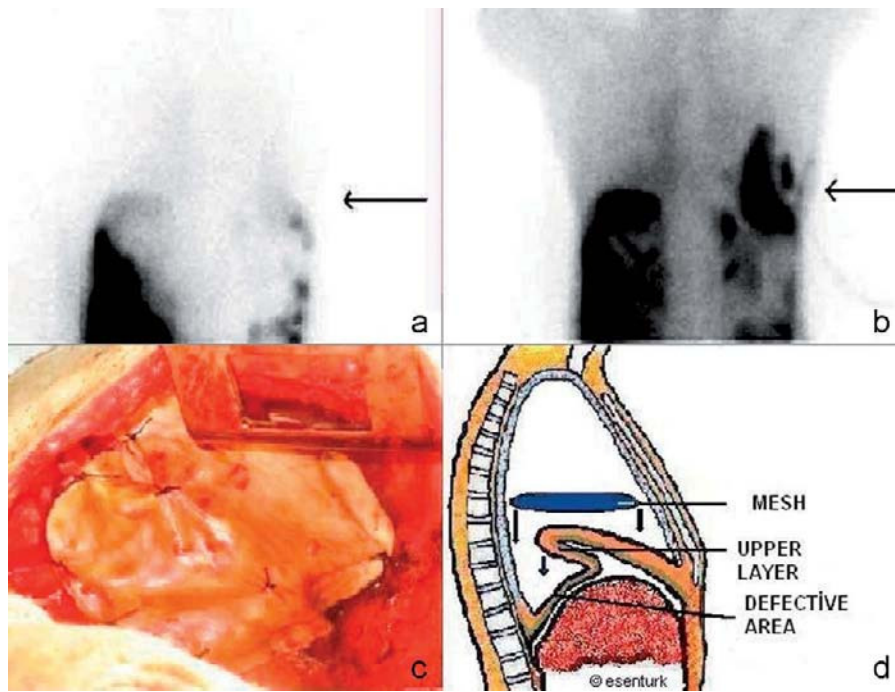


Figure. Lung scintigraphy with Tc99 contrast. Arrows at diaphragm level: a) First minute, b) 6th minute, c) Placing the Gore-Tex® mesh on the diaphragm, d) Diagram of the diaphragmoplasty. *Legend:* 1. Mesh. 2. Upper layer 3. Defective area.

diaphragmoplasty may be a good choice for treating respiratory failure due to significant transdiaphragmatic defects.

Conflict of Interest

The author affirms they have no conflicts of interest.

References

1. Roussos A, Philippou N, Mantzaris GJ, Gourgouliannis KI. Hepatic hydrothorax: pathophysiology diagnosis and management. *J Gastroenterol Hepatol.* 2007;22:1388-93.
2. Alberts WM, Salem AJ, Solomon DA, Boyce G. Hepatic hydrothorax. Cause and management. *Arch Intern Med.* 1991;151:2383-8.
3. Lin DJ, Wang MF, Gao GX, Li B, Su LL, Zhu L, et al. The value of thoracoscopy for diagnosis and management of refractory hepatic hydrothorax. *Zhonghua Jie He He Hu Xi Za Zhi.* 2006;29:665-7.

4. Temes RT, Davis MS, Follis FM, Pett Jr SB, Wernly JA. Videothoroscopic treatment of hepatic hydrothorax. *Ann Thorac Surg.* 1997;64:1468-9.
5. Mouroux J, Perrin C, Venissac N, Blaive B, Richelme H. Management of pleural effusion of cirrhotic origin. *Chest.* 1996;109:1093-6.
6. Huang PM, Kuo SW, Lee JM. Thoracoscopic diaphragmatic repair for refractory hepatic hydrothorax. *Thorac Cardiovasc Surg.* 2006;54:47-50.

Serdar Sen, Ekrem Senturk*

Adnan Menderes University, Medicine Faculty, Thoracic Surgery, Aydin, Turkey

*Corresponding author.

E-mail address: ekremsenturk@hotmail.com (E. Senturk).

Pneumonia Due to *Dialister pneumosintes* in a Patient With Chronic Obstructive Pulmonary Disease

Neumonía por Dialister pneumosintes en un paciente con EPOC

To the Editor:

In patients with chronic obstructive pulmonary disease (COPD), pneumonia is a frequent complication that is generally caused by common microbes. We report a clinical case of a patient with pneumonia due to *Dialister pneumosintes*. A review of PubMed from 1960 to the present revealed that this microbe has not been isolated as a cause of pneumonia in patients without risk factors.

The patient was 74 years old at the time of examination, and was an ex-smoker and ex-drinker. He also had COPD and was undergoing no regular treatment. The patient was being followed up as an outpatient in the pneumology department as he had suffered from recurrent infections in the past 5 years. During this time, pseudonodular infiltrates that changed location had been observed in follow-up chest CT scans. Fiberoptic bronchoscopy had also been performed and showed no malignancy or bacteria that could have caused these infiltrates. Tumor markers had also been found that ruled out the presence of malignancy. After 3 years without COPD exacerbations, the patient was discharged.

One year later, the patient was readmitted as the dyspnea had worsened with the patient suffering even at rest, accompanied by