

## Letters to the Editor

### Non-specific Interstitial Pneumonia with Unusual Symptoms

#### *Neumonía intersticial inespecífica con síntomas poco comunes*

To the Editor:

The diffuse parenchymal lung diseases (DPLD) are a group of disorders that affect the spacing between the epithelial and endothelial membranes of the lung bases.<sup>1</sup> The approach recommended in patients with DPLD is the detailed study of the clinical history, findings on physical examination, and the

performance of certain lab tests, imaging studies, and, in some patients, transbronchial or surgical lung biopsy.<sup>2</sup>

A 26-year old woman presented cough, sputum, exertion dyspnea, loss of appetite, night sweats and weight loss. The cough and exertion dyspnea had started 6 years earlier. The sputum and the loss of appetite and weight appeared one year before her first visit to our office. In her clinical history, she informed us that she had been treated for tuberculosis the year before. The diagnosis of tuberculosis was made based on symptoms and a radiologic study. Since the symptoms and the radiological findings did not respond to inspecific treatment, tuberculosis was diagnosed based on the symptoms and

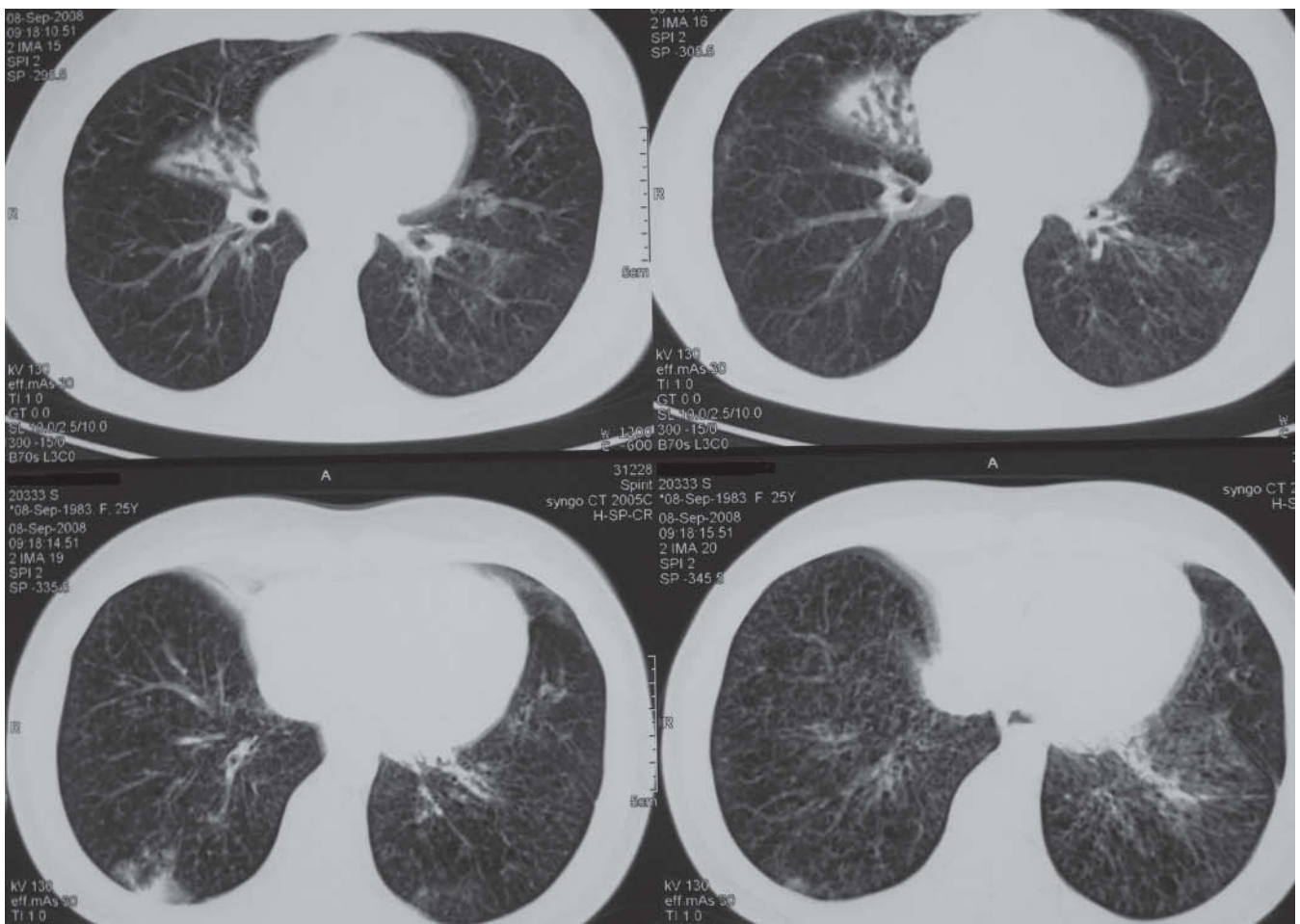


Figure 1. Computerised tomographies of the patient.

the radiological results. During the treatment for tuberculosis, her symptoms were not completely resolved. When they worsened, she sought assistance in our outpatient clinic. After routine tests, a CT scan was performed. Bronchiectasis was observed in the right middle lobe and in the lower left, as well as reticulonodular density predominantly in the lower left lobes of both lungs. Subpleural conservation of these lesions was also observed (fig. 1). She was hospitalised and antibiotic treatment was administered, due to the purulent sputum and fever. After the treatment, she was advised to undergo a bronchoscopy, but the patient refused.

One month later, her symptoms had worsened and another CT lung scan was performed. The lesions showed signs of progression. A bronchoscopy was performed, as well as a transbronchial fine needle aspiration, bronchioalveolar lavage, and a transbronchial biopsy. The results of these procedures did not reveal any indication about the nature of the illness, so the patient was advised to undergo a surgical lung biopsy and wedge biopsy. The pathological diagnosis of the patient was inspecific interstitial pneumonia (NII) and treatment with 1 mg/kg of prednisolone was started.

The radiological findings typical in patients with idiopathic pulmonary fibrosis is peripheral reticular opacity predominantly in the lung bases. In some cases, the CT features of NII may overlap with those most commonly found in the usual NII type (NIU). As with NIU, the abnormalities in NII generally predominate in the middle and lower segments of the lungs. However, they are less likely to occur in a subpleural distribution in NII than in NIU; in fact, the absence of subpleural involvement leads to a marked preference for NII.<sup>3</sup> In our case, the lesions were located predominantly in the lower lobe and, also, their subpleural preservation was observed.

The fact that tuberculosis is more common in Turkey led to a misdiagnosis, due to the fact that some of the symptoms present were also seen in tuberculosis, and the initial lesions did not respond to inspecific treatment. As in our case, there are many lesions that simulate those of tuberculosis and, therefore, it must first be ruled out in any region where their incidence is frequent. In this patient,

tuberculosis was first diagnosed, although sputum staining to detect acid-resistant tuberculosis bacteria was negative. The patient received treatment for tuberculosis (300 mg/day isoniazide, 600 mg/day rifampicine, 1,500 mg/day pyrazinamide, and 1,000 mg/day etambutol). Although she completed the treatment, she did not recover. Given the situation, the possibility of other illnesses was investigated and, thanks to the surgical biopsy, the diagnosis of NII was achieved. Surgical lung biopsy is the definitive procedure to obtain a diagnosis of NII. As in our case, there is much data to support the value of surgical lung biopsies to achieve a final diagnosis, in many cases, of DPLD.<sup>2</sup>

According to this case, NII can also be considered in situations in which it is not possible to interpret the radiological findings, although the symptoms are not typical in this disease, for example, loss of appetite and weight, and night sweats.

## References

1. American Thoracic Society, European Respiratory Society. American Thoracic Society/European Respiratory Society international multidisciplinary consensus classification of the idiopathic interstitial pneumonias. *Am J Respir Crit Care Med.* 2002;165:277-304.
2. Martinez FJ. Idiopathic interstitial pneumonias. Usual interstitial pneumonia versus nonspecific interstitial pneumonia. *Proc Am Thorac Soc.* 2006;3:81-95.
3. Misumi S, Lynch DA. Idiopathic pulmonary fibrosis/ usual interstitial pneumonia: imaging diagnosis, spectrum of abnormalities, and temporal progression. *Proc Am Thorac Soc.* 2006;3:307-14.

Yavuz Havlucu,<sup>a,\*</sup> Levent Ozdemir,<sup>a</sup> Suat Durkaya<sup>b</sup> and Erkan Sahin<sup>c</sup>

<sup>a</sup>Department of Chest Diseases, Hospital Estatal Dortyol, Hatay, Turkey

<sup>b</sup>Thoracic Surgery Department, Hospital Estatal Iskenderun Korfez, Hatay, Turkey

<sup>c</sup>Department of Radiology, Hospital Antakya Defne, Hatay, Turkey

\*Corresponding author.

E-mail address: dyhavlucu@yahoo.com (Y. Havlucu).

## Miliary Tuberculosis Due to BCG in an Asymptomatic Patient: Initial Onset or a Condition Not Yet Described?

### *Tuberculosis miliar por BCG en un paciente asintomático: ¿afectación inicial o una entidad no descrita?*

To the Editor:

Bacille Calmette-Guerin (BCG) is a live attenuated strain of *Mycobacterium bovis*, a species of the *Mycobacterium tuberculosis* complex group. BCG have been used in the treatment of in situ and superficial bladder cancer since the decade of the 70s.<sup>1-3</sup> Its effectiveness has been demonstrated in numerous studies, although its use is not free of complications, which have been reported to be local and systemic reactions. Although very rare, but with a high mortality, one of these complications is miliary tuberculosis (MTB).<sup>1,2</sup> We report a rare case of a patient who, in the absence of respiratory or general symptoms, was diagnosed with a TBM after intravesical BCG administration. He was a 62 year old man without toxic habits and with no respiratory history of interest. After consulting for hematuria, he was diagnosed with stage I transurethral endoscopic papillary transitional cell carcinoma, so three weeks later he began treatment with monthly intravesical administrations of BCG (Connaught strain, 10<sup>9</sup> colony forming units per dose). Anti-tuberculosis prophylaxis was not carried out prior to treatment. After the sixth cycle a colon CT was carried out to follow up on a prior intestinal polyp disease that showed a micronodular pattern in

the upper cuts. The patient denied having any general or respiratory symptomatology and the analyses were completed, including HIV status and phase reactants, all completely normal. Based on the radiologic findings, a chest CT was carried out (fig. 1) that confirmed a diffuse, bilateral micronodular pattern without finding other parenchymal or mediastinic lesions. Chest X-ray at this time came out normal. A bronchoscopy with transbronchial biopsies (BTB) was carried out as well as bronchoalveolar lavage (LBA). The microscopic description of the BTB was non-necrotizing epithelioid granulomas. Stains and cultures for mycobacteria and DNA and RNA amplification techniques for *M. tuberculosis* were negative in the LBA. Specific PCR for *M. tuberculosis* were positive in the biopsies. A diagnosis was made of probable TBM secondary to endovesical administration of BCG. Anti-tuberculosis treatment was initiated with rifampicine and isoniazide for 9 months, to which etambutol was added during the first two months, without adverse effects from the medication during follow-up. In the follow-up chest CT at 3 months a reduction in the number of nodules was seen with complete disappearance in some lung segments.

Although intravesical BCG administration is usually well tolerated by most patients, multiple local complications have been reported such as cystitis, prostatitis, orchitis, urethral obstruction, and also systemic reactions, including fever and less frequently (<1%), rash, polyarthralgia and arthritis, granulomatous hepatitis and various forms of respiratory impairment.<sup>1-4</sup> Among these various types of parenchymal involvement should be highlighted, such as the TBM, interstitial pneumonitis or diffuse alveolar damage, which in most