



Clinical Note

Unilateral Painful Diaphragm Paralysis as the Only Sign of Amyotrophic Neuralgia

Marina Blanco-Aparicio,^{a,*} Carmen Montero-Martínez,^a Dolores Couto-Fernández,^b Berta Pernas,^a María Fernández-Marrube^a and Héctor Vereja-Hernando^a^aServicio de Neumología, Complejo Hospitalario Universitario, A Coruña, Spain^bServicio de Neurología, Complejo Hospitalario Universitario, A Coruña, Spain

ARTICLE INFO

Article history:

Received August 1, 2009

Accepted September 22, 2009

Keywords:

Neuropathy

Amyotrophic neuralgia

Diaphragmatic paralysis

Phrenic nerve

Palabras clave:

Neuropatía

Neuralgia amiotrófica

Parálisis diafragmática

Nervio frénico

ABSTRACT

Amyotrophic neuralgia is an inflammatory and idiopathic neuropathy characterised by neuropathic pain. It was first described in 1948 as an affection of just the brachial plexus and was called Parsonage-Turner syndrome. Although this syndrome is more frequent in the brachial plexus, it may affect concomitantly or in isolation the phrenic nerve, which diagnosis is particularly difficult without high clinical suspicion.

We present a patient with amyotrophic neuralgia whose only manifestation was left phrenic nerve involvement, and we highlight the resistance of the pain to analgesics, as well as the persistence of the symptoms and diaphragm problems for more than six months.

© 2009 SEPAR. Published by Elsevier España, S.L. All rights reserved.

Parálisis diafragmática unilateral dolorosa como única manifestación de la neuralgia amiotrófica

RESUMEN

La neuralgia amiotrófica es una neuropatía inflamatoria e idiopática que se caracteriza por dolor neuropático. Se describió por primera vez en 1948 como una afectación sólo del plexo braquial y se denominó síndrome de Parsonage-Turner. Aunque este síndrome es más frecuente en el plexo braquial, puede afectar de forma concomitante o aislada al nervio frénico, y en esta circunstancia el diagnóstico es muy difícil si no hay alta sospecha clínica.

Presentamos el caso de un paciente con neuralgia amiotrófica cuya única manifestación fue la afectación frénica izquierda, y destacamos la refractariedad del dolor a los analgésicos, así como la persistencia de los síntomas y de la alteración diafragmática durante más de 6 meses.

© 2009 SEPAR. Publicado por Elsevier España, S.L. Todos los derechos reservados.

Introduction

Unilateral diaphragmatic paralysis may be idiopathic¹ or secondary to multiple causes, among which the most common is a tumour with phrenic nerve involvement or surgical trauma, but it has also been described in rare circumstances.² In its idiopathic form, viral infection

has been identified as the most likely aetiology and is usually asymptomatic. In highly symptomatic cases with only one hemidiaphragm elevation we should suspect incomplete involvement of the contralateral diaphragm³ or involvement of the intercostal muscles. In both cases, the characteristic symptom of diaphragmatic paralysis is exertional dyspnea and/or in the supine position, but it rarely involves pain.

We describe a patient with unilateral diaphragmatic paralysis, whose only symptom was a nagging pain with ipsilateral arm movements, refractory to high doses of various painkillers and persistent 6 months after diagnosis.

* Corresponding author.

E-mail address: mba@mundo-r.com (M. Blanco-Aparicio).

Clinical Observation

A male patient, 49 years old, ex-smoker with cumulated consumption of 20 pack-years, with no other clinical-surgical history. He visited for a 3-month history of nagging pain in the left chest that radiated to the dorsal region upon sudden movements or upon exertion of the left arm, and that provoked dyspnea. He also complained of occasional pain in the right flank. He was asymptomatic at rest. He had no muscular weakness nor loss of sensation. He had no history of viral infection, recent vaccination, strenuous exercise, surgery, trauma or family history of hereditary amyotrophic neuralgia (NA).

Physical examination revealed a temperature of 36.5° C and blood pressure of 120/80 mmHg. In the lung auscultation there was hypophenesis in the left base. The detailed neurologic examination showed that language, cranial nerves, strength, both superficial and deep sensitivity and reflexes were not altered, and there was no atrophy or fasciculations. The blood count, general biochemistry and values of muscle enzymes (creatin kinase and aldolase), ESR, CRP, thyroid hormones, antibodies antineutrophil cytoplasmic anti-nuclear and rheumatoid factor were normal. Chest X-ray showed elevation of the left hemidiaphragm (fig. 1), and fluoroscopia confirmed paresis of that diaphragm. Arterial blood gasometry showed a pH of 7.43, arterial oxygen pressure of 83 mmHg and arterial carbon dioxide pressure of 36 mmHg. There was no desaturation (time below 90% saturation: 0.35%) in the nocturnal pulsoximetry. Lung function tests showed a forced vital capacity (FVC) of 3,240 ml (68% of predicted), forced expiratory volume in one second (FEV₁) of 2,340 ml (65% predicted), FEV₁ / 72% FVC, total lung capacity of 5820 ml (89% of predicted), residual volume of 2650 ml (127% of predicted), functional residual capacity of 3330 ml (93% of predicted), diffusing capacity carbon monoxide of 73% and diffusing capacity corrected for alveolar volume of 86%. Maximal inspiratory and expiratory pressure were 6.11 kPa (57% of predicted) and 8.50 kPa (62% of predicted), respectively. CT scans of the neck and mediastinum as well as magnetic resonance of the spinal cord were normal. Studies of left phrenic nerve conduction showed increased response latency (10.5 ms), duration of 24.8 ms, and decreased amplitude (0.5 mV) on the opposite side, which was indicative of phrenic nerve involvement (fig. 2). The electromyogram (EMG) of the left brachial plexus was normal. The 3 month follow-up EMG performed showed the persistence of long latency and low amplitude in the left phrenic nerve, in relation to the opposite side.

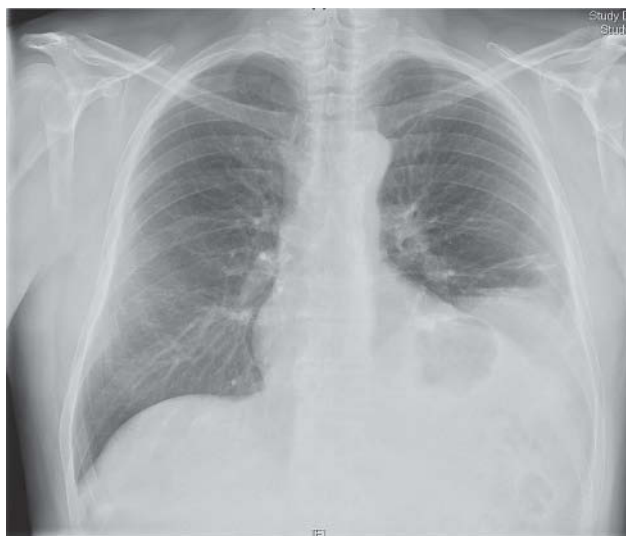

Figure 1. PA chest x-ray showing elevation of the left hemidiaphragm.

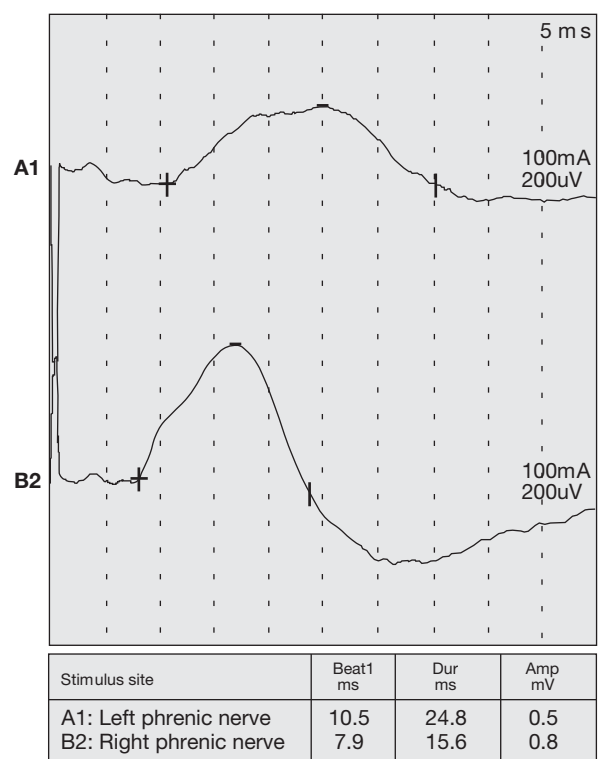


Figure 2. The conduction velocity shows left phrenic nerve response (A1) with increased latency and decreased amplitude. Normal response of the right phrenic nerve (B2).

Discussion

Amyotrophic neuralgia is an inflammatory and idiopathic neuropathy characterised by the acute start of neuropathic pain, followed by weakness and atrophy of the affected musculature. It may also progress with sensation deficiencies together with paresthesia and/or hypoesthesia. The disease was first described in 1948 as an affection of only the brachial plexus and was known as Parsonage-Turner syndrome⁴ or brachial neuritis, brachial plexus neuropathy or acute brachial radiculitis. Later on, concomitant or isolated neuropathy of other peripheral nerves was observed. Concomitant involvement of the phrenic nerve is rare in NA,⁵ and bilateral or isolated unilateral phrenic neuropathy is even more rare.^{6,7}

Our patient presented with a neuralgic pain in the left hemithorax with isolated homolateral diaphragmatic involvement, which was confirmed by EMG. The absence of a specific cause after carrying out an exhaustive study and the neuropathic pain are the criteria for diagnosis of NA with phrenic nerve involvement.^{8,9}

In the study by Tsao et al.,¹⁰ among 33 patients with idiopathic phrenic paralysis, 7 NA cases reported involvement of another motor nerve typical of NA and 10 cases had isolated involvement of the phrenic nerve.

The incidence of NA is 2-3 per 100,000 people per year, with a peak incidence between the third and fifth decades. It predominates in men, with a 2-4:1 ratio. A dominant autosomic hereditary variant has been described (hereditary NA), which predisposes patients to recurrent peripheral neuropathic pain. Genetic studies¹¹ reveal a defect in chromosome 17q24-q25. Extrabrachial involvement is more common (56%) in the hereditary subtype than in the sporadic one (17%). Although the aetiology is unknown, there is mention of an autoimmune pathogenic mechanism that would lead to focal demyelination or axonal degeneration.¹²

The typical profile of NA is the sudden onset of severe pain in the shoulder, followed by weakness and atrophy of muscles innervated by C5-C7.^{4,13} There may be radiation to the scapula, and neuropathic pain is greatest at night.¹⁴ The involvement of other peripheral nerves leads to various clinical syndromes.¹⁵⁻¹⁷ The duration of the pain is approximately 30 days and in one third of patients chronic pain persists, resistant to the usual painkillers. In our case, the intense, stinging pain triggered by exertion of the left arm persisted for 6 months.

The diagnosis is very difficult if there is no muscular weakness in the upper extremities, which is typical of the disease. Suspicion is based on the presence of acute neuropathic pain in the shoulders and upper extremities or unexplained diaphragmatic paralysis. It is necessary to rule out common causes of peripheral neuropathy such as infection, autoimmune diseases, diabetes and vasculitis. The EMG with a nerve conduction study can reveal patchy conduction blockages and can help to rule out monoradiculopathy or entrapment neuropathy. In case of involvement of the brachial plexus, the cervical MRI is usually normal, except for T2 hyperintensity. Phrenic nerve involvement may also be suspected from the lung function data, which show restriction and reduction in airway pressures, with preserved functional residual capacity. Expiratory reserve volume and maximal expiratory pressure are generally preserved in isolated phrenic paralysis. The decrease in expiratory reserve volume suggests nerve involvement of accessory muscles, and in this case may present with significant dyspnea that is unusual in isolated unilateral phrenic nerve paralysis.

Management is usually conservative and consists of analgesics, physiotherapy, and patient relaxation. Corticoids are used to reduce pain, but show no influence whatsoever in the progression of the disease. In patients with great dyspnea of the diaphragm may find relief of symptoms,¹⁸ but it should take a minimum of 2 years, since late recoveries are observed.

The prognosis of typical NA without phrenic nerve involvement is good,¹³ with complete resolution in more than 90% of cases after 3 years.⁶ However, 3 of the 4 cases with phrenic nerve involvement reported by Tsairis et al.⁶ still had immobile hemidiaphragms in the fluoroscopy 2½-4 years after the onset of the disease. A number of authors^{5,7,19,20} agree that phrenic nerve recovery takes longer than the nerves of the extremities, up to three years.

In conclusion, we here highlight the importance of suspicion of NA as a cause of painful unilateral diaphragmatic paralysis, because

the diagnosis is mainly clinical and imaging studies only serve to exclude other causes of unilateral phrenic nerve paralysis.

References

- Gibson GJ. Diaphragmatic paresis: pathophysiology, clinical features, and investigation. *Thorax*. 1989;44:960-70.
- Carretero Gracia JA, Álvarez Alegret R, Peñalver Cuesta JC. Chronic sclerosing mediastinitis: infrequent cause of unilateral diaphragmatic paralysis. *Arch Bronconeumol*. 2000;36:417-9.
- Laguery A, Ellie E, Saintarailles J, Marthan R, Barat M, Julien J. Unilateral diaphragmatic paralysis: an electrophysiological study. *J Neurol Neurosurg Psychiatry*. 1992;55:316-8.
- Parsonage MJ, Turner JW. Neuralgia amyotrophy, the shoulder girdle syndrome. *Lancet*. 1948;i:973-8.
- Lahrmann H, Grisold W, Authier FJ, Zifko UA. Neuralgic amyotrophy with phrenic nerve involvement. *Muscle Nerve*. 1999;22:437-42.
- Tsairis P, Dyck PJ, Mulder DW. Natural history of brachial plexus neuropathy. *Arch Neurol*. 1972;27:109-17.
- Gregory RP, Loh L, Newsom-Davis J. Recurrent isolated alternating phrenic nerve palsies: a variant of brachial neuritis. *Thorax*. 1990;45:420-1.
- Nardone R, Bernhart H, Pozzera A, Taddie M, Tezzon F. Respiratory weakness in neuralgic amyotrophy: report of two cases with phrenic nerve involvement. *Neurol Sci*. 2000;21:177-81.
- Lin PT, Andersson PB, Distad BJ, Barohn RJ, Cho SC, So YT. Bilateral isolated phrenic neuropathy causing painless bilateral diaphragmatic paralysis. *Neurology*. 2005;65:1499-501.
- Tsao BE, Ostroskiy DA, Wilbourn AJ, Shields RW. Phrenic neuropathy due to neuralgia amyotrophy. *Neurology*. 2006;66:1582-4.
- Pellegrino JE, Rebbeck TR, Brown MJ, Bird TD, Chance PF. Mapping of hereditary neuralgic amyotrophy (familial brachial plexus neuropathy) to distal chromosome 17Q. *Neurology*. 1996;46:1128-32.
- Sierra A, Prat J, Bas J, Romeu A, Montero J, Matos JAM, et al. Blood lymphocytes are sensitized to brachial plexus nerves in patients with neuralgic amyotrophy. *Acta Neurol Scand*. 1991;83:183-6.
- Turner J, Parsonage M. Neuralgic amyotrophy (paralytic brachial neuritis) with special reference to prognosis. *Lancet*. 1957;2:209-12.
- Helms CA, Martínez S, Speer KP. Acute brachial neuritis (Parsonage-Turner syndrome): MR imaging appearance-report of three cases. *Radiology*. 1998;207:255-9.
- England JD, Summer AJ. Neuralgic amyotrophy: an increasingly diverse entity. *Muscle Nerve*. 1987;10:60-8.
- Pierre PA, Laterre CE, Van den Bergh PY. Neuralgia amyotrophy with involvement of cranial nerves IX, X, XI and XII. *Muscle Nerve*. 1990;13:704-7.
- England JD. The variations of neuralgic amyotrophy. *Muscle Nerve*. 1999;22:435-6.
- Quintana González JI, Carbajo M, Rodríguez J, Ortiz de Saracho J, Guzmán Davila G, Castro Deza Sanz R. Unilateral diaphragmatic paralysis treated successfully by plication. *Arch Bronconeumol*. 2001;37:401-3.
- Kalluri M, Huggins JT, Strange C. A 56-year-old woman with arm pain, dyspnea, and an elevated diaphragm. *Chest*. 2008;133:296-9.
- Mulvey D, Aquilina R, Elliot M, Moxham J, Green M. Diaphragmatic dysfunction in neuralgic amyotrophy: an electrophysiologic evaluation of 16 patients presenting with dyspnea. *Am Rev Respir Dis*. 1993;147:66-71.