

## Letters to the Editor

### Bronchial Atresia Together with a Gonadal Teratoma: What is the Relationship?

#### *Atresia bronquial junto a teratoma gonadal. ¿Cuál es la relación?*

To the Editor:

Teratomas being germinal tumours classified as gonadal and extragonadal,<sup>1</sup> in the reviewed medical literature only cases are published in which these last are associated with congenital anomalies (muscular and skeletal and heart alterations, rectal stenosis and microcephaly) with a frequency of 9 to 26%.<sup>2</sup>

We present here the first case in which a gonadal teratoma can be associated with a malformation, concretely with bronchial atresia.

Woman of 33 years of age sent for a presurgical assessment of pulmonary risk for laparoscopic abdominal surgery for a left ovarian tumour, a casual finding during her first gynaecological exam. No toxic habits or medical/surgical history of interest, the patient was asymptomatic and her physical, analytical and functional exams were within normal limits, except for the fact that in her chest X-ray in the anteroposterior and lateral projections a polylobar image was seen in the right lower lobe (Fig. 1). Tumour markers were negative. Using a chest computed tomography with contrast (Fig. it was possible to see a 6.5?2.2 cm lesion, with an irregular shape, with several glove-finger prolongations, located in segment 10, accompanied by a distal segmental area of radiolucency.

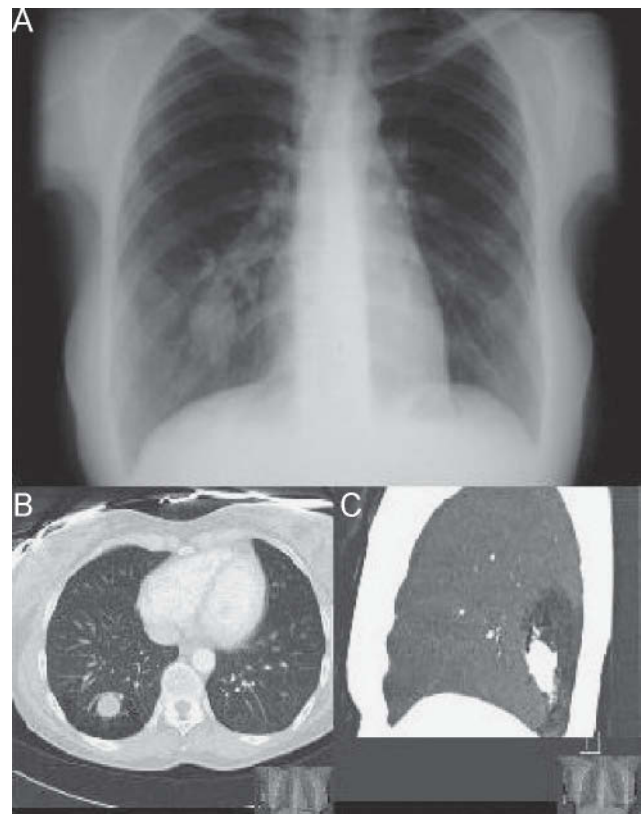
The patient underwent laparoscopic excision of the left adnexus (ovary and Fallopian tube) and the histological study was compatible with a mature teratoma- germinal cell neoplasias constitute 10-20% of all ovarian tumours.<sup>1</sup>

Subsequently, the study was completed by performing a bronchofibroscopy that did not show endobronchial lesions or anomalies in bronchial segments up to the limits accessed using this technique. According therefore to this data the patient was diagnosed with congenital bronchial atresia with distal bronchocele of right segment 10.

Bronchial atresia is an alteration characterized by focal obliteration of a part of the bronchus, which causes an accumulation of secretions and a bronchocele with absence of ventilation of the corresponding distal pulmonary area (which is seen radiologically as hyperlucent).<sup>3</sup> Approximately 50% of the patients are asymptomatic at the time of diagnosis, and this condition is more frequent in men (2:1), and usually affects young people.<sup>4</sup> Chest computed tomography with contrast is diagnostic,<sup>3</sup> and makes it possible to differentiate between congenital anomalies, bronchoectasias and other types of bronchial obstruction. Treatment of asymptomatic patients is conservative, and surgery is only necessary if there should be symptoms (such as recurrent respiratory infections, chronic cough or dyspnea).<sup>3</sup>

After 2 years of follow-up, the patient continues asymptomatic and without changes on X-ray, therefore we have continued to manage her conservatively.

The strangeness of our case lies in that we simultaneously find 2 entities (gonadal teratoma and bronchial atresia) that, in spite of their anatomical distance, could have a common origin in chromosome alterations which are not yet completely characterized, such as a loss of homogeneity of chromosome 18 (usually expressed by the acronym LOH. 18). It is known that chromosome 18 trisomy is related to lung segmentation anomalies.<sup>5</sup> Recently the importance of locus 18q21 in the direction of axon extension during embryonic development has been established; a deletion at this level would generate a general predisposition to the development of tumours (among these ovarian tumours, with an incidence of 9-12%, in the context of Lynch syndrome).<sup>6</sup> Every day the human genome is better known, and it is probable that in the not very distant future a relationship will be found between these 2 alterations.



**Figure 1.** A) Chest X-ray (posteroanterior projection): mass in the right lower lobe. B) and C) chest CT with contrast (axial section and sagittal section): Polylobar lesion in right segment 10 with distal segmental radiolucency.

## References

- Morillo M, Martín F, Vidal F, Jofré JJ, González E, Carrasco S. Teratoma maduro de ovario. Estudio clínico-patológico de 112 casos y revisión de la literatura. Actual obstet ginecol. 2001;XIII:249-53.
- Sancak R, Dagdemir A, Tasdemir HA, Kucukoduk S, Baysal K. A thoracic Spinal Cord Teratoma Associated with Taussing-Bing Anomaly in a Newborn. Teratology. 2001;63:77-8.
- Yoldi M, Flórez S, Alegre N. Atresia bronquial de localización excepcional. Arch Bronconeumol. 2001;37:514-5.
- Kinsella D, Sissons G, Williams MP. The radiological imaging of bronchial atresia. Br J Radiol. 1992;65:681-5.
- Baguena R, Marin J, Calpe JL, Servera E, Pérez D, Domínguez A. Las hipoplasias pulmonares. Med Esp. 1985;84:17-22.
- Nussbaum RL, MacInnes RR, Willard HF. Genética en Medicina. 5<sup>th</sup> Ed. Masson: Thompson & Thompson; 2009.

Lirios Sacristán Bou \*, Concepción Martín Serrano and Santiago Romero Candeira

Servicio de Neumología, Hospital General Universitario de Alicante, Alicante, Spain

\*Corresponding author.

E-mail address: lirios\_sacristan@yahoo.es (L. Sacristán Bou).

## Acrometastasis Due to Lung Cancer. A Case Presentation

### Acrometástasis por cáncer de pulmón. A propósito de un caso

To the Editor:

Acrometastasis are defined as malignant secondary lesions of the bones located in the hands and/or feet.<sup>1</sup> Only between 0.007 and 0.3% of patients with bone metastasis develop acrometastasis. Usually acrometastasis present as pre-terminal events in the context of disseminated cancer.<sup>1</sup> As a result, they may be of importance as the first manifestation of an occult cancer, or can simulate and be treated improperly as if they were other skeletal diseases.

A 63-year-old man. Heavy smoker, hospitalised for haemoptysis. Had a history of moderately differentiated squamous cell cancer in a metastatic supraclavicular lymph node with an unknown primary tumour 2 years before. A computed tomography revealed a large hilar mass with a peripheral nodular lesion in the right lung. Shortly afterwards the patient presented a painful tumour in the distal phalange of the left thumb (Fig. 1). Endobronchial and finger biopsies confirmed a moderately differentiated squamous cell carcinoma. An X-ray study revealed an osteolytic lesion of the distal phalange of the thumb. Amputation was performed at the interphalangeal joint. Later other metastasis appeared, and the patient died 6 months later.

In most patients with acrometastasis the lung is involved (it is the most common origin of hand metastasis in 40-47% of cases)<sup>2</sup>, possibly due to its capacity for propagation by the systemic route. There is an association between squamous cell cancer and the development of acrometastasis.<sup>3</sup> The right hand is more often affected than the left. Metastasis of the distal phalange has been reported in patients with pulmonary osteoarthropathy.<sup>1</sup> This finding could be related to the local blood-supply flow. Clinically they present with local pain, erythema and oedema that simulate an acute infection or a pathological fracture.<sup>4</sup> Frequently, they are initially confused with benign processes, such as hangnail, trauma, rheumatoid arthritis, osteomyelitis or gout. X-ray findings show, in almost all cases, lytic lesions without periosteal reaction, and without joint involvement. These are important signs when carrying out a radiological differential diagnosis with primary malignant tumours and osteomyelitis.<sup>1,5</sup> Needle puncture aspiration or biopsy are the most effective methods for diagnosis.

Acrometastasis normally appear during a very extended disease, and suggest an ominous prognosis. The treatments used for palliation include systemic chemotherapy, curettage, amputation of solitary lesions that grow in distal phalanges and short bones when there is no response to analgesia and radiotherapy (reserved for multiple lesions). Treatment is aimed at relieving pain and restoring function.<sup>6</sup> Due to the deceptive characteristics mentioned above, many cases are not initially diagnosed. Persistence of symptoms, lack of response



Figure 1. Acrometastasis of the left thumb.