



Case Report

Hypersensitivity Pneumonitis after Exposure to *Candida* spp

Carlos Serrano^a, Alfonso Torrego^b, Alfonso Loosli^c, Antonio Valero^{c,*} and César Picado^c

^aUnidad de Alergia, Hospital Fundación Valle del Lili, Cali, Colombia

^bServicio de Neumología, Hospital de la Santa Creu i Sant Pau, Barcelona, Spain

^cServicio de Neumología y Alergia Respiratoria, Institut del Tòrax, Hospital Clínic, Barcelona, Spain

ARTICLE INFO

Article history:

Received August 28, 2009

Accepted August 29, 2009

Keywords:

Hypersensitivity pneumonitis

Candida albicans

Lung disease

Palabras clave:

Neumonitis por hipersensibilidad

Candida albicans

Enfermedad pulmonar

ABSTRACT

Hypersensitivity pneumonitis (HP) is a lung disease caused by heavy and recurrent inhalation of antigens. We describe the case of a patient with HP caused by domestic exposure to *Candida* spp. The diagnosis was made by taking into consideration the clinical presentation, exposure history, radiological findings, bronchoalveolar lavage, lung function and the immuno-allergy study. The diagnosis was definitively confirmed by performing a specific bronchial provocation test. It has been shown that there is cross-reactivity between different *Candida* species, and despite making the diagnosis in this case with *Candida albicans*, we were unable to define exactly which species was responsible for the HP.

© 2009 SEPAR. Published by Elsevier España, S.L. All rights reserved.

Neumonitis por hipersensibilidad tras exposición a *Candida* spp

RESUMEN

La neumonitis por hipersensibilidad (NH) es una enfermedad pulmonar debida a la exposición a diferentes antígenos por vía inhalada de forma intensa y recurrente. Describimos el caso de un paciente con NH por exposición doméstica a *Candida* spp. Para llegar al diagnóstico se consideraron la presentación clínica, el antecedente de exposición, los hallazgos radiológicos, el lavado broncoalveolar, la función pulmonar y el estudio inmunológico, siendo confirmado de forma definitiva tras la realización de la provocación bronquial específica. Se ha demostrado reactividad cruzada entre diferentes especies de *Candida* y, a pesar de realizar el diagnóstico en este caso con *Candida albicans*, no podemos definir con exactitud qué especie es la responsable de la NH.

© 2009 SEPAR. Publicado por Elsevier España, S.L. Todos los derechos reservados.

Introduction

Hypersensitivity pneumonitis (HP), also known as extrinsic allergic alveolitis, EAA, is a pulmonary disease caused by exposure to different antigens through intense, recurring inhalation. Traditionally, the clinical presentation of the disease has been divided into 3 types: acute, subacute and chronic, which are determined based on intensity, frequency and duration of exposure to the antigen.¹

Diagnosis is based on a history of symptoms, radiology pattern of the computed tomography scan (CT), bronchoalveolar lavage lung

function tests, bronchial provocation and immunological tests. The presence of precipitins and positive skin tests to the suspected antigen are useful but not diagnostically significant. Duplication of the symptom pattern by specific bronchial provocation is considered the definitive test for diagnosis.²

Candida albicans is a common saprophyte in the upper respiratory tract and rarely causes lung disease. Indeed, lung infections caused by *Candida* occur only in small children, the elderly and immunocompromised patients.

This disease has been described in connection with exposure to *Candida* and other moulds in the use of ultrasonic humidifiers,³⁻⁵ and it is also caused by haematogenic proliferation of the *Candida* antigen in the intestinal mucous.^{6,7} Few cases of HP have been reported where *Candida* was identified as the causal agent,^{8,9} in spite of the

*Corresponding author.

E-mail address: valero@clinic.ub.es (A. Valero).

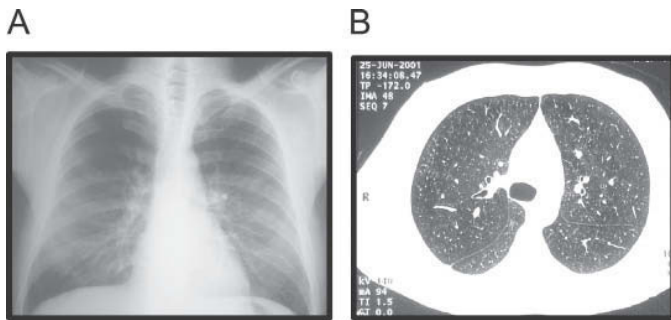


Figure 1. Radiology pattern: interstitial diffuse infiltrate in the simple chest X-ray (A), and micronodular infiltrate with a ground glass opaque background in the high resolution chest CT scan (B).

difficulty in precisely defining the species of *Candida* responsible for disease.⁸

We describe in this article a case of HP secondary to domestic exposure *Candida*.

Clinical Observation

39 year old male with a history of allergic rhinitis and mild intermittent asthma, smoker (10 pack/year), employed in the automotive sector. Described recurring episodes of dry cough, progressive shortness of breath (even during moderate exertion), asthenia, arthralgia, myalgia and fever, for which on various occasions he had been visited the emergency services, where he had presented with symptoms of fever (39–40° C) with mild bibasilar sibilant rales, requiring hospitalisation on one of these visits.

The patient said that the onset of his symptoms coincided with the appearance of damp stains in his bathroom caused by a drain leakage. He had observed that the symptoms improved when he was temporarily living elsewhere. He brought in samples from his home, taken from the damp patches in the bathroom. This material was cultured and *Alternaria* spp., *Fusarium* spp., *Penicillium* spp., *Candida* spp. and *Aspergillus* spp were identified.

Among the complementary tests performed, serology, haemoculture and mycobacterium culture were negative. The blood count was normal at 12,500 leukocytes (68% neutrophils), as well as the biochemical and coagulation parameters.

As for respiratory function tests, the results of the forced spirometry were as follows: forced expiratory volume in the first second at 101%, forced vital capacity at 98%, index at 82 and non significant bronchodilator test. In the plethysmography test total lung capacity was at 97%, residual volume of 98%, inhalation capacity was 93% and flow volume was 102%. Carbon monoxide transfer factor was 73%, and the relationship between it and the alveolar volume was 71%. The results of the arterial blood gas (ABG) test (21%) were: arterial oxygen pressure at 80mmHg, arterial carbon dioxide pressure 39.5mmHg and 7.39pH

The X-ray and CT scan showed a diffuse-interstitial pattern, and an opaque ground glass image was seen on the CT scan (fig. 1).

A fibrobronchoscopy and a bronchoalveolar wash were performed. The BAL differential cell count was the following: 42% macrophages (normal: 80–90%) 80–90%, 29% lymphocytes (normal ≤ 12%) and 28% neutrophils (normal ≤ 3%).

Regarding the immunological study, intradermal tests and precipitin determination tests were carried out with *Penicillium notatum*, *Aspergillus fumigatus*, *Cladosporium herbarum*, *Alternaria alternata* and *Micropolyspora faeni*, and proved positive only for *Candida* (fig. 2) 2). The test for immunoglobulin G (IgG) with 3 species of *Candida* (*C. albicans albicans*, *C. krusei* y *C. parapsilosis*) was positive.

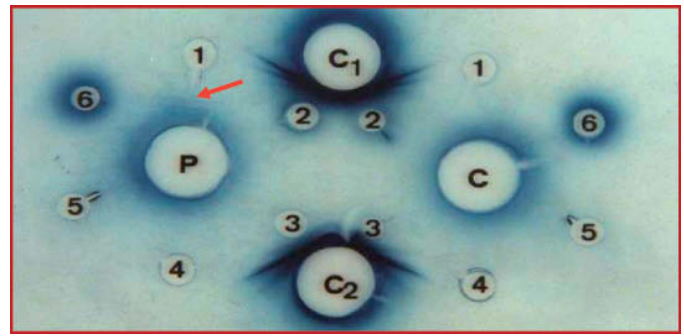


Figure 2. Results of the precipitin tests against different moulds. In order to study the presence of antibodies in the patient's serum capable of producing precipitin immunocomplexes with proteins present in the extracts, a double diffusion technique was used. Note the positive band, faint but significant, (arrow) for *Candida albicans*. C: negative control serum (mix from 2 non allergic people); C1: anti-*Penicillium notatum* rabbit serum; C2: anti-*Aspergillus fumigatus* rabbit serum; P: Patient; 1: *Candida albicans* extract; 2: *Penicillium notatum* extract; 3: *Aspergillus fumigatus* extract; 4: *Cladosporium herbarum* extract; 5: *Alternaria alternata* extract; 6: *Micropolyspora faeni* extract.

A bronchial provocation test was ordered for *C. Albicans*.¹⁰ Nine hours after nebulization with the extract (1 mg/mL) the patient developed respiratory symptoms (cough, dyspnoea, crepitant rales), fever, leukocytosis, radiology infiltrates and functional respiratory deterioration (forced expiratory volume in the first second passed from 114 to 67%, forced vital capacity from 109 to 68% and oxygen arterial pressure from 87 to 64mmHg), with complete recovery 12 hours later.

Discussion

We have described a case of HP caused by *Candida* in which the diagnosis was carried out by means of skin tests, precipitin tests, X-ray study, bronchoalveolar lavage and finally, a specific bronchial provocation test. The patient temporarily changed residence while the leak in the bathroom was being fixed, and since his return has remained symptom free.

Some authors consider skin tests ambiguous because their results are inconsistent,¹¹ while others consider them as diagnostically significant.¹² In this specific case, we consider that the intradermal tests positive for *Candida* do not prove helpful in diagnosis, since *C. albicans* is an ubiquitous mould in humans and candidine, an extract obtained from *C. albicans* that is used to determine cell immunity, is highly prevalent throughout the population.

Precipitin reactions are very sensitive, but have low specificity. They are detected in 40–50% of people who have suffered exposure but are asymptomatic, which indicates that their presence is not necessarily related to disease.¹¹ Our patient was positive to precipitins for *Candida* spp., but not for other moulds that were present in the culture obtained from the patient's bathroom.

Although the skin tests, precipitin determination and the provocation protocol were carried out with *C. albicans* extract and were clearly positive, the presence of specific IgG antibodies to 2 other species of *Candida* shows that there is cross-reaction between them, meaning that we cannot determine which species of *Candida* is responsible for the HP in this case.

Given the infrequency of *Candida* as the cause of HP and the possible legal repercussions of this case, we considered the provocation test necessary in order to precisely define the antigen source that triggered the HP.

To conclude, we describe an unusual case of HP resulting from exposure to *Candida* spp. in the home, which was proved through a

bronchial provocation test. The presence of IgG antibodies against several species of *Candida* indicates the existence of a cross-reaction between them.

Acknowledgements

To Bartolomé Borja from the R&D Department of Bial-Aristegui, Bilbao, Spain, for the precipitin tests used in this case.

To Jorge Martínez from the Department of Immunology, Microbiology and Parasitology of the School of Farmacia (Universidad del País Vasco, Vitoria, Spain), for the immunoglobulin G tests against the various species of *Candida*.

References

1. Fink JN, Ortega HG, Reynolds HY, Cormier YF, Fan LL, Franks TJ, et al. Needs and opportunities for research in hypersensitivity pneumonitis. *Am J Respir Crit Care Med.* 2005;171:792-8.
2. Patel AM, Ryu JH, Reed CE. Hypersensitivity pneumonitis: current concepts and future questions. *J Allergy Clin Immunol.* 2001;108:661-70.
3. Suda T, Sato A, Ida M, Gemma H, Hayakawa H, Chida K. Hypersensitivity pneumonitis associated with home ultrasonic humidifiers. *Chest.* 1995;107:711-7.
4. Álvarez-Fernández JA, Quince S, Calleja JL, Cuevas M, Losada E. Hypersensitivity pneumonitis due to an ultrasonic humidifier. *Allergy.* 1998;53:210-2.
5. Ordoqui E, Orta M, Aranzábal A, Martínez MC, Idoate F, Trujillo MJ, et al. Alveolitis alérgica extrínseca por exposición a un humidificador ultrasónico. *Alergol Inmunol Clin.* 2000;15:400-4.
6. Schreiber J, Struben C, Rosahl W, Amthor M. Hypersensitivity alveolitis induced by endogenous candida species. *Eur J Med Res.* 2000;5:126.
7. Schreiber J, Goring HD, Struben C, Rosahl W, Lakotta W, Amthor M. Interstitial lung disease induced by endogenous *Candida albicans*. *Eur J Med Res.* 2001;6:71-4.
8. Ando M, Yoshida H, Nakashima H, Sugihara Y, Kashida Y. Role of *Candida albicans* in chronic hypersensitivity pneumonitis. *Chest.* 1994;105:317-8.
9. González-Mancebo E, Díez-Gómez ML, Pulido Z, Alfaya T, León F. Swimming-pool pneumonitis. *Allergy.* 2000;55:782-3.
10. Hinojosa M, Fraj J, De la Hoz B, Alcázar R, Sueiro A. Hypersensitivity pneumonitis in workers exposed to esparto grass (*stipa tenacissima*) fibers. *J Allergy Clin Immunol.* 1996;98:985-91.
11. Lacasse Y, Selman M, Costabel U, Dalphin JC, Ando M, Morell F, et al. Clinical diagnosis of hypersensitivity pneumonitis. *Am J Respir Crit Care Med.* 2003;168:952-8.
12. Morell F. Usefulness of specific skin test in the diagnosis of hypersensitivity pneumonitis. *J Allergy Clin Immunol.* 2002;110:939.