



Case Report

Rapid Resolution of Nitrofurantoin-Induced Interstitial Lung Disease

Miguel Ángel Núñez Viejo,^a Ana Fernández Montes,^a Javier Velasco Montes,^a José Javier Gómez-Román,^b Carmen García Ibarbia,^a and José Luis Hernández Hernández^a

^aDepartamento de Medicina Interna, Hospital Universitario Marqués de Valdecilla, Universidad de Cantabria, Santander, Spain

^bDepartamento de Anatomía Patológica, Hospital Universitario Marqués de Valdecilla, Universidad de Cantabria, Santander, Spain

ARTICLE INFO

Article history:

Received April 26, 2008

Accepted May 29, 2008

Available online March 31, 2009

Keywords:

Nitrofurantoin

Interstitial lung disease

Transbronchial biopsy

Corticosteroids

Palabras clave:

Nitrofurantoína

Enfermedad pulmonar intersticial

Biopsia transbronquial

Corticoides

ABSTRACT

We report the case of a 40-year-old woman diagnosed with interstitial lung disease due to long-term nitrofurantoin therapy. Despite severely distorted bronchiolar architecture and honeycombing confirmed by computed tomography of the thorax, transbronchial biopsy showed a pattern of acute/subacute interstitial pneumonitis and the symptoms and radiographic findings disappeared within 1 month after administration of prednisone. This case shows that nitrofurantoin-induced lung disease may run a benign course and respond favorably to corticosteroids, even when there is radiographic evidence of established lung fibrosis. Transbronchial biopsy might be useful for assessing the reversibility of pulmonary lesions associated with nitrofurantoin.

© 2008 SEPAR. Published by Elsevier España, S.L. All rights reserved.

Nitrofurantoína y enfermedad pulmonar intersticial de rápida resolución

RESUMEN

Presentamos el caso de una mujer de 40 años diagnosticada de enfermedad pulmonar intersticial secundaria a la administración crónica de nitrofurantoína. A pesar de la grave desestructuración de la arquitectura bronquiolar y una tomografía computarizada de tórax que confirmó la presencia de panalización, la biopsia transbronquial mostró un patrón de neumonitis intersticial aguda-subaguda y el cuadro clínico y radiológico se resolvió en el plazo de un mes tras la administración de prednisona. Este caso pone de manifiesto que la enfermedad pulmonar inducida por nitrofurantoína puede llegar a ser una entidad benigna con respuesta favorable a los corticoides, incluso en el caso de que haya datos radiológicos de fibrosis pulmonar establecida. La biopsia transbronquial podría ser una prueba útil para evaluar la reversibilidad de las lesiones pulmonares asociadas a la nitrofurantoína.

© 2008 SEPAR. Publicado por Elsevier España, S.L. Todos los derechos reservados.

Introduction

Nitrofurantoin-induced pulmonary toxicity was first described in 1957, and a broad spectrum of acute and chronic forms of presentation have since been reported.¹⁻³ Chronic pulmonary reactions of this type usually occur in elderly patients; onset is often insidious and interstitial lung disease and fibrosis may develop. High-resolution computed tomography (HRCT) scans of patients with interstitial pneumonia are characterized by a predominantly reticular pattern,

which is often related to the presence of established pulmonary fibrosis, particularly when associated with distorted parenchymal architecture.^{4,5}

We report the case of a woman on long-term nitrofurantoin therapy who developed interstitial pneumonitis with radiographic findings suggestive of pulmonary fibrosis. The condition resolved rapidly after administration of prednisone. We also discuss the prognostic value of transbronchial biopsy in this clinical context.

Case Description

A 48-year-old woman was admitted for progressively worsening dyspnea, even on minimal exertion, as well as dry cough, nighttime

*Corresponding author.

E-mail address: manuvi2004@hotmail.com (M.A. Núñez Viejo).

sweating, asthenia, and a weight loss of 3 kg in the past month. The patient was a nonsmoker and had been taking nitrofurantoin (50 mg/d) continually for the past 11 months as prophylaxis for recurrent urinary tract infections. She was a teacher, but was not giving classes at the time. She had not been exposed to toxic substances, was not taking any other medications, and denied drug abuse.

The physical examination revealed tachypnea and tachycardia, but there were no signs of cyanosis or clubbing. Abundant Velcro-like crackles were audible in the lower two-thirds of both lungs. All other findings of the physical examination were normal.

Arterial blood gas analysis without oxygen showed a pH of 7.44, PaO₂ of 65 mm Hg, PaCO₂ of 36 mm Hg, and bicarbonate of 25 mEq. The erythrocyte sedimentation rate was 42 mm/h, and lactate dehydrogenase was elevated (682 U/L). The remaining hematology and biochemical parameters were within normal limits. Antinuclear antibodies were positive at a titer of 1:640 and showed a speckled staining pattern. All other immunologic tests (rheumatoid factor, anti-double-stranded DNA antibodies, antineutrophil cytoplasmic antibodies, total hemolytic complement [CH₅₀], C3 and C4 complements, and serum immunoglobulin

and cryoglobulin levels) were negative or normal. The microbiological studies and the Mantoux test were also negative.

The chest radiograph showed a diffuse reticular pattern that mainly affected the middle lobe and both lower lobes. HRCT showed diffuse interstitial thickening, as well as peribronchial thickening with patchy areas of ground-glass opacities. The distorted bronchiolar architecture, bands of fibrosis, and incipient honeycombing pattern affected both lung bases (Figure 1A). No pleural effusion or enlarged lymph nodes were observed. The patient was unable to cooperate in the lung function tests because of an anxiety attack.

Nitrofurantoin was withdrawn on admission but the patient's condition worsened over the following days and radiographic follow-up confirmed progressive deterioration of the pulmonary infiltrates.

The macroscopic findings of the fiberoptic bronchoscopy were normal and bronchoalveolar lavage fluid analysis showed 40% macrophages, 20% lymphocytes, 10% neutrophils, and 30% eosinophils. Pathologic analysis of a transbronchial biopsy specimen taken during the bronchoscopy showed partially distorted pulmonary architecture with focal areas of fibrosis and a considerable chronic

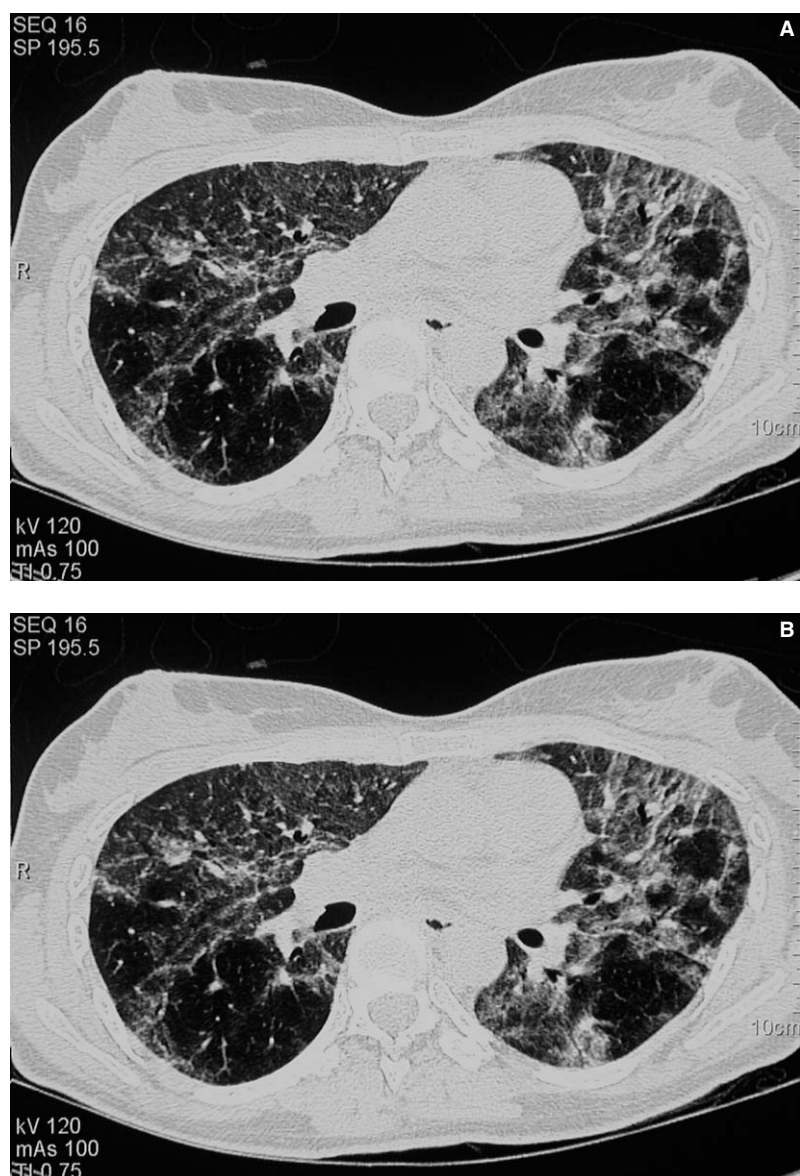

Figure 1. A, high resolution computed tomography (HRCT) scan revealing distorted bronchial architecture, bands of fibrosis, and incipient honeycombing in both lung bases. B, follow-up HRCT scan showing complete resolution of the pulmonary lesions.

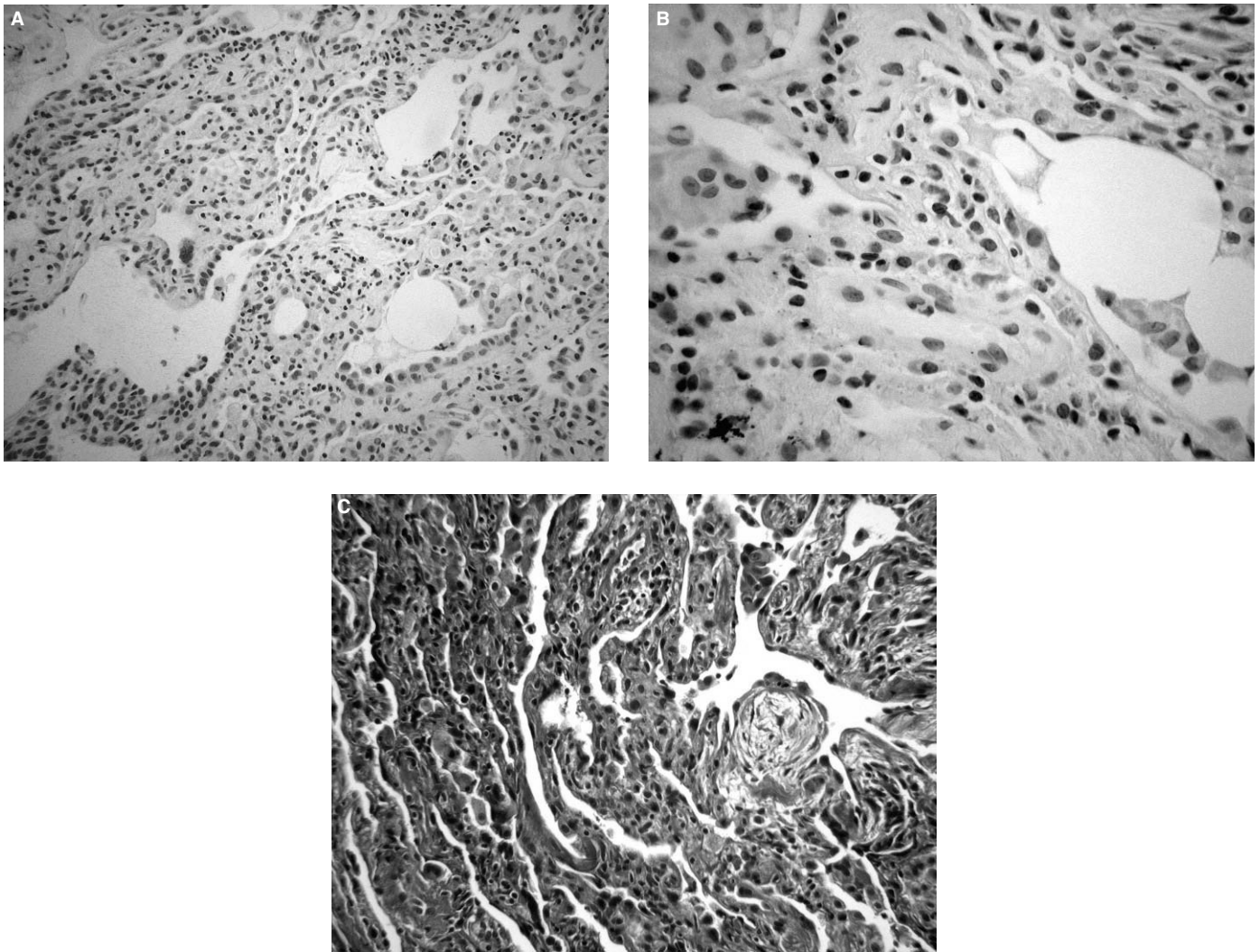


Figure 2. A, partial loss of pulmonary architecture and considerable interstitial inflammation (hematoxylin-eosin, $\times 80$). B, interstitial infiltrate composed of lymphocytes, plasma cells, and numerous eosinophils (hematoxylin-eosin, $\times 160$). C, elastin stain showing proliferation of mature fibroblasts with minimal collagen deposits (Masson trichrome, $\times 80$).

lymphoid infiltrate, as well as eosinophils, plasma cells, and various areas of fibroblast proliferation (Figure 2).

Based on the findings, oral prednisone therapy (1 mg/kg/d) was started, and the patient's respiratory symptoms and parameters improved significantly within a few days. At 25 days postadmission, lung sounds were normal and HRCT confirmed complete resolution of the pulmonary infiltrates and honeycombing (Figure 1B). The patient was discharged with prednisone therapy, to be tapered down. One year later, at the time of writing, she was asymptomatic, all respiratory function tests were normal, and no radiographic evidence of recurrence had been detected.

Discussion

Prolonged use of nitrofurantoin can induce interstitial lung disease and irreversible fibrosis.¹⁻⁴ Lung involvement is common in elderly patients on long-term nitrofurantoin therapy as prophylaxis for recurrent urinary tract infections. Histologically, most cases show a pattern that suggests chronic interstitial pneumonia, which can occasionally be difficult to distinguish from other more common types of interstitial pneumonia. The presence of eosinophilia is widely described in chronic forms of nitrofurantoin-induced toxicity, and its finding in the lung biopsy could be a marker of lesion reversibility, along with the absence of massive fibrosis.⁵

Around 10% to 30% of patients show some kind of response to corticosteroids, usually after 2 or 3 months of treatment, although complete remissions are rare.¹⁻⁴ Two cases of radiographic resolution of established, apparently irreversible pulmonary fibrosis in elderly patients who had received nitrofurantoin therapy for 3 years have been recently described.⁷ However, a histologic study to confirm the diagnosis was not performed in either patient, unlike our case.

Our patient presented radiographic evidence that suggested irreversible pulmonary fibrosis (honeycombing pattern), although the biopsy showed predominantly acute/subacute changes. In fact, the patient's clinical symptoms and radiographic findings resolved rapidly and unexpectedly within 25 days, following corticosteroid therapy. To the best of our knowledge, this is the first patient in whom a complete pathologic study has confirmed rapid recovery from severe nitrofurantoin-induced interstitial lung disease.

In conclusion, pulmonary function parameters should be closely monitored in patients on long-term nitrofurantoin therapy, and the drug should be discontinued at the first sign of any abnormalities. Transbronchial biopsy is a useful method for detecting the presence or absence of fibrotic response and, consequently, for assessing the reversibility of interstitial lesions. Clinical improvement tends to be rapid, but complete radiographic resolution of the interstitial disease may not be observed. Corticosteroid treatment should be initiated as

soon as possible because radiographic changes caused by secondary to pulmonary fibrosis can improve or even resolve completely, as was the case in our patient.

References

1. Willcox PA, Maze SS, Sandler M, Benatar SR. Pulmonary fibrosis following long-term nitrofurantoin therapy. *S Afr Med J.* 1982;61:714-7.
2. Holmberg L, Boman G. Pulmonary reactions to nitrofurantoin. 447 cases reported to the Swedish Adverse Drug Reaction Committee 1966-1976. *Eur J Respir Dis.* 1981;62:180-9.
3. Hart J. Pulmonary sensitivity to nitrofurantoin. *Br Med J.* 1970;2:51-2.
4. Bessis L, Callard P, Gotheil C, Biaggi A, Grenier P. High-resolution CT of parenchymal lung disease: precise correlation with histologic findings. *Radiographics.* 1992; 12:45-58.
5. Holmberg L, Boman G, Böttiger LE, Eriksson B, Spross R, Wessling A. Adverse reactions to nitrofurantoin. Analysis of 921 reports. *Am J Med.* 1980;69:733-8.
6. Katzenstein AL. Pathology of drug-induced lung disease. In: Katzenstein AL, editor. *Katzenstein and Askin's surgical pathology of non-neoplastic lung disease.* 3rd ed. Vol. 13: Major problems in pathology. Philadelphia: WB Saunders; 1997. p. 90-2.
7. Sheehan RE, Wells AU, Milne DG, Hansell DM. Nitrofurantoin-induced lung disease: two cases demonstrating resolution of apparently irreversible CT abnormalities. *J Comput Assist Tomogr.* 2000;24:259-61.