



## Case Report

### Hypersensitivity Pneumonitis Caused by *Trichoderma viride*

Alicia Enríquez-Matas,<sup>a,\*</sup> Santiago Quirce,<sup>a</sup> Noelia Cubero,<sup>b</sup> Joaquín Sastre,<sup>a</sup> and Rosario Melchor<sup>b</sup>

<sup>a</sup>Departamento de Alergia, Fundación Jiménez Díaz, Madrid, Spain

<sup>b</sup>Departamento de Neumología, Fundación Jiménez Díaz, Madrid, Spain

#### ARTICLE INFO

##### Article history:

Received November 20, 2007

Accepted December 19, 2007

Available online May 12, 2009

##### Keywords:

Fungi

Hypersensitivity pneumonitis

*Trichoderma viride*

Ultrasonic humidifiers

#### ABSTRACT

Hypersensitivity pneumonitis (HP) can be induced by exposure to indoor molds contaminating humidifiers and heating or ventilation systems. A 54-year-old woman with dyspnea, cough, chest pain, and fever was seen in the emergency room. A chest radiograph revealed interstitial infiltrates and blood tests showed leukocytosis with neutrophilia and severe hypoxemia. A diagnosis of HP was made by a combination of clinical, radiologic, physiologic, and immunologic studies. *Trichoderma viride* was isolated in cultures of water samples from an ultrasonic humidifier installed in the patient's home a year earlier. Precipitating immunoglobulin G antibodies to *T viride* were detected in the patient's serum by enzyme-linked immunosorbent assay. The patient remained symptom free after the humidifier was removed from her home. Our findings strongly suggest that the patient developed HP due to *T viride* from the humidifier. To our knowledge, this is the first report of such a case.

© 2007 SEPAR. Published by Elsevier España, S.L. All rights reserved.

### Neumonitis por hipersensibilidad causada por *Trichoderma viride*

#### RESUMEN

Las neumonitis por hipersensibilidad (NH) pueden producirse debido a la exposición a hongos ambientales por contaminación de humidificadores y sistemas de calefacción. Describimos el caso de una paciente que acudió a urgencias por disnea, tos, dolor torácico y fiebre. Presentaba infiltrados intersticiales en la radiografía de tórax y leucocitosis con neutrofilia e hipoxemia grave en la analítica sanguínea. La combinación de exploraciones clínicas, radiológicas, fisiológicas e inmunológicas llevó al diagnóstico de NH. Tenía un humidificador doméstico en casa desde hacía un año. En el cultivo de las muestras de agua del humidificador creció *Trichoderma viride*. Se detectaron anticuerpos precipitantes inmunoglobulina G anti *T. viride* mediante enzimoanálisis en el suero de la paciente. Tras retirar el humidificador la paciente permaneció asintomática. El resultado de los estudios indica que desarrolló NH causada por *T. viride* que contaminaba el agua del humidificador. Según nuestro conocimiento, éste es el primer caso descrito de NH por *T. viride*.

© 2007 SEPAR. Publicado por Elsevier España, S.L. Todos los derechos reservados.

##### Palabras clave:

Hongos

Neumonitis por hipersensibilidad

*Trichoderma viride*

Humidificadores ultrasónicos

## Introduction

Although molds are a well-known cause of occupational hypersensitivity pneumonitis (HP), domestic exposure to fungal spores is not generally implicated,<sup>1</sup> except in Japan, where summer-type HP due to home contamination by *Trichosporon* species is

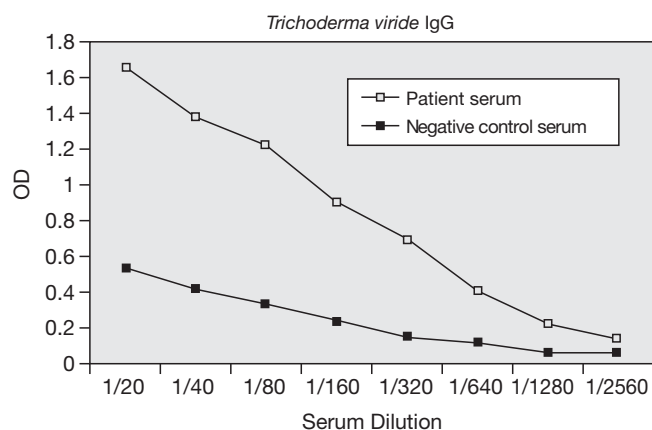
common.<sup>2</sup> However, reports of mold-induced HP in other parts of the world in relation to home reservoirs such as contaminated humidifiers or heating and ventilation systems<sup>3</sup> have been increasing.

## Case Description

A 54-year-old woman, a nonsmoker and a dressmaker by profession, came to the emergency room reporting a 2-month history of progressive dyspnea. She also reported having had cough and fever over the past 15 days. She had been examined by a pulmonologist

\*Corresponding author

E-mail address: aenriquezmatas@hotmail.com (A. Enríquez-Matas).



**Figure.** Precipitating immunoglobulin G (IgG) antibodies against *Trichoderma viride* were detected in the patient's serum by enzyme-linked immunosorbent assay. Optical densities (OD) expressed at 492 nm.

for persistent cough a year earlier, and at that time her chest radiograph had been normal. She had not been exposed to any obvious source of organic dust, except pigeons nesting on balconies near her house. She had kept a canary for years and had installed an ultrasonic humidifier in her home a year earlier.

Physical examination revealed bilateral crackles. Blood tests showed leukocytosis (white cell count, 18 280/mL<sup>3</sup>) with neutrophilia (90%) and severe hypoxemia (PaO<sub>2</sub>, 44 mm Hg). Chest radiographs revealed interstitial infiltrates. The patient was admitted to the intensive care unit for 5 days and was treated with noninvasive mechanical ventilation. Marked improvement was observed within a few days of treatment with antibiotics, oxygen therapy, and bronchodilators. A high-resolution computed tomography scan showed bilateral diffuse micronodular infiltrates and ground-glass opacities. Pulmonary function tests revealed a forced vital capacity (FVC) of 63% of predicted, a forced expiratory volume in 1 second (FEV<sub>1</sub>) of 56% of predicted, and a ratio of FEV<sub>1</sub> to FVC of 75%. The carbon monoxide diffusing capacity of the lung (DLCO) was 57% and the ratio of DLCO to alveolar volume was 73%.

Lymphocytosis (73%) was observed in the bronchoalveolar lavage fluid. The CD4<sup>+</sup>/CD8<sup>+</sup> ratio was 14. A transbronchial lung biopsy showed lymphocytic interstitial pneumonitis and microgranulomas. Cultures of bronchoalveolar lavage fluid for mycobacteria were negative, as were serology tests for common respiratory pathogens, common microorganisms, and pigeon droppings. Skin prick tests to common aeroallergens were also negative. *Trichoderma viride* grew in cultures of water samples from the ultrasonic humidifier. Precipitating immunoglobulin (Ig) G antibodies to *T viride* tested by enzyme-linked immunosorbent assay were positive in serum from the patient and negative in serum from a control subject (Figure).

The specific IgG response was analyzed by immunoblot assay using an in-house extract of the cultured mold. After incubation with the patient's serum, several IgG-binding bands of approximately 6 to 8 kDa, 13 kDa, and 66 kDa were observed. The diagnosis was HP due to *T viride* from the humidifier water. The patient has remained symptom-free since the device was removed from her home a year ago.

## Discussion

The diagnosis of HP was based on clinical, radiologic, physiologic, and immunologic findings that strongly suggested that the clinical picture was related to *T viride* contamination of an ultrasonic humidifier in the patient's home. The evidence supporting the diagnosis included her excellent response to avoidance of exposure, with removal of the contaminated ultrasonic humidifier, and the detection of precipitating IgG antibodies to *T viride*.

*T viride* is the most common of the *Trichoderma* species, which are saprophytic filamentous fungi found around the world. They are widely used in industry to obtain mold-derived enzymes and in agriculture they serve as biofungicides. Only a few cases of infection due to *Trichoderma* species and *T viride* in particular have been reported.<sup>4</sup> There are also 2 reports of eosinophilic pneumonia with precipitating antibodies against *Trichosporon cutaneum* and *T viride*.<sup>5</sup> Finally, *T viride* has been found in high concentrations in dust collected in the bedrooms of children with asthma living in water-damaged homes.<sup>6</sup>

To the best of our knowledge, this is the first report of HP due to *T viride* contamination of a domestic ultrasonic humidifier.

## Acknowledgments

The authors wish to thank Jerónimo Carnés, of Leti Alergia (Tres Cantos, Madrid, Spain), for his help with the enzyme-linked immunosorbent assay.

## References

1. Sugita T, Ikeda R, Nishikawa A. Analysis of *Trichosporon* isolates obtained from the houses of patients with summer-type hypersensitivity pneumonitis. *J Clin Microbiol.* 2004;42:5467-71.
2. Bush RK, Portnoy JM, Saxon A, Terr AI, Wood RA. The medical effects of mold exposure. *J Allergy Clin Immunol.* 2006;117:326-33.
3. Álvarez-Fernández JA, Quirce S, Calleja JL, Cuevas M, Losada E. Hypersensitivity pneumonitis due to an ultrasonic humidifier. *Allergy.* 1998;53:210-2.
4. Chouaki T, Lavarde V, Lachaud L, Raccurr CP, Hennequin C. Invasive Infections due to *Trichoderma* species: report of 2 cases, findings of in vitro susceptibility testing, and review of the literature. *Cin Infect Dis.* 2002;35:1360-7.
5. Imokawa S, Sato A, Taniguchi M, Imamura M, Shirai T, Suda T, et al. Two cases of acute eosinophilic pneumonia with precipitating antibody against *Trichosporon cutaneum* and *Trichoderma viride*. *Nihon Kyobu Shikkan Gakkai Zasshi.* 1993;31:352-9.
6. Vesper SJ, McKinsty C, Yang C, Haugland RA, Kercksmar CM, Yike I, et al. Specific molds associated with asthma in water-damaged homes. *J Occup Environ Med.* 2006;48:852-8.