

Positron Emission Tomography for the Study of Solitary Pulmonary Nodules

Iván Márquez Rodas,^a Javier de Miguel Díez,^b and José Luis Álvarez-Sala^c

^aServicio de Oncología Médica, Hospital Universitario Gregorio Marañón,

Departamento de Fisiología, Facultad de Medicina, Universidad Autónoma de Madrid, Madrid, Spain

^bServicio de Neumología, Hospital Universitario Gregorio Marañón, Universidad Complutense de Madrid, Madrid, Spain

^cServicio de Neumología, Hospital Clínico San Carlos, Universidad Complutense de Madrid, Madrid, Spain

Solitary pulmonary nodules are a major clinical challenge for all doctors involved in their study. The aim is always to avoid missing malignant lesions but also to avoid performing unnecessary diagnostic tests. The most recent research suggests that in the near future chest computed tomography will become even more widely used for the early detection of lung cancer. If this occurs, there is likely to be a marked increase in the number of solitary pulmonary nodules detected, making it essential to develop techniques that enable us to manage this problem with an optimal risk-benefit ratio. We review the underlying principles of positron emission tomography and the advances that have been made in its use for the study of solitary pulmonary nodules. In addition, we discuss the possible causes of false positives and negatives in this technique and the strategies aimed at increasing diagnostic yield.

Key words: Solitary pulmonary nodule. Positron emission tomography. Diagnostic yield.

Introduction

The solitary pulmonary nodule is defined as a single radiological image with a nodular appearance, less than 3 cm in diameter, situated in the lung, surrounded by healthy parenchyma, and not associated with significant lymphadenopathy. These nodules may be present in up to 0.2% of all chest radiographs performed for any reason,¹ and their evaluation is a major challenge in the daily practice

Correspondencia: Dr J. de Miguel Díez
Servicio de Neumología Hospital Universitario Gregorio Marañón
Dr. Esquerdo, 46
28007 Madrid, Spain
E-mail: jmiguel.hgugm@salud.madrid.org

Manuscript received October 22, 2007. Accepted for publication November 7, 2007

La tomografía por emisión de positrones en el estudio del nódulo pulmonar solitario

El nódulo pulmonar solitario (NPS) es un reto clínico importante para todo médico implicado en su estudio. El objetivo se cifra siempre en impedir que una lesión maligna pase inadvertida, pero también en evitar que se realicen pruebas diagnósticas innecesarias. Si en el futuro inmediato se generaliza todavía más, como parecen indicar las investigaciones más recientes, el uso de la tomografía computarizada de tórax como método de detección precoz del cáncer de pulmón, es probable que se produzca un notable aumento del número de NPS diagnosticados. En tal caso se haría imprescindible desarrollar técnicas que permitan abordar este problema con una óptima relación riesgo-beneficio. En este trabajo se revisan los fundamentos y los avances que se han producido en el uso de la tomografía por emisión de positrones como técnica de estudio del NPS. Se discuten, asimismo, las causas que explican los posibles falsos positivos y negativos de la prueba, así como las estrategias dirigidas a incrementar la rentabilidad diagnóstica de este procedimiento.

Palabras clave: Nódulo pulmonar solitario. Tomografía por emisión de positrones. Rentabilidad diagnóstica.

of any physician. On the one hand, between 20% and 40% of solitary pulmonary nodules are malignant lesions, meaning that they should be resected as early as possible.² On the other, between 20% and 40% of resected solitary pulmonary nodules are found to be benign, and no surgical intervention may therefore have been necessary.² The ideal situation would therefore be to be able to classify all nodules as benign or malignant before surgery in order to prevent a malignant lesion from continuing to grow, worsening the prognosis, or in the case of benign lesions, to avoid performing unnecessary excisions, as this surgery is not risk-free.

The diagnosis of the solitary pulmonary nodule is currently based on the findings of a plain chest radiograph or chest computed tomography (CT), whatever the reason for having performed these studies. The nature of the nodule is usually assessed by calculating the risk that the

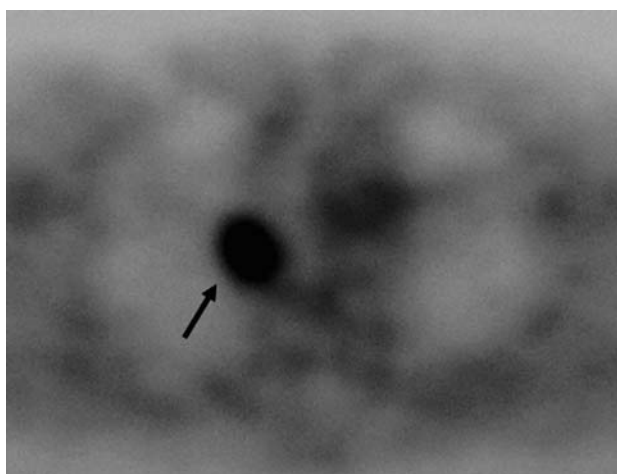


Figure 1. A positive result of positron emission tomography of a solitary pulmonary nodule that was also seen on chest computed tomography and that was later identified as a squamous cell carcinoma. The arrow indicates the malignant nodule.

lesion could be malignant, an analysis that is almost always based on clinical and radiological criteria. The criteria that have been found to be important as independent factors associated with a high probability that the image is malignant are age, a significant history of smoking, a history of cancer (>5 years earlier), and the specific characteristics of the nodule (diameter >3 cm, presence of marginal spiculation, and localization in the upper lobes).³ Other possible radiological findings, such as the presence of calcifications or the stability of the lesion for more than 2 years, are considered to suggest that the lesion is benign.¹ However, in those cases in which the above-mentioned criteria do not permit a firm conclusion to be reached (indeterminate solitary pulmonary nodule), biopsy of the nodule is essential in order to determine whether the lesion is benign or malignant. This can be performed by bronchoscopy, transthoracic fine-needle aspiration, or by surgery. None of these 3 procedures is risk-free.¹

It should be noted that a recent multicenter study appears to demonstrate that, in individuals with a higher risk of presenting lung cancer than the general population, yearly chest CT will detect this tumor, if present, at an earlier stage.⁴ That study also found that 5-year survival is very high in those patients in whom the required surgical resection is performed based on this screening system. In view of these results, if chest CT becomes generalized as a feasible method for the secondary prevention of lung cancer, we may assume that there will be a considerable increase in the number of solitary pulmonary nodules detected. The classification of these nodules into benign or malignant will be an important part of the daily work of the pulmonologist and of physicians in general who treat patients with respiratory diseases. It would therefore be of very great benefit to find new methods for clarifying the differential diagnosis of solitary pulmonary nodules; ideally these methods should avoid the need for performing invasive tests and, at the same time, should reduce the possibility of missing a malignant lesion to zero.

Malignant tumors, including lung cancer, have a high capacity to take up and metabolize glucose.⁵ [18F]-fluorodeoxyglucose (FDG) may be used as a glucose analogue; it is taken up by and accumulates in cells, particularly malignant cells, and subsequently emits radiation in the form of positrons. These particles can then be analyzed using special equipment and translated into tomographic images; this constitutes the basis of the so-called positron emission tomography (PET).⁶ Thus, at a simple level, it may be said that if a solitary pulmonary nodule accumulates radiolabeled glucose to a greater extent than other tissues, it is very likely that the lesion is malignant (Figure 1). In contrast, if the uptake is the same as or lower than that of the surrounding structures, the lesion is probably benign.

Based on these considerations, one of the main indications for PET is the study of the solitary pulmonary nodule that cannot be defined as benign or malignant using conventional imaging techniques (the indeterminate solitary pulmonary nodule).¹ However, false positives (benign lesions that take up FDG, such as granulomas or tuberculomas) and false negatives (malignant lesions that do not take up FDG) do occur in PET. A false positive result means that unnecessary tests will be performed, whilst a false negative will lead to a potentially curable lung cancer not being treated, which is much worse. For this reason, the efforts of many investigators have been directed at establishing the variables that determine the sensitivity and specificity of PET and at attempting to increase the accuracy of the technique. We will now discuss of the role that PET may have in the differential diagnosis of the solitary pulmonary nodule, analyzing its advantages, disadvantages, and the methods that could improve the diagnostic yield of the procedure.

Value of Positron Emission Tomography

Diagnostic Yield

The usefulness of any diagnostic test must be verified by comparing the new technique with a reference technique in a validation process that establishes the new technique's sensitivity (percentage of true positives detected as such) and specificity (percentage of true negatives detected as such). In the case of the solitary pulmonary nodule, the gold standard technique is the pathological study of biopsy material obtained by fiberoptic bronchoscopy, transthoracic fine-needle aspiration, or surgical intervention. However, the majority of studies on this subject also accept the possibility of radiologic follow-up for 18 to 24 months: growth of the nodule is interpreted as a sign of malignancy and radiologic stability over this period as a sign of a benign lesion.⁷⁻⁹

Patient series show considerable variation in the sensitivity and specificity of PET for the evaluation of the solitary pulmonary nodule, mainly as a consequence of the different methodologies used in each study. The results of a meta-analysis published in 2001¹⁰ are therefore important. That meta-analysis, which included 40 studies with a total of more than 1400 lung lesions, established a sensitivity of 96.8% and specificity of 77.8%, based on

analysis of the maximum area under the diagnostic efficacy curve. Those results therefore indicate that PET offers a high sensitivity but that the probability of finding false negatives cannot be ignored; also, its specificity is intermediate, meaning that false positive results may occur relatively frequently.

False positives. Almost all studies evaluating the diagnostic yield of PET in the study of the solitary pulmonary nodule found occasional false positive results. This occurs because elevated FDG uptake is not specific to tumors. Certain chronic infectious or inflammatory disorders, such as granulomas,¹¹ histoplasmosis,¹² tuberculosis, or anthrasilicosis,² as well as benign tumors such as the hamartomas,⁹ to cite some examples, produce false positive images that can lead to confusion and the initiation of invasive tests that are not risk-free (Table).

False negatives. In the case of the solitary pulmonary nodule, a false negative result is of greater consequence than a false positive result, as it can lead to a potentially curable malignant lesion being left untreated. There 3 main causes of false negative results:

1. Tumors that are so small that they are below the spatial resolution of PET. Lesions less than 1 cm may be seen and measured with relative ease on chest CT. However, the maximum resolution of current PET machines is around 6 to 8 mm,⁶ meaning that, even though a nodule takes up labeled glucose, it is unlikely to appear as a detectable image. In an attempt to resolve this problem, some studies have established the strategy of using chest CT to correct the partial volume effect of PET in order subsequently to recalculate the uptake levels.¹³ However, this procedure is relatively complex and is not usually applicable in clinical practice. The evaluation of small nodules is thus one of the most important challenges currently facing us in interpreting PET.

2. Competition in FDG uptake caused by concomitant hyperglycemia. A higher proportion of false negatives is observed in patients with hyperglycemia.¹³ Curiously, sudden increases in the serum glucose levels are responsible for this phenomenon more frequently than persistent hyperglycemia.¹⁴ For this reason, patients are usually told not to eat for at least 4 hours before PET is performed, an important measure, as cases have been reported in which a nodule initially appearing as negative became clearly positive after fasting.¹⁴

3. Malignant tumors with a low capacity for glucose uptake, such as occurs with bronchioloalveolar adenocarcinoma and carcinoid tumor. Neoplasms of this type have been reported among the false negative results of many of the major series published.^{6,13,15}

Bronchioloalveolar adenocarcinoma, an uncommon subtype of lung cancer, shows marked histological variability, leading to heterogeneous radiological manifestations and occasional difficulty in its pathological identification. Its most common presentation is as a solitary pulmonary nodule¹⁶ and its growth is usually slow, with a relatively low tendency to metastasize.¹⁷ In

Causes of False Positive and False Negative Results When Positron Emission Tomography is Used to Study Solitary Pulmonary Nodules

| False Positives | False Negatives |
|-----------------|-----------------------------------|
| Tuberculosis | Nodules less than 1 cm |
| Sarcoidosis | Bronchioloalveolar adenocarcinoma |
| Histoplasmosis | Carcinoid tumor |
| Anthrasilicosis | Metastasis from thyroid cancer |
| Infections | Metastasis from renal carcinoma |
| Pneumonia | |
| Abscesses | |
| Hamartomas | |

PET studies, it can give rise to false negative results in up to 57% of cases. In addition, it has been reported that its ability to take up labeled glucose is inversely proportional to the degree of histological differentiation of the tumour,¹⁸ which has been explained by the fact that the malignant cells of this tumor express a smaller quantity of the type 1 glucose transporter than other primary lung neoplasms.¹⁷

Pulmonary carcinoid tumors are neuroendocrine neoplasms that arise from cells that can take up and decarboxylate amine precursors (APUD system).¹⁹ They show a high degree of differentiation, meaning that they take up less labeled glucose than other malignant tumors and can sometimes be difficult to detect on PET.²⁰ To get round this problem, some authors have recently proposed the use of a specific metabolite of neuroendocrine tumors, such as [(11)C]-5-hydroxytryptophan, instead of labeled glucose; this metabolite is selectively taken up by cells of the APUD system, increasing the diagnostic yield of PET.¹⁹ However, it is clear that further studies are necessary in order to evaluate the efficacy of this method in these cases.

Prognostic Value

Apart from its utility in diagnosis, PET has prognostic value, particularly in patients with previously diagnosed lung cancer. It is useful for staging¹ and for detecting recurrence, both in lung and other tumors.^{6,21} In addition, the degree of FDG uptake is a good marker of the aggressiveness of a tumor.²² It has also been observed that certain chemoresistant tumors take up less labeled glucose, and that uptake is inversely proportional to the expression of P-glycoprotein, one of the most widely studied chemoresistance factors.²³ However, as the possibilities for PET to determine the prognosis of a malignant lesion are still poorly defined, we must await further studies.

Evaluation of Uptake in Positron Emission Tomography

There are 2 ways to evaluate FDG uptake in PET. One is subjective-qualitative (presence or absence of uptake, with however many intermediate degrees desired) and the other objective-semiquantitative. This second method is based on the application of the so-called “standardized

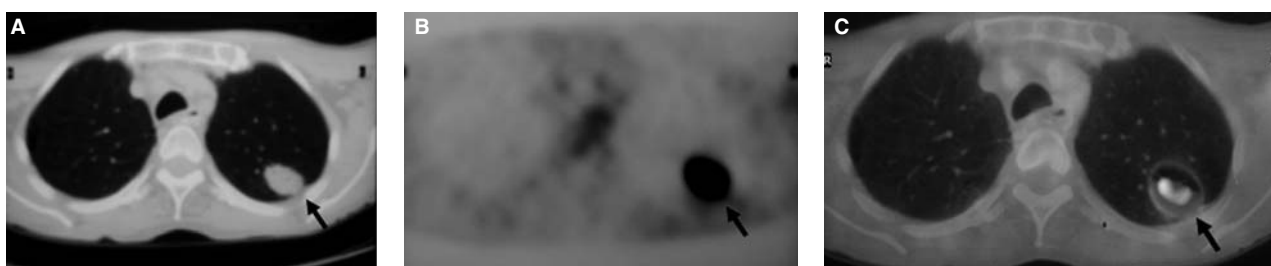


Figure 2. Malignant solitary pulmonary nodule visible with increased definition in the study performed simultaneously with positron emission tomography and chest computed tomography (thoracic PET-CT) and that was subsequently identified as a pulmonary adenocarcinoma. The nodule is shown in the chest CT (A), PET (B), and PET-CT (C). The arrows indicate the site of the malignant nodule.

uptake value" (SUV), which expresses FDG uptake by the lesion normalized according to the dose administered and the subject's body weight. The SUV provides the possibility for a "gray scale," which has a range from 0 to an undefined maximum value. The value of 2.5 is accepted as the cut-off point for malignancy.⁶

At first sight, objective values may be thought to be more reliable than subjective ones. However, a number of studies have found no significant differences in the sensitivity or specificity of PET between the 2 forms of evaluation.^{10,24} In addition, it has even been stated that the probability of malignancy in nodules with an SUV between 0 and 2.5 may be as high as 24%.¹⁵ In fact, having defined the many factors that can affect the uptake of labeled glucose and, therefore, the SUV, it is not easy to establish fixed values that serve to distinguish between the benign and malignant nature of a solitary pulmonary nodule.¹³

Strategies to Improve the Diagnostic Yield of Positron Emission Tomography

The diagnostic yield of PET can be increased if the probability of malignancy of a solitary pulmonary nodule in an individual patient is calculated before the test. Application of the model proposed by Swensen et al,³ which collates 3 clinical and 3 radiological factors (as described above), significantly increased the area under the PET diagnostic efficacy curve.²⁴ In contrast, Dewan and coworkers²⁵ did not observe that the calculation of the pretest probability of malignancy improved the diagnostic efficacy of the technique. This discrepancy may be explained by the fact that there were fewer patients in the second study and that the pretest probability of malignancy was calculated using Bayesian methods rather than logistic regression.

In recent years, new strategies have been aimed at improving the diagnostic efficacy of PET. One of these is based on taking 2 series of tomographic images separated by a given time, usually between 45 and 60 minutes. Zhuang and coworkers,²⁶ for example, used this method to study various tumor cell lines and inflammatory lesions induced in experimental animals, as well as pulmonary nodules whose benign or malignant nature was already known, and were able to demonstrate that the uptake of malignant tumors increased with time; this did not occur in benign lesions. The interest in these results derives from the fact that they add a new aspect to labeled glucose uptake that is specific to tumor cells and is not observed

in benign nodules. The use of this difference could serve to reduce the number of false positives observed in PET. Future studies will be necessary to confirm the reliability of this method.

A number of formulas designed to correct the underestimation of the SUV caused by hyperglycemia, such as adjusting the value of this parameter according to the patient's serum glucose level, have also been studied. Using this method, some authors have achieved a slight increase in the reproducibility of the technique.²⁷

Another strategy that has been used to increase the diagnostic yield of PET is to combine it with images from chest CT (thoracic PET-CT).²⁸ Over the past 2 or 3 years, a number of machines have appeared that enable both techniques to be performed simultaneously; these provide true rather than virtual superposition of the images obtained by PET and chest CT (Figure 2). In a recent retrospective study comparing the sensitivity and specificity of CT, PET, and PET-CT in the study of the solitary pulmonary nodule, significantly higher yields were found with the integrated PET-CT system than with either of the other 2 techniques separately.²⁹ However, that study had at least 2 major limitations: its retrospective design and the small size of the sample. It would therefore be interesting to perform further studies with a prospective design and a larger number of patients.

Indications for Positron Emission Tomography in the Study of the Solitary Pulmonary Nodule

Figure 3 shows a simple algorithm that includes those situations in which, according to current literature, PET may help to differentiate between malignant and benign solitary pulmonary nodules. In summary, it may be stated that PET is useful for evaluating nodules that are not clearly defined as benign or malignant from a radiological point of view. However, it should not be forgotten that false positives or, worse, false negatives may also occur with this technique.

Conclusion

The solitary pulmonary nodule continues to be a major challenge for any physician involved in its study. The need to not miss the diagnosis of a malignant lesion means that, on many occasions, invasive procedures are performed; these procedures are never risk-free and can give rise to serious complications. In addition, benign nodules may

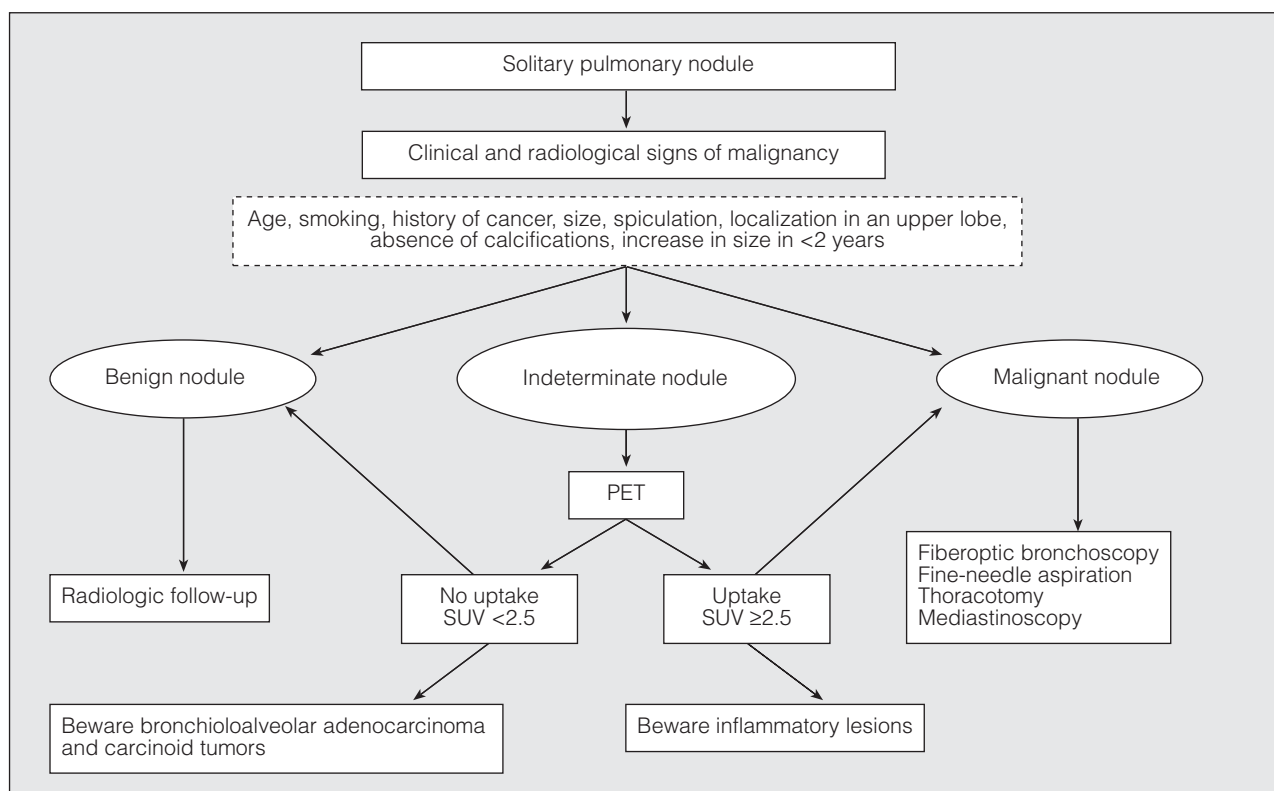


Figure 3. Diagnostic algorithm for the solitary pulmonary nodule highlighting the role of positron emission tomography (PET). SUV indicates standardized uptake value.

also be surgically resected when this is unnecessary. This dilemma, far from being resolved, will likely become ever more common in daily practice, particularly if chest CT imaging becomes accepted as the method of choice for the early detection of lung cancer in the at-risk population.

PET may help in decision-taking with respect to the best path to follow in the differential diagnosis of a solitary pulmonary nodule of indeterminate characteristics. However, it must not be forgotten that this technique has limitations, particularly with regard to small nodules and certain tumors, such as bronchioloalveolar adenocarcinoma and carcinoid tumors. The current aims are to improve the technique itself, evaluate the diagnostic value of new metabolites specific to tumors that have a low glucose uptake (such as the 2 just mentioned), evaluate the possibility of PET imaging performed sequentially (in 2 phases) or combined (superimposed) with chest CT (thoracic PET-CT), and validate the models that simultaneously integrate the pretest probability with PET in order to improve the yield of this diagnostic technique.

REFERENCES

1. Ost D, Fein AM, Feinsilver SH. The solitary pulmonary nodule. *N Engl J Med.* 2003;348:2535-42.
2. Bury T, Dowlati A, Paulus P, Corhay JL, Benoit T, Kayembe JM, et al. Evaluation of the solitary pulmonary nodule by positron emission tomography imaging. *Eur Respir J.* 1996;9:410-4.

3. Swensen SJ, Silverstein MD, Ilstrup DM, Schleck CD, Edell ES. The probability of malignancy in solitary pulmonary nodules. Application to small radiologically indeterminate nodules. *Arch Intern Med.* 1997;157:849-55.
4. The International Early Lung Cancer Action Program investigators. Survival of patients with stage I lung cancer detected on CT screening. *N Engl J Med.* 2006;355:1763-71.
5. Nolop KB, Rhodes CG, Brudin LH, Beaney RP, Krausz T, Jones T, et al. Glucose utilization in vivo by human pulmonary neoplasms. *Cancer.* 1987;60:2682-9.
6. Präuer HW, Weber WA, Römer W, Treuman T, Ziegler SI, Schwaiger M. Controlled prospective study of positron emission tomography using the glucose analogue 18F-fluorodeoxyglucose in the evaluation of pulmonary nodules. *Br J Surg.* 1998;85:1506-11.
7. Richter JA, Torre W, Gámez C, Aramendía JM, Crespo A, Nicolás A, et al. Valor del PET-18FDG en el cáncer de pulmón. *Med Clin (Barc).* 1999;113:567-71.
8. Herder GJ, Golding RP, Hoekstra OS, Comans EF, Teule GJ, Postmus PE, et al. The performance of 18-F-fluorodeoxyglucose positron emission tomography in small solitary pulmonary nodules. *Eur J Nucl Mol Imaging.* 2004;31:1231-6.
9. Ruiz Hernández G, González A, de Juan R, Vereá H, Callol LM, Domper M, et al. Exactitud diagnóstica del análisis semicuantitativo de la tomografía por emisión de positrones en lesiones pulmonares radiológicamente indeterminadas. *Rev Esp Med Nucl.* 2002;21:403-9.
10. Gould MK, Maclean CC, Kuschner WG, Rydzak CE, Owens DK. Accuracy of positron emission tomography for diagnosis of pulmonary nodules and mass lesions. A meta-analysis. *JAMA.* 2001;285:936-7.
11. García de Llanos C, Cabrera Navarro P, Freixinet Gilart J, Rodríguez Suárez P, Hussein Serhald M, Romero Saavedra T. Textiloma intratorácico interpretado como carcinoma broncogénico. Otro falso positivo de la tomografía por emisión de positrones. *Arch Bronconeumol.* 2007;43:292-4.

MÁRQUEZ RODAS I ET AL. POSITRON EMISSION TOMOGRAPHY FOR THE STUDY
OF SOLITARY PULMONARY NODULES

12. Dewan NA, Gupta NC, Redepenning LS, Phalen JJ, Frick MP. Diagnostic efficacy of PET-FDG imaging in solitary pulmonary nodules. Potential role in evaluation and management. *Chest*. 1993;104:997-1002.
13. Hickeson M, Yun M, Matthies A, Zhuang H, Adam LE, Lacorte L, et al. Use of a corrected standardized uptake value based on the lesion size on CT permits accurate characterization of lung nodules on FDG-PET. *Eur J Nucl Med*. 2002;29:1639-47.
14. Ojha B, Bartley SC, Gundlapalli S, Mountz JM. Effect of dietary intake before F-18 FDG positron emission tomographic scanning on the evaluation of a solitary pulmonary nodule. *Clin Nucl Med*. 2001;26:908-9.
15. Bryant AS, Cerfolio RJ. The maximum standardized uptake values on integrated FDG-PET/CT is useful in differentiating benign from malignant pulmonary nodules. *Ann Thorac Surg*. 2006;82:1016-20.
16. Sabloff BS, Truong MT, Wistuba II, Erasmus JJ. Bronchioalveolar cell carcinoma: radiologic appearance and dilemmas in the assessment of response. *Clin Lung Cancer*. 2004;6:108-12.
17. Higashi K, Ueda Y, Sakurai A, Wang XM, Xu L, Murakami M, et al. Correlation of glut-1 glucose transporter expression with [18F]FDG uptake in non-small cell lung cancer. *Eur J Nucl Med*. 2000;27:1778-85.
18. Higashi K, Ueda Y, Seki H, Yuasa K, Oguchi M, Noguchi T, et al. Fluorine-18-FDG PET imaging is negative in bronchioloalveolar lung carcinoma. *J Nucl Med*. 1998;39:1016-20.
19. Eriksson B, Örlfors H, Oberg K, Sundin A, Bergström M, Långström B. Developments in PET for the detection of endocrine tumors. *Best Pract Res Clin Endocrinol Metab*. 2005;19:311-24.
20. Erasmus JJ, McAdams HP, Patz EF Jr, Coleman RE, Ahuja V, Goodman PC. Evaluation of primary pulmonary carcinoid tumors using FDG-PET. *AJR*. 1998;170:1369-73.
21. Muñoz Llarena A, Carrera Revilla S, Gil-Negrete Laborda A, Pac Ferrer J, Barceló Galíndez R, López Vivanco G. Factores pronósticos en metástasis pulmonares reseccables de carcinoma colorrectal. *Arch Bronconeumol*. 2007;43:309-16.
22. Higashi K, Matsunari I, Ueda Y, Ikeda R, Guo J, Oguchi M, et al. Value of whole body FDG-PET in management of lung cancer. *Ann Nucl Med*. 2003;17:1-14.
23. Higashi K, Ueda Y, Ikeda R, Kodama Y, Guo J, Matsunari I, et al. P-glycoprotein expression is associated with FDG uptake and cell differentiation in patients with untreated lung cancer. *Nucl Med Commun*. 2004;25:19-27.
24. Herder GJ, Van Tinteren H, Golding RP, Kostense PJ, Comans EF, Smit EF, et al. Clinical prediction model to characterize pulmonary nodules. Validation and added value of 18F-fluorodeoxy-glucose positron emission tomography. *Chest*. 2005;128:2490-6.
25. Dewan NA, Shehan CJ, Reer SD, Gobar LS, Scott WJ, Ryschon K. Likelihood of malignancy in a solitary pulmonary nodule. Comparison of Bayesian analysis and results of FDG-PET scan. *Chest*. 1997;112:416-22.
26. Zhuang H, Pourdehnad M, Lambright ES, Yamamoto AJ, Lanuti M, Li P, et al. Dual time point 18F-FDG PET imaging for differentiating malignant from inflammatory processes. *J Nucl Med*. 2001;42:1412-7.
27. Nakamoto Y, Zasadny KR, Minn H, Wahl RL. Reproducibility of common semi-quantitative parameters for evaluating lung cancer glucose metabolism with positron emission tomography using 2-deoxy-2-18F-fluoro-D-glucose. *Mol Imaging Biol*. 2002;4:171-8.
28. Maldonado A, González-Alenda FJ, Alonso M, Sierra JM. Utilidad de la tomografía por emisión de positrones-tomografía computarizada (PET-TC) en neumología. *Arch Bronconeumol*. 2007;43:562-72.
29. Kim SK, Allen-Auerbach M, Goldin J, Fueger BJ, Dahlbom M, Brown M, et al. Accuracy of PET/CT in characterization of solitary pulmonary lesions. *J Nucl Med*. 2007;48:214-20.