

## Polymyositis and Interstitial Lung Disease With a Favorable Response to Corticosteroids and Methotrexate

Nieves Hoyos,<sup>a</sup> Álvaro Casanova,<sup>a</sup> Silvia Sánchez,<sup>a</sup> Claudia Valenzuela,<sup>a</sup> Asunción García,<sup>b</sup> and Rosa María Girón<sup>a</sup>

<sup>a</sup>Servicio de Neumología, Hospital de La Princesa, Madrid, Spain

<sup>b</sup>Servicio de Anatomía Patológica, Hospital de La Princesa, Madrid, Spain

Polymyositis is a rare collagen disease that can involve the lungs. Between 5% and 30% of patients with polymyositis present interstitial lung disease at diagnosis or during the course of disease. Onset is usually insidious and involves dyspnea and nonproductive cough. Several histopathological findings are associated with polymyositis and the most common is nonspecific interstitial pneumonia. The prognosis of interstitial lung disease associated with polymyositis is better than that of idiopathic pulmonary fibrosis, since most patients respond to treatment with corticosteroids and immunosuppressants.

We report the case of a 60-year-old woman with dyspnea and muscle weakness who was diagnosed with polymyositis and interstitial lung disease (radiography indicated possible nonspecific interstitial pneumonia). The patient responded well to prednisone and methotrexate.

**Key words:** Polymyositis. Lung diseases, interstitial. Nonspecific interstitial pneumonia.

Polimiositis y afectación pulmonar intersticial con buena respuesta a glucocorticoides y metotrexato

La polimiositis es una colagenopatía rara, que puede afectar al pulmón. Entre un 5 y un 30% de los pacientes con polimiositis presenta una enfermedad pulmonar intersticial en el momento del diagnóstico o durante el curso de la enfermedad. El inicio suele ser insidioso en forma de disnea y tos seca. Son varias las entidades histopatológicas que se asocian a polimiositis, de las cuales la más frecuente es la neumonía intersticial no específica. El pronóstico de la enfermedad pulmonar intersticial difusa asociada a polimiositis es mejor que el de la fibrosis pulmonar idiopática, ya que la mayoría de los pacientes responde al tratamiento con glucocorticoides e inmunodepresores.

Presentamos el caso clínico de una mujer de 60 años con síntomas de disnea y debilidad muscular, a quien se diagnosticó de polimiositis y enfermedad pulmonar intersticial difusa (posible neumonía intersticial no específica por hallazgos radiológicos), y que mostró buena respuesta al tratamiento con prednisona y metotrexato.

**Palabras clave:** Polimiositis. Enfermedad pulmonar intersticial difusa. Neumonía intersticial no específica.

### Introduction

Polymyositis is an uncommon rheumatological disease of unknown etiology, with an estimated prevalence of between 0.5 and 8 cases per million. Proximal muscle weakness is the most frequent clinical manifestation and the initial symptom in 80% of patients. The diagnostic criteria are symmetric proximal muscle weakness, increased muscle enzyme levels (creatine kinase and aldolase), characteristic alterations in the electromyogram, and the demonstrated presence of inflammatory cell infiltrates and necrosis in a sample of muscle tissue.<sup>1</sup> Pulmonary complications appear in more than 46% of patients with polymyositis and are associated with reduced survival.<sup>1</sup>

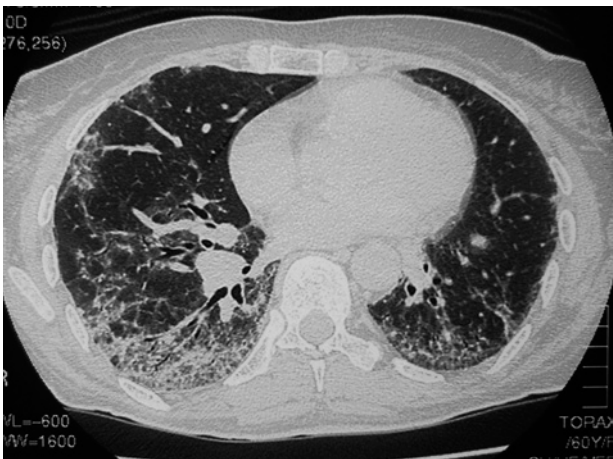Correspondence: Dr. R.M. Girón.  
Servicio de Neumología. Hospital Universitario de La Princesa.  
Diego de León, 62. 28006 Madrid. España.  
E-mail: med002861@nacom.es

Manuscript received October 26, 2006. Accepted for publication November 14, 2006.

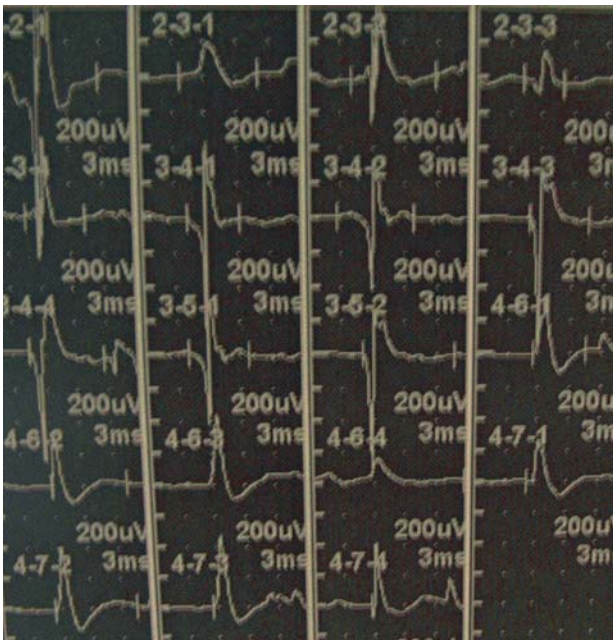
We present the case of a patient whose condition manifested with simultaneous muscular and pulmonary symptoms. She was diagnosed with polymyositis and interstitial lung disease that improved with corticosteroids and methotrexate.

### Case Description

The patient was a 60-year-old homemaker with no history of substance abuse or exposure to toxic substances and the following clinical history: hypertension, hypercholesterolemia, depression since age 25 for which she was receiving venlafaxine and lorazepam, atopic dermatitis, and fibrositis that was being treated with nonsteroidal anti-inflammatory drugs. The patient came to the pulmonology clinic with a 3-year history of slowly progressive effort dyspnea accompanied by dry cough and occasional episodes of chest pain on both sides. There was no hemoptysis or fever. She also complained of myalgia, especially in the proximal muscles, which had been affecting her for the last few months to the extent that she could not rise from a chair without using her arms, nor could she shower or comb her hair without difficulty.



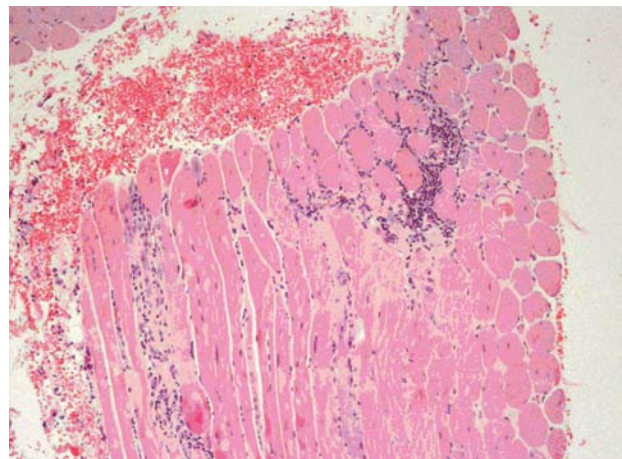
**Figure 1.** High-resolution computed tomography showing a bilateral interstitial pattern, with septal enlargement, areas of ground glass opacity, reticulation, and traction bronchiectasis with predominance in the lower lobes.



**Figure 2.** Electromyogram of the quadriceps muscle showing a myopathic pattern with low-amplitude waves.

She presented arthralgia in the knees and hands and reddening of the fingers in response to cold temperatures, although Raynaud disease was not evident. The most noteworthy aspect of the physical examination was Velcro-type end-inspiratory crackles on pulmonary auscultation; cardiac auscultation was normal. Of particular interest was considerable weakness at the level of the scapula and pelvis, which made it difficult for the patient to raise her arms above her head and rise from a chair without using her arms.

Standard chest radiograph revealed a predominant bibasilar interstitial pattern. Baseline arterial gas values were as follows: PaO<sub>2</sub>, 59 mm Hg; PaCO<sub>2</sub>, 42.8 mm Hg; oxygen saturation, 90%; and alveolar-arterial gradient in partial pressure of oxygen, 31.9 mm Hg. Based on a suspicion of interstitial lung disease coupled with a possible connective tissue disorder,



**Figure 3.** Biopsy of the deltoid muscle showing a lymphocytic inflammatory infiltrate and necrosis of striate muscle fibers.

the decision was taken to admit the patient to hospital for further tests.

The most relevant details of the laboratory analysis were as follows: aspartate aminotransferase, 111 U/L; alanine aminotransferase, 81 U/L; lactate dehydrogenase, 886 U/L; creatine kinase, 3976 U/L; and creatine kinase MB, 142 U/L. The remaining biochemical parameters, complete blood count, and coagulation study were normal. Serology provided positive results for antinuclear antibodies at a low-titer (1/80), and for smooth muscle and anti-Jo-1 antibodies. Tests for the remaining antibodies—anti-Ro/SS-A, anti-La/SS-B, anti-Sm, antiribonucleoprotein, and circulating antineutrophil cytoplasmic antibodies (with a perinuclear and cytoplasmic pattern)—and rheumatoid factor were negative. The protein profile was normal.

High-resolution computed tomography of the chest revealed a bilateral interstitial pattern, with septal enlargement, areas of ground glass opacity, reticulation, and traction bronchiectasis predominantly in the lower lobes and no clear areas of honeycombing (Figure 1). The results of lung function testing were as follows: forced vital capacity, 2400 mL (84.2%); forced expiratory volume in the first second, 1970 mL (81.7%); total lung capacity, 4080 mL (80%); diffusing capacity of the lung for carbon monoxide (DLCO), 4.65 mL/min/mm Hg (59.5%); and the DLCO/alveolar volume ratio, 1.33 (87%). Fiberoptic bronchoscopy did not reveal endobronchial lesions. A culture and smear of bronchial aspirate and bronchoalveolar lavage fluid were negative. A cell count in bronchoalveolar lavage fluid based on 400 cells revealed 244 macrophages (61%), 52 lymphocytes (13%), 44 neutrophils (11%), and 60 eosinophils (15%). Transbronchial biopsy yielded a fragment of lung parenchyma with fibrosis and an interstitial inflammatory infiltrate, as well as destruction of the alveolar parenchyma.

The electromyogram of the quadriceps and deltoid muscles revealed a myopathic pattern (Figure 2). Finally, a biopsy was taken of the deltoid muscle, and the sample tissue presented a marked inflammatory and interstitial infiltrate with a predominance of lymphocytes and necrosis. These abnormalities are indicative of polymyositis (Figure 3).

The diagnosis was of diffuse interstitial lung disease (DILD) associated with polymyositis, with possible nonspecific interstitial pneumonia (NSIP) according to the radiograph. Therefore, treatment was begun with methotrexate (25 mg weekly) and prednisone (60 mg/d). The patient progressed favorably, with an improvement in clinical symptoms, laboratory parameters, and respiratory function. Two months after treatment started,

creatinase kinase was 97 U/L, aspartate aminotransferase 19 U/L, and alanine aminotransferase 40 U/L. Respiratory function improved by 8% in forced vital capacity and 12% in DLCO.

## Discussion

Connective tissue diseases are a heterogeneous group of immune-mediated inflammatory disorders that may involve several organs, including the lung. Within this group, polymyositis and dermatomyositis can compromise the lung in different ways: aspirative pneumonia or ventilatory insufficiency as a complication of neuromuscular weakness, DILD, drug-induced lung disease, and primary carcinoma of the lung.

DILD was first reported as a complication of polymyositis/dermatomyositis in 1956,<sup>1</sup> and this association has been clearly established since then with an estimated prevalence of polymyositis ranging from 5% to 30% according to the study.<sup>2,3</sup> It is twice as frequent in women and the mean age of presentation is 50 years. Nowadays, lung involvement is the main cause of death in this group of patients.<sup>3</sup>

Although there is a broad spectrum of clinical manifestations in polymyositis associated with DILD, onset is usually insidious, with dyspnea and dry cough developing over weeks or months. Physical exploration reveals bibasilar crackles. Clubbing is uncommon. Raynaud disease affects 50% to 60% of patients with polymyositis and positive anti-Jo-1 antibodies. Respiratory function tests usually show a reduction in forced vital capacity, total lung capacity, and DLCO. There are few reports in the medical literature on bronchoalveolar lavage; neutrophils predominate and there is an inversion of the CD4<sup>+</sup>/CD8<sup>+</sup> ratio.<sup>4</sup>

The first reports of polymyositis associated with DILD mentioned similarities with idiopathic pulmonary fibrosis. More recent reports show that the histological patterns of interstitial lung disease associated with polymyositis are varied.<sup>5</sup> After the changes made in recent years to the classification of idiopathic interstitial pneumonia,<sup>6</sup> Douglas et al<sup>7</sup> reviewed the lung biopsies of 22 patients with polymyositis and DILD, and saw that 18 (81%) presented NSIP, 2 diffuse alveolar damage, 1 bronchiolitis obliterans with organized pneumonia, and the remainder usual interstitial pneumonia. This and other studies<sup>8-10</sup> show that NSIP is the most frequent histological finding in polymyositis. Findings based on pathological investigations are similar to those of idiopathic NSIP and include heterogeneous lesions, diffuse involvement of the alveolar wall with different degrees of inflammation or fibrosis, preservation of alveolar architecture, and absence of fibroblastic foci.

High-resolution computed tomography is more sensitive than conventional chest radiography for the detection of DILD. In the case of DILD associated with polymyositis, the findings include septal enlargement (90%), reticular opacities (43% to 92%), ground glass opacities (33% to 100%), parenchymal micronodules (27% to 73%), patchy consolidation (22% to 100%), traction bronchiectasis (0% to 17%), and honeycombing (0% to 19%). The combination of a ground-glass pattern, reticular opacities, and traction

bronchiectasis, without honeycombing, is indicative of NSIP, as was the case with our patient.

There is no relationship between creatine kinase concentrations or the extension of the muscle disease and the development of DILD. Most of the antibodies detected in patients with polymyositis recognize enzymes that intervene in the synthesis of transfer RNA (tRNA). The most common antibodies are those that target the histidyl-tRNA synthetase enzyme or anti-Jo-1 antibodies, which are present in only 30% of patients with polymyositis/dermatomyositis. Nevertheless, 75% to 100% of patients with polymyositis/dermatomyositis and positive anti-Jo1 antibodies present associated interstitial lung disease; therefore, this antibody is considered a marker of DILD, although it does not seem to have an added prognostic value.<sup>11,12</sup> The so-called synthetase syndrome includes other types of myositis that present other antisynthetase antibodies such as threonyl-tRNA synthetase (anti-PL7), alanyl-tRNA synthetase (anti-PL12), or isoleucyl-tRNA synthetase (anti-OJ). These are also associated with interstitial lung disease.

Although there have been no randomized placebo-controlled clinical trials in patients with DILD associated with polymyositis, the decision to treat or not depends on the severity of lung dysfunction, the type of DILD, and whether or not glucocorticoids or immunosuppressants are contraindicated. Most authors recommend glucocorticoids at a dose of 0.75 mg/d to 1.0 mg/d (prednisone or an equivalent) and tapering the dose over time. A lack of response to corticosteroids or the onset of adverse events makes it necessary to introduce a cytotoxic or immunosuppressive agent. Although data are limited to isolated cases or small case series, favorable responses have been reported with cyclophosphamide (both orally and intravenously),<sup>13,14</sup> azathioprine,<sup>15,16</sup> methotrexate and cyclosporine A,<sup>17</sup> and tacrolimus.<sup>18</sup> In the study by Douglas et al<sup>7</sup> involving 70 patients with DILD associated with polymyositis/dermatomyositis, the most common immunosuppressants were azathioprine (25 cases) and methotrexate (14 cases). We used methotrexate because of previous favorable experience with this drug in a similar case. Slow-release commercial formulations for oral, muscular, or subcutaneous administration make methotrexate a good treatment option, since they guarantee adherence and avoid the consequences of potential overdose by the patient.

The prognosis of DILD associated with polymyositis/dermatomyositis is better than that of idiopathic pulmonary fibrosis, as is the case with other collagen diseases. In the study by Douglas et al,<sup>7</sup> mean survival at 3 and 5 years was 74% and 60%, respectively. By contrast, in the study by Marie et al,<sup>3</sup> mean survival was greater: 90% at 3 years and 86.5% at 5 years.

In summary, most patients with polymyositis/dermatomyositis associated with DILD present clinical, radiographic, and histological evidence indicative of NSIP, which has a better prognosis and response to corticosteroids. Although no controlled randomized clinical trials have been carried out, most patients improve with corticosteroids and immunosuppressants.



REFERENCES

1. Mills ES, Matthews WH. Interstitial pneumonitis in dermatopolymyositis. *JAMA*. 1956;160:1467-70.
2. Salmeron G, Greenberg SD, Lidsky MD. Polymyositis and diffuse interstitial lung disease. A review of the pulmonary histopathologic findings. *Arch Intern Med*. 1981;141:1005-10.
3. Marie I, Hatron PY, Hachulla E, Wallaert B, Michon-Pasturel U, Devulder B. Pulmonary involvement in polymyositis and in dermatomyositis. *J Rheumatol*. 1999;26:1336-43.
4. Kourakata H, Takada T, Suzuki E, Enomoto K, Saito I, Taguchi Y, et al. Flowcytometric analysis of bronchoalveolar lavage fluid cells in polymyositis/dermatomyositis with interstitial pneumonia. *Respirology*. 1999;4:223-8.
5. Tazelaar HD, Viggiano RW, Pickersgill J, Colby TV. Interstitial lung disease in polymyositis and dermatomyositis. Clinical features and prognosis as correlated with histologic findings. *Am Rev Respir Dis*. 1990;141:727-33.
6. American Thoracic Society (ATS)/European Respiratory Society. International multidisciplinary consensus classification of the idiopathic interstitial pneumonias. *Am J Respir Crit Care Med*. 2002;165:277-304.
7. Douglas WW, Tazelaar HD, Hartman TE, Hartman RP, Decker PA, Schroeder DR. Polymyositis-dermatomyositis-associated interstitial lung disease. *Am J Respir Crit Care Med*. 2001;164:1182-5.
8. Mino M, Noma S, Taguchi Y, Tomii K, Kohri Y, Oida K. Pulmonary involvement in polymyositis and dermatomyositis: sequential evaluation with CT. *AJR Am J Roentgenol*. 1997;169:83-7.
9. Akira M, Hara H, Sakatani M. Interstitial lung disease in association with polymyositis-dermatomyositis: long term follow-up CT evaluation in seven patients. *Radiology*. 1999;210:333-8.
10. Ikezoe J, Johkoh T, Kohno N, Takeuchi N, Ichikado K, Nakamura H. High-resolution CT findings of lung disease in patients with polymyositis and dermatomyositis. *J Thorac Imaging*. 1996;11:250-9.
11. Yoshida S, Akizuki M, Mimori T, Yamagata H, Inada S, Homma M. The precipitating antibody to an acidic nuclear protein antigen, the Jo-1, in connective tissue diseases. A marker for a subset of polymyositis with interstitial pulmonary fibrosis. *Arthritis Rheum*. 1983;26:604-11.
12. Bernstein RM, Morgan SH, Chapman J, Bunn CC, Mathews MB, Turner-Warwick M. Anti-Jo-1 antibody: a marker for myositis with interstitial lung disease. *Br Med J*. 1984;289:151-2.
13. Mok CC, To CH, Szeto ML. Successful treatment of dermatomyositis-related rapidly progressive interstitial pneumonitis with sequential oral cyclophosphamide and azathioprine. *Scand J Rheumatol*. 2003;32:181-3.
14. Shinohara T, Hidaka T, Matsuki Y, Ishizuka T, Takamizawa M, Kawakami M, et al. Rapidly progressive interstitial lung disease associated with dermatomyositis responding to intravenous cyclophosphamide pulse therapy. *Intern Med*. 1997;36:519-23.
15. Bunch TW, Worthington JW, Combs JJ, Ilstrup DM, Engel AG. Azathioprine with prednisone for polymyositis. A controlled, clinical trial. *Ann Intern Med*. 1980;92:365-9.
16. Bunch TW. Prednisone and azathioprine for polymyositis: long-term followup. *Arthritis Rheum*. 1981;24:45-8.
17. Chang HK, Lee DH. Successful combination therapy of cyclosporine and methotrexate for refractory polymyositis with anti-Jo-1 antibody: a case report. *J Korean Med Sci*. 2003;18:131-4.
18. Ochi S, Nanki T, Takada K, Suzuki F, Komano Y, Kubota T, et al. Favorable outcomes with tacrolimus in two patients with refractory interstitial lung disease associated with polymyositis/dermatomyositis. *Clin Exp Rheumatol*. 2005;23:707-10.