

Multiple Chest Wall Abscesses Complicating Blunt Chest Trauma

To the Editor: Infections of the chest wall are usually secondary to surgical procedures¹ and, more rarely, to contamination through open chest injuries. We report an extremely rare case in which a staphylococcal sepsis led to the infection of preexisting hematomas in a patient with chest trauma.

A 62-year-old patient was admitted to the emergency department with a diminished level of consciousness after injuries received in a traffic accident. The patient had a respiratory rate of 18 breaths/min, a pulse rate of 82 beats/min, blood pressure of 120/70 mmHg, and a score of 13 on the Glasgow Coma Scale. Findings from cardiocirculatory, respiratory, and abdominal examination were normal and peripheral pulses were present. The complete blood count and emergency biochemistry were also normal. A simple chest radiograph revealed multiple left rib fractures (the fifth to the ninth ribs), with no pleuropulmonary trauma. The computed tomography scan of the chest showed a subarachnoid hemorrhage in the right parietal region.

The neurological status of the patient improved and became normal on the fourth day after admission. At day 5, the patient developed fever and dyspnea. Physical examination showed hypoventilation in the lung bases, and blood gas analysis showed a PaO₂ of 54 mmHg, a PaCO₂ of 27 mmHg, and a pH of 7.5. A chest radiograph revealed a left pulmonary base infiltrate and ipsilateral pleural effusion. Urine and blood cultures were started and treatment was initiated with ceftazidime and tobramycin. The patient was admitted to the intensive care unit intubated and mechanically ventilated with a positive end-expiratory pressure of 10 cm H₂O; a PaO₂ of 230 mmHg was attained. Physical examination showed fluctuant masses measuring 3 and 5 cm, respectively, in the left parasternal region and located in the second and fourth intercostal spaces, without heat or erythema. Over the next few days, the patient's clinical status gradually worsened, despite improved radiological findings for the pulmonary infiltrate and pleural effusion.

Blood cultures showed the presence of *Staphylococcus aureus* and treatment with vancomycin was initiated. No other focus of infection was found, and both the electrocardiogram and the echocardiogram were normal. The masses previously detected in the chest wall increased in size and also presented clear signs of inflammation. At the same time, other collections were detected at the midaxillary line in the fourth, fifth and seventh intercostal spaces. Computed tomography confirmed bilateral involvement (figure). Needle biopsy of the collections confirmed the presence of the same pathogen as in the blood culture, and a needle biopsy of the pleural effusion found no infection. The abscesses were debrided; the patient improved and was discharged 15 days later.

The most important finding in the case we report is the extremely rare extension of staphylococcal sepsis to hematomas resulting from chest trauma.²⁻⁴ In our patient, the only way this event could have occurred was by hematogenous dissemination, since there was

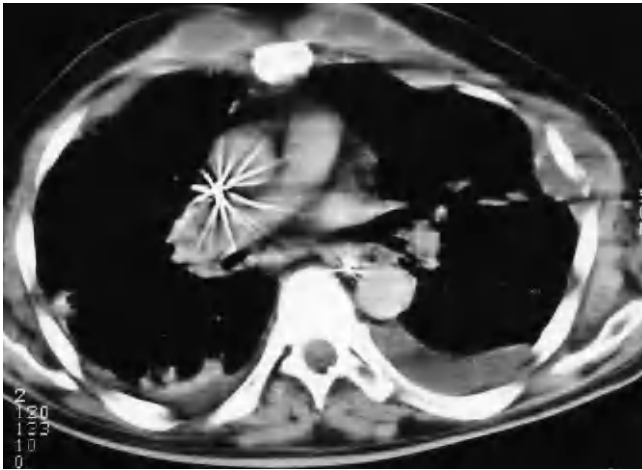


Figure. Computed tomography scan of the chest showing collections along the chest wall and in the left parasternal region.

no open wound. As the pleural effusion was not contaminated, superinfection of the chest wall hematomas was ruled out as the source. Although the primary focus of infection was not detected, it may have developed in the urinary tract, in an intravenous catheter, or even in the lung. The only possible treatment for these cases is by draining the collections and by administering systemic antibiotic therapy,⁵ as in our case. This case illustrates the possibility of bacteremic superinfection of hematomas due to blunt chest trauma. Such

hematoma superinfection is more often described in the sternal region²⁻⁴ and rarely in rib fractures.

Jorge Freixinet Gilart,^a Jorge Solé Violán,^b and Felipe Rodríguez de Castro^c

^aUnidad de Cirugía Torácica,
Hospital Universitario de Gran Canaria
Dr. Negrín, Las Palmas de Gran Canaria,
Las Palmas, Spain

^bUnidad de Medicina Intensiva, Hospital
Universitario de Gran Canaria Dr. Negrín,
Las Palmas de Gran Canaria, Las Palmas,
Spain

^cUnidad de Neumología,
Hospital Universitario de Gran Canaria
Dr. Negrín, Las Palmas de Gran Canaria,
Las Palmas, Spain

1. Hammainen P, Kostianen S. Postoperative necrotizing chest-wall infection. Case report of a rare complication after elective surgery. *Scand Cardiovasc J.* 1998;32:243-5.
2. Gregory MW, Jacobsen WM. Closed blunt chest trauma causing mediastinal abscess. *J Trauma.* 1996;41:899-901.
3. Cuschieri J, Kralovich KA, Patton JH, Horst M, Obeid FN, Karmy-Jones R. Anterior mediastinal abscess after closed sternal fracture. *J Trauma.* 1999;47:551-4.
4. Jayle CPM, Corbi PJ, Franco S, Menu PM. Destructive sternitis 3 years after blunt chest trauma. *Ann Thorac Surg.* 2005;80:348.
5. Burkhart HM, Deschamps C, Allen MS, Nichols FC III, Miller DL, Pairolero PC. Surgical management of sternoclavicular joint infections. *J Thorac Cardiovasc Surg.* 2003;125:945-9.