

Selective Lobar Blockade Using an Arndt Endobronchial Blocker in 2 Patients With Respiratory Compromise Who Underwent Lung Resection

Clara Espí, Roser García-Guasch, Cristina Ibáñez, Esther Fernández, and Julio Astudillo

Hospital Universitario Germans Trias i Pujol, Badalona, Barcelona, Spain

Selective lobar blockade is an alternative to one-lung ventilation in thoracic surgery. We present 2 cases of lung resection with severe respiratory compromise. The first patient had previously undergone a left lower lobectomy and 2 atypical resections in the left and right upper lobes and was scheduled for a right lower lobectomy. The second patient presented chronic obstructive pulmonary disease with forced vital capacity of 1200 mL (26% of predicted value) and forced expiratory volume in 1 second of 820 mL (25% of predicted value) and was scheduled for an atypical resection of the left upper lobe with pleural abrasion. Selective lobar blockade was achieved in both cases using an Arndt endobronchial blocker. Ventilation during the operation was sufficient. Surgery was uneventful in both cases and lobar collapse was satisfactory.

Key words: Thoracic surgery. Bronchial blockers. Arndt endobronchial blocker. Selective lobar blockade.

Bloqueo lobular selectivo mediante el bloqueador bronquial de Arndt en 2 pacientes con compromiso respiratorio sometidos a resección pulmonar

En cirugía torácica el bloqueo lobular selectivo representa una alternativa a la ventilación unipulmonar. Se presentan 2 casos de cirugía de resección pulmonar con un compromiso respiratorio grave. El primero, sometido anteriormente a una lobectomía inferior izquierda y 2 resecciones atípicas en lóbulos superiores izquierdo y derecho, se programó para una nueva lobectomía del lóbulo inferior derecho. El segundo paciente, que presentaba una enfermedad pulmonar obstructiva crónica grave con una capacidad vital forzada de 1.200 ml (26%) y volumen espiratorio forzado en el primer segundo de 820 ml (25%), se programó para resección atípica del lóbulo superior izquierdo con abrasión pleural. En ambos casos se consiguieron bloqueos lobulares selectivos con el bloqueador endobronquial de Arndt. La ventilación fue adecuada durante la intervención. La cirugía transcurrió sin incidencias en ambos casos y el colapso lobular fue correcto.

Palabras clave: Cirugía torácica. Bloqueadores bronquiales. Bloqueador bronquial de Arndt. Bloqueo lobular selectivo.

Introduction

Selective one-lung ventilation is required in thoracic surgery to allow the surgeon to view and manipulate the lung that is being operated on. Although the double-lumen tube is still the most commonly used instrument for this purpose, bronchial blockers are rapidly being introduced because they can provide greater advantages in some clinical situations. The first such device designed for this purpose was the bronchial blocker incorporated onto a single-lumen tube (Univent, Fuji Systems Corporation,

Tokyo, Japan).¹ The Arndt bronchial blocker was introduced later. This blocker is independent of the tracheal tube and can be positioned in the required bronchus using fiberoptic bronchoscopy. With blockade of the main bronchus, the target lung can be fully collapsed.^{2,3} One of the advantages of bronchial blockers over double-lumen tubes is that they can block 1 or 2 lobes, thus preventing the complete collapse of an entire lung. Very few cases have been published where the Arndt blocker has been used for this purpose and none where lung function is compromised.^{4,5}

We present 2 cases where an Arndt endobronchial blocker was used for selective lobar blockade. The first patient had a history of several lung resections and the second patient had severe chronic obstructive pulmonary disease.

Correspondence: Dra. C. Espí.
Hospital Universitario Germans Trias i Pujol.
Ctra. Canyet, s/n. 08916 Badalona. Barcelona. España.
E-mail: clara.espi@uv.es

Manuscript received May 26, 2006. Accepted for publication June 20, 2006.

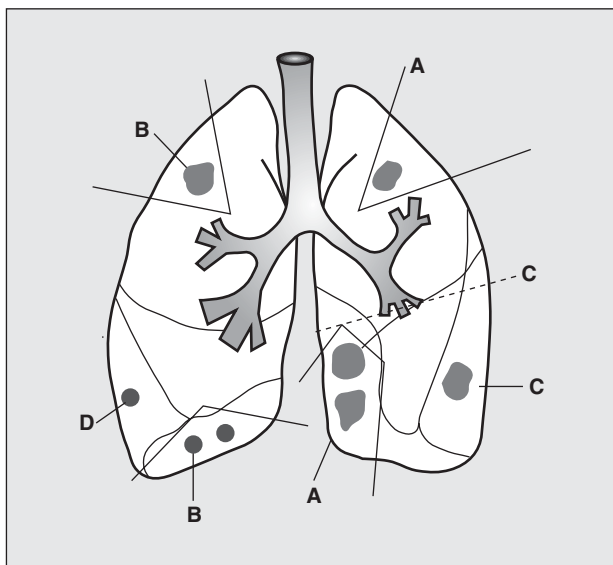


Figure 1. Diagram showing the different atypical resections and lobectomy in Case 1 prior to the left lower lobectomy. A indicates atypical resections of the left upper and lower lobes in January 2002; B, atypical resections of the right upper and lower lobes in February 2002; C, left lower lobectomy in August 2002; and D, diagnosis of a new nodule in February 2004. (Figure by C. Espí.)

Case Description

Case 1

A 73-year-old patient (class III according to the classification of the American Society of Anesthesiologists) was scheduled for elective right lower lobectomy. The patient had an adenocarcinoma of the sigmoid colon that had been resected 6 years previously (T3 N0 M0). In January 2002, the patient underwent an atypical resection of 2 nodules in the left lower lobe and 1 nodule in the left upper lobe. In February 2002, he underwent an atypical resection of a nodule in the right lower

lobe and another nodule in the right upper lobe. In August of the same year, he underwent a left lower lobectomy due to a new nodule (Figure 1).

The patient was scheduled for a further lobectomy due to the appearance of a new central nodule in the right lower lobe. At the time, the patient had part of the left upper lobe, part of the right upper lobe, and the right middle and lower lobes intact. According to ventilation-perfusion scintigraphy, perfusion was 67.7% in the right lung and 32.2% in the left lung. Lung function tests showed a forced vital capacity (FVC) of 2870 mL (66.2%), forced expiratory volume in 1 second (FEV₁) of 2100 mL (68.8%), and FEV₁/FVC of 0.73.

The patient was intubated without difficulty using a tube with an internal diameter of 8 mm. A 9-French Arndt endobronchial blocker (William Cook Europe A/S, Bjaeverskov, Denmark) was inserted into the bronchus intermedius to block the right middle and lower lobes (Figure 2). Once confirmed that the blocker was correctly positioned, the balloon was inflated with 6 mL of air. An aspirator was connected to the distal end of the blocker to facilitate collapse.

Surgery was uneventful. The patient presented oxygen saturation measured by pulse oximetry of 99% throughout the operation. While the chest was being closed, the balloon was deflated and the endobronchial blocker was withdrawn. The middle lobe re-expanded satisfactorily.

Case 2

A 62-year-old patient (class III according to the classification of the American Society of Anesthesiologists) was scheduled for elective atypical resection of the left upper lobe with resection of bullae and pleural abrasion. The patient had a history of severe chronic obstructive pulmonary disease and had undergone surgery for a rectal adenocarcinoma (T4 N0 M1). Follow-up computed tomography showed a nodule in the left upper lobe. According to arterial gasometry, basal PaO₂ was 68 mm Hg and basal PaCO₂ was 38 mm Hg. Lung function tests showed the following values: FVC of 1200 mL (26%), FEV₁ of 820 mL (25%), and FEV₁/FVC of 68%. Bronchodilator response was minimal. Positron emission tomography revealed increased uptake in the left upper lobe.

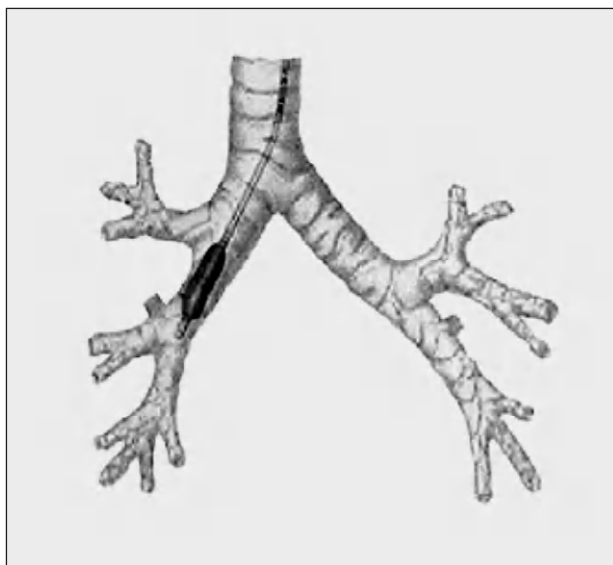


Figure 2. Placement of the endobronchial blocker in the bronchus intermedius in Case 1. (Figure by C. Ibáñez.)

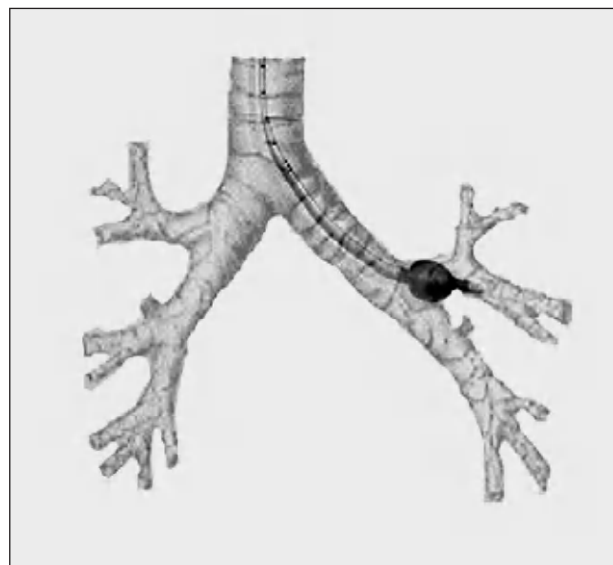


Figure 3. Placement of the endobronchial blocker in the bronchus of the left upper lobe. (Figure by C. Ibáñez.)

The patient was intubated using a tube with an 8-mm internal diameter. The left upper lobe was blocked using a 9-French Arndt endobronchial blocker (Figure 3). The balloon was inflated with 6 mL of air and satisfactory ventilation in the left lower lobe and absence of ventilation in the left upper lobe were confirmed by lung auscultation. When the blocker was in position, the guide was withdrawn and air was aspirated through the lumen of the blocker to collapse the lobe. Satisfactory collapse of the left upper lobe was confirmed when the chest was open. Surgery was uneventful. Oxygen saturation measured by pulse oximetry was above 97% at all times.

Discussion

The ability to block just one part of the lung made it possible to perform surgery in 2 cases of severe respiratory disease that would have otherwise made surgery and anesthesia inadvisable. Lung function was acceptable in the first patient (FEV₁, 2100 mL) but if a double-lumen tube had been used, isolating the right lung for surgery, only part of the left upper lobe would have been ventilated. In the second case, lung function was compromised (PaO₂ of 68 mm Hg and FEV₁ of 820 mL) and one-lung ventilation would have been problematic for the patient. Because satisfactory ventilation was achieved in both cases using the endobronchial blocker, it was not considered appropriate to verify whether one-lung ventilation would have been tolerated.

Lobar blockade has already been described by Campos,⁶ using a Univent bronchial blocker with which improved oxygenation was achieved following one-lung ventilation. Placement of the blocker in the bronchus intermedius improved oxygenation in a patient requiring a right lower lobectomy who had undergone a previous lobectomy and who did not tolerate one-lung ventilation.⁷

Only a few case reports have been published describing the use of an Arndt blocker in compromised patients. In the case reported by Ng and Hartigan,⁴ selective blockade of the right lower lobe made it possible to perform the lower stage of a right pleurectomy in a patient who had previously undergone a left pneumonectomy. In the case described by Campos and Kernstine,⁵ blockade of the left upper lobe in a patient who had previously undergone a right pneumonectomy made it possible to perform a

lingulectomy. Another alternative described for a case of right upper lobectomy in a patient who had previously undergone contralateral pneumectomy is high-frequency jet ventilation.⁸

Endobronchial blockade allows for satisfactory ventilation without the need for more sophisticated equipment that is not available in all operating theaters or hospitals.

Our second patient had not undergone a previous resection but lung function was extremely limited. We have not found any other cases with these characteristics in the medical literature.

The article by Ng and Hartigan⁴ describes one of the limitations of lobar blockade. Blockade of the right upper lobe may be very difficult due to the tight angle and the short distance between the entrance to the lobe and the subsequent branching.

In our experience, selective lobar blockade using an endobronchial blocker could provide a good alternative to one-lung ventilation in patients with compromised lung function.

REFERENCES

1. MacGillivray RG. Evaluation of a new tracheal tube with a movable bronchus blocker. *Anaesthesia*. 1988;43:687-9.
2. García-Guasch R, López de Castro P, Lucas M, Busquets J, Sariñena T, Muñoz S. Experiencia inicial con los bloqueadores bronquiales tipo Arndt en cirugía torácica. *Rev Esp Anestesiol Reanim*. 2005;52:19-23.
3. Campos JH. An update on bronchial blockers during lung separation techniques in adults. *Anesth Analg*. 2003;97:1266-74.
4. Ng JM, Hartigan PM. Selective lobar bronchial blockade following contralateral pneumonectomy. *Anesthesiology*. 2003;98:268-70.
5. Campos JH, Kernstine KH. Use of the wire-guided endobronchial blocker for one-lung anesthesia in patients with airway abnormalities. *J Cardiothoracic Vasc Anesth*. 2003;17:352-4.
6. Campos JH. Effects on oxygenation during selective lobar versus total lung collapse with or without continuous positive airway pressure. *Anesth Analg*. 1997;85:583-6.
7. Campos JH, Ledet C, Moyers JR. Improvement of arterial oxygen saturation with selective lobar bronchial block during hemorrhage in a patient with previous contralateral lobectomy. *Anesth Analg*. 1995;81:1095-6.
8. King BW, Gross KP. Right upper lobe resection after left pneumonectomy. *Anesthesiology*. 1994;81:771-3.