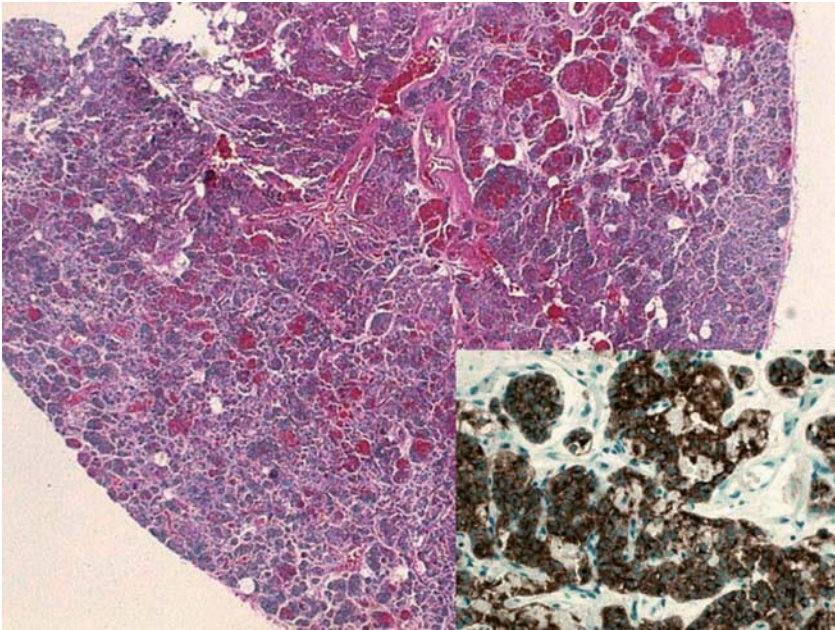


Mediastinal Parathyroid Gland or Adenopathy With Endocrine Cancer Infiltration?

To the Editor: Cervical mediastinoscopy is still the gold standard for preoperative lymph node staging of bronchogenic carcinoma. To a greater or lesser extent it forms part of all processes for diagnosing and treating this disease and is therefore a common surgical examination technique in thoracic surgery departments. Identification of diseased lymph nodes is visual. Their appearance is variable but generally characteristic, as they range from small fleshy nodules to large anthracotic lymph nodes to nodes that are completely calcified or have whitish spotting that suggests tumor infiltration.

We present the case of a 72-year-old man with a spiculated lung nodule 3 cm in diameter in the right upper lobe and diseased mediastinal lymph nodes at the limit of normal size. A transbronchial biopsy performed with a fiberoptic bronchoscope did not provide a diagnosis and it was not possible to perform fine-needle aspiration due to the central location of the nodule. Because lung cancer was suspected, positron emission tomography was performed in combination with computed axial tomography as part of the lymph node staging process. The results indicated mediastinal and right hilar involvement. Mediastinoscopy was performed to obtain histopathological confirmation of lymph node infiltration and samples were taken from stations 2R, 2L, 4Rs, 4Ri, 4Ls, 4Li, and 7. The pathologist's analysis



Fragment of the biopsy of a mediastinal parathyroid gland. The lymph node capsule and rounded shape can be seen. Inset: immunostaining that detected the presence of parathyrin in the gland.

of these samples revealed tumor infiltration only in the lymph node at 2L, which was initially reported as an "endocrine tumor with no lymph node tissue." As this was a surprising finding, the sample was studied again with immunostaining that revealed the presence of parathyrin in the prepared sample. The final report identified the structure as a "parathyroid gland" (Figure).

The presence of ectopic parathyroid glands in the mediastinum is not exceptional. They have been detected in 7% of autopsies and in up to 10% of series of patients with hyperparathyroidism.¹ They appear in 38% of cases where surgical treatment of hyperparathyroidism by means of cervical parathyroidectomy has failed.² The usual resection technique is medial sternotomy or,

more recently, video-assisted thoracoscopy—occasionally guided by scintigraphy.³ Resection by mediastinoscopy—a minimally invasive technique—has also been described.^{4,5} However, nothing was found in the literature on the incidental biopsy of an ectopic parathyroid gland during mediastinoscopy for lymph node staging in bronchogenic carcinoma. The first author of this letter has performed some 200 mediastinoscopy procedures and had never yet come across one.

The importance of this report is that it shows that a mediastinal parathyroid gland may be indistinguishable from an endocrine tumor at the same site in the initial pathologic examination using conventional staining techniques. In patients whose primary tumor is

also endocrine cancer, this finding can mistakenly lead us to consider that the disease has spread to the lymph nodes. Detecting parathyrin by means of immunostaining, however, makes it possible to distinguish between endocrine cancer with mediastinal infiltration and an ectopic parathyroid gland in the mediastinum—a possibility that should be considered when evaluating the pathology report. This case also shows that abnormalities revealed by positron emission tomography require mediastinoscopy to obtain samples for histologic confirmation of lymph node infiltration.

**Francisco Javier Moradiellos Díez,^a
Isabel Salas Villar,^b
and Clara Salas Antón^b**

^aServicio de Cirugía Cardiovascular
y Torácica,
Hospital Universitario Puerta de Hierro,
Madrid, Spain
^bServicio de Anatomía Patológica,
Hospital Universitario Puerta de Hierro,
Madrid, Spain

1. Sitges-Serra A, Sancho JJ, Pereira JA, Girvent M, Pascual M, Berná L. Hiperparatiroidismos debidos a glándulas paratiroides de localización torácica. *Cir Esp*. 2003; 73:213-7.
2. Clark OH. Mediastinal parathyroid tumors. *Arch Surg*. 1998;123:1096-100.
3. Barriga-Sánchez R, Larrañaga E, García JL, Tamura A, Pun Y, Martín E. Nueva técnica quirúrgica para glándulas paratiroides intratorácicas: la videotoroscopia con detección de Tc-MIBI intraoperatoria. *Cir Esp*. 2006;79:255-7.
4. Ohno K, Kuwata K, Yamasaki Y, Yamasaki H, Hatanaka N, Yamamoto S. Mediastinoscopic extirpation of mediastinal ectopic parathyroid gland. *Ann Thorac Surg*. 1997; 64:238-40.
5. Adinolfi M, Browder W, Wallin JD, Jones JW. Excision of mediastinal parathyroid gland by mediastinoscopy. *South Med J*. 1983;76:1496-7.