

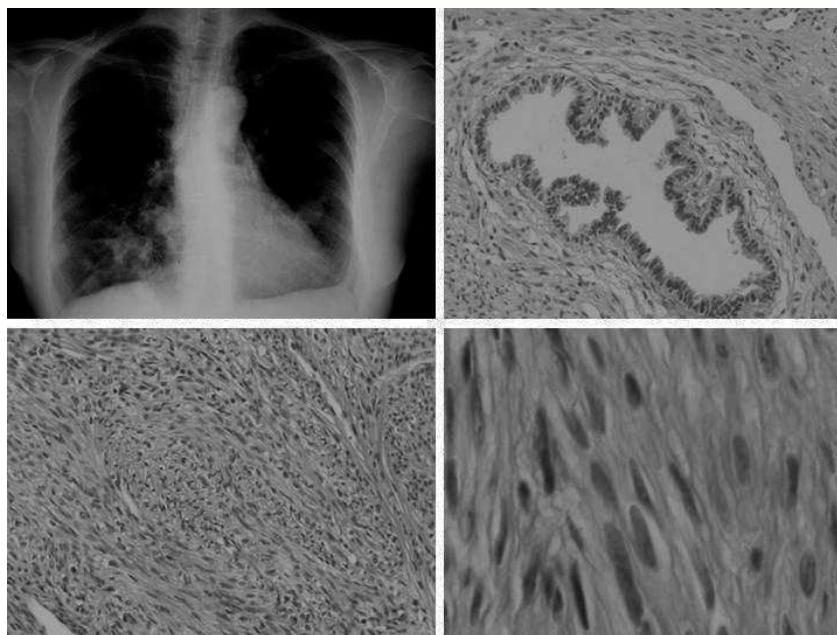
Benign Metastasizing Leiomyoma of the Lung

To the Editor: Benign metastasizing leiomyoma is the term used to describe the disease characterized by extrauterine leiomyomatous lesions without histologic or cytologic signs of malignancy. Clinically and radiologically such lesions simulate metastatic behavior in patients with a history of uterine leiomyomas.

We present the case of a 54-year-old woman who underwent a total hysterectomy (with double adnexectomy) due to multiple myomas. Adenomyosis and an endometrial polyp were observed in the excised tissue. An anteroposterior chest x-ray performed in a preoperative study in relation to the uterine disease revealed multiple pulmonary nodules (cannonballs), as seen in the figure, and the patient was referred to the pneumology department for examination. Computed tomography of the thorax revealed multiple nodular and solid images of varying size, distributed in both lung fields in a diffuse multinodular pattern. These findings were indicative of metastatic lung disease of an unidentified primary tumor. No enlarged mediastinal nodes or retroperitoneal masses were observed. A colonoscopy was negative, as were postoperative cytology of respiratory samples and fiberoptic bronchoscopy. The patient was referred to the chest surgery unit for wedge resection biopsy of 2 bilateral pulmonary nodules by video-assisted thoracoscopic surgery. The lesions had diameters of 2.5 cm and 2 cm at the largest part, were fasciculated, and had a whitish tone and firm consistency, resistant to the cut. Histology revealed a lesion formed of spindle cells with slightly eosinophilic cytoplasm and central fusiform cigar-shaped nuclei with regular outlines and no evident nucleoli, atypia, or mitosis. Thorough examination of the excised tissue did not reveal foci of tumor necrosis, pleomorphic regions, or increased cellular atypia. All these findings of histology together with the clinical history and condition of the patient led to a diagnosis of benign metastasizing leiomyoma of the lung. After 2 years of follow-up, the patient has not presented symptoms attributable to her disease nor needed specific treatment.

Although the term benign metastasizing leiomyoma has not been used widely, it has not been wholly accepted as many authors find it does not danfy the real nature of the lesion. Many authors deny the existence of this type of lesion, arguing that a tiny specimen of each of the supposed metastatic lesions, together with the primary uterine lesion, would demonstrate that they are really low-grade leiomyosarcomas. In fact, careful review of published cases has led to the rejection of many although a significant number have not been refuted. In support of the existence of such lesions, however, it is important to say that primary smooth-muscle neoplasms of the lung are very unusual and most cases described have been positive for estrogen receptors and many have responded well to hormone therapy.¹

In any case, criteria are needed to distinguish a malignant smooth muscle lesion from a benign one (leiomyosarcoma compared



Anteroposterior chest x-ray (upper left image) and microscopic details of the lesion (magnification [20 and [40).

with leiomyoma) so that the true nature of lesions can be determined. The following parameters have been used to that end: tumor necrosis, cell atypia, and the mitosis index. However, there is another series of secondary parameters which also help determine the true nature of a lesion. These are the age of the patient, the size of the tumor, its macroscopic appearance, and, of course, invasion of the veins and adjacent structures, which are directly indicative of malignancy.^{2,3} None of these were present in our patient, leading us to believe we had a real case of benign metastasizing leiomyoma. The second problem that must be solved is the confusing terminology used. While we have used the terminology included in the latest classification of the World Health Organization, we think that it could cause errors or confusion among clinicians, surgeons, and pathologists. For this reason we think a name like leiomyomatosis of the lung in a patient with a history of uterine leiomyomatosis, although long and tortuous, is more descriptive and would probably help resolve the dispute. In addition, new studies are being published which defend the metastatic nature of these lesions by demonstrating their monoclonality through sophisticated techniques such as comparative genomic hybridization and analysis of the inactivity of the X chromosome.⁴

The differential diagnosis concerns metastasis of leiomyosarcoma, primary pulmonary leiomyomatosis (no history of related gynecological lesions), lymphangioliomyomatosis, and the so-called fibroleiomyomatous hamartoma, although the clinical characteristics described seem specific and differ from those of the other entities. Prognosis is good and depends on the extension of the pulmonary nodules because, even though progression is usually

slow, massive pulmonary invasion has been observed with its consequent morbidity; as these cases are usually accompanied by symptoms we can say that their presence is associated with greater morbidity.

Conventional treatment is surgery (nodulectomy and/or oophorectomy), although hormone therapy (modulators of estrogen receptors, aromatase inhibitors, analogues of the luteinizing, and prostagenic agents) has the advantage of causing less morbidity and mortality and good results have been reported.^{5,6}

**Francisco Javier Torres Gómez,^a
Andrés Arroyo Tristán,^b
and Francisco Javier Torres Olivera^a**
^aDepartamento de Anatomía Patológica,
Hospital Universitario Virgen Macarena,
Sevilla, Spain.
^bServicio de Cirugía Torácica,
Hospital Universitario Virgen Macarena,
Sevilla, Spain.

1. Goyle KK, Moore DF Jr, Garrett C, Goyle V. Benign metastasizing leiomyomatosis: case report and review. *Am J Clin Oncol.* 2003;26:473-6.
2. Barbetakis N, Xenikakis T, Efstathiou A, Vlahueis M, Fessatidis I. Pulmonary benign metastasizing leiomyoma. *J Cardiovasc Surg.* 2004;45:399-400.
3. Funakoshi Y, Sawabata N, Takeda S, Hayakawa M, Okumira Y, Maeda H. Pulmonary benign metastasizing leiomyoma from the uterus in a postmenopausal woman: report of a case. *Surg Today.* 2004;34:55-7.
4. Tietze L, Gunther K, Horbe A, Pawlik C, Klosterhalfen B, Handt S, et al. Benign metastasizing leiomyoma: a cytogenetically

LETTERS TO THE EDITOR

- balanced but clonal disease. *Human Pathol.* 2000;31:126-8.
5. Rivera JA, Christopoulos S, Small D, Trifiro M. Hormonal manipulation of benign metastasizing leiomyomas: report of a two cases and review of the literature. *J Clin Endocrinol Metab.* 2004;89:3183-8.
 6. Hague WM, Abdul Wahid NA, Jacobs HS, Graft I. Use of LHRH analogue to obtain reversible castration in a patient with benign metastasizing leiomyoma. *Br J Obstet Gynaecol.* 1986;93:455-60.