

Constrictive Pericarditis As the First Sign of Lung Cancer

Luis Mateos Caballero,^a Juan Manuel Nogales Asensio,^b Rafael Alonso González,^b Juan José Garrido Romero,^c Reyes González Fernández,^b and Antonio Manuel Pérez Fernández^c

^aSección de Neumología, Hospital de Mérida, Mérida, Badajoz, Spain.

^bSevicio de Cardiología, Hospital Infanta Cristina, Badajoz, Spain.

^cServicio de Neumología, Hospital Infanta Cristina, Badajoz, Spain.

Symptoms such as cough and hemoptysis in patients with lung cancer can be the consequence of local bronchopulmonary disease, tumor growth that leads to compression of surrounding structures, distant metastases, diverse systemic effects (anorexia, asthenia, weight loss), or paraneoplastic syndromes associated with tumor production of certain hormones. Approximately 10% of patients are asymptomatic at diagnosis. We report the case of a 77-year-old man with dyspnea, pleuritic chest pain, and lower limb edema. The patient died within a few days. The cause of the clinical picture was constrictive pericarditis secondary to metastases from lung carcinoma.

Key words: Lung cancer. Constrictive pericarditis. Metastases from lung cancer.

Introduction

Metastatic involvement of the pericardium is a common cause of pericardial effusion that can occasionally lead to cardiac tamponade. Pericardial constriction, however, is a very rare manifestation of such metastatic involvement.

We describe the case of a patient who developed pericardial constriction and cardiogenic shock with fatal outcome as the first manifestation of lung cancer.

Case Description

The patient was a 77-year-old man, ex-smoker of 60 pack-years, with a history of low-grade papillary bladder cancer that was treated with transurethral resection one year before. He was on a regimen of bacille Calmette-Guérin treatment. Urography performed during his last check up revealed an

Pericarditis constrictiva como primera manifestación de carcinoma pulmonar

Los síntomas que presentan los pacientes con cáncer de pulmón pueden ser la consecuencia de una enfermedad broncopulmonar local (tos, hemoptisis, etc.), deberse a la extensión del tumor hacia las estructuras circundantes, a metástasis a distancia, a efectos sistémicos inespecíficos (anorexia, astenia, pérdida de peso) o a síndromes paraneoplásicos secundarios a la producción de determinadas hormonas por el tumor. En torno al 10% de los pacientes se encuentran asintomáticos en el momento del diagnóstico.

Presentamos el caso de un paciente varón de 77 años de edad, que presentaba disnea, dolor torácico de tipo pleurítico y edemas en los miembros inferiores. Su evolución fue fatal, falleciendo al cabo de pocos días. La causa de la clínica era la existencia de pericarditis constrictiva secundaria a metástasis de carcinoma pulmonar.

Palabras claves: Carcinoma pulmonar. Pericarditis constrictiva. Metástasis de pulmón.

image suggestive of a kidney cyst or tumor, requiring confirmation of the origin by magnetic resonance imaging.

He came to the emergency department of our hospital complaining of shortness of breath with moderate exercise starting 2 weeks earlier, edema in the lower limbs, and pleuritic chest pain. Physical examination revealed pitting edema in the lower limbs and sounds were absent upon percussion at the base of the right lung. The patient was eupneic with no orthopnea. Heart sounds were normal.

Laboratory results showed slightly elevated levels of aspartate aminotransferase (52 U/L), γ -glutamyl transpeptidase 210 U/L, and alkaline phosphatase 263 U/L; mild hypoproteinemia (total proteins, 6.1 g/dL; albumin: 3.2 g/dL); abnormal coagulation (prothrombin activity, 49%); an elevated D dimer level (907 nmol/L), and an erythrocyte sedimentation rate of 40 mm/h. Arterial blood gas analysis showed the following resting values: pH was 7.48; PaCO₂, 26 mmHg; PaO₂, 72 mmHg; bicarbonate (HCO₃⁻), 20 mEq/L; and arterial oxygen saturation, 95%. Electrocardiography revealed sinus rhythm, decreased voltage, and nonspecific repolarization abnormalities. A chest radiograph showed right-sided pleural effusion. Ventilation-perfusion scintigraphy indicated a low probability of pulmonary embolism.

The patient was admitted to the pulmonology department for study of the right pleural effusion. Fluid obtained by diagnostic thoracentesis was bloody and had a pH of 7.54, a

Correspondence: Dr. L. Mateos Caballero.
Sección de Neumología, Hospital de Mérida.
Polígono Nueva Ciudad, s/n. Mérida. Badajoz
E-mail: luismateoscab@yahoo.es

Manuscript received January 3, 2006. Accepted for publication February 21, 2006.

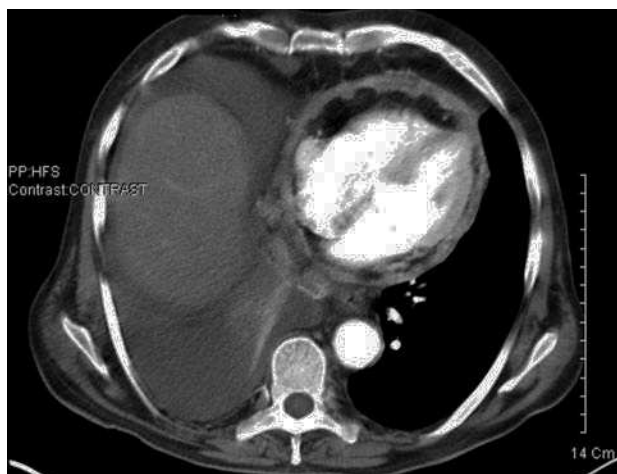

Figure 1. A chest computed tomography scan showing irregular circumferential thickening of the pericardium with no effusion, indicative of constrictive pericarditis. Right pleural effusion is also visible.

red cell count of 28 800 cells/ μ L, a white cell count of 160 cells/ μ L, a glucose concentration of 115 mg/dL, a protein concentration of 2.9 mg/dL, a lactate dehydrogenase (LDH) level of 181 U/L, cholesterol level of 48 mg/dL, and adenosine desaminase of 14.5 U/L. According to Light's criteria, the fluid was a transudate (pleural fluid protein/serum protein ratio, 0.47; pleural fluid LDH/serum LDH ratio, 0.59). Pleural fluid cytology was negative for malignancy.

Echocardiography revealed increased density suggestive of pericardial fat on the anterior pericardium, and dilatation of the inferior vena cava; the results of the rest of the study were normal. A chest computed tomography scan showed circumferential pericardial thickening (Figure 1), which confirmed the presence of right pleural effusion; there were no other abnormal findings.

The patient's clinical manifestations worsened, with increased dyspnea, chest discomfort, and edema. Physical examination detected tachypnea, orthopnea, jugular venous distension, diminished right vesicular murmur, hepatomegalia,

and generalized edema (anasarca). Urination was scant, with a positive water balance. Deterioration was apparent in liver function: aspartate aminotransferase level 191 U/L, alanine aminotransferase 190 U/L, LDH 434 U/L, γ -glutamyl transpeptidase 346 U/L, and alkaline phosphate 359 U/L; in coagulation: prothrombin activity 39% of predicted; and in kidney function: creatinine clearance 30 mL/min. Moderate hyponatremia (128 mEq/L) was also noted.

In view of the diagnosis of pericardial constriction with evident clinical and hemodynamic deterioration, the patient was transferred to the coronary care department. In the cardiac surgery unit pericardiectomy was ruled out due to high surgical risk. The patient's deteriorated hemodynamic condition progressively worsened and multiorgan failure set in; he died within a few hours.

Autopsy reported a 3.5-cm tumor in the right middle lobe adjacent to the surface of the heart, enlarged paratracheal nodes (the largest, 2.5 cm), and enlarged subcarinal nodes (the largest, 8 cm). The parietal pericardium adhered firmly, was whitish and fibrous in appearance, and had thickened to 3 mm. The pericardial effusion was sanguinous. The visceral pericardium had thickened and presented numerous whitish tumor-like nodules (Figure 2). A whitish 2-cm tumor node was detected in the right atrium. The thoracic aorta was firmly adhered to the lung tumor.

Under a microscope, it was evident that the right middle lobe tumor had invaded the adjacent pleura, the pericardium, epicardial fat, the right atrium, and the periaortic adipose tissue. The tumor was composed of large epithelial cells with areas of intense necrosis and an elevated mitotic index. Also described were peritumoral pneumonia, and paratracheal and subcarinal nodes with carcinomatoid metastases.

In conclusion, the diagnosis was severe pericardial constriction of metastatic origin as the first manifestation of large cell carcinoma with the traits of squamous cell lung cancer.

Discussion

Metastatic involvement of the heart is much more common than primary tumors and is usually

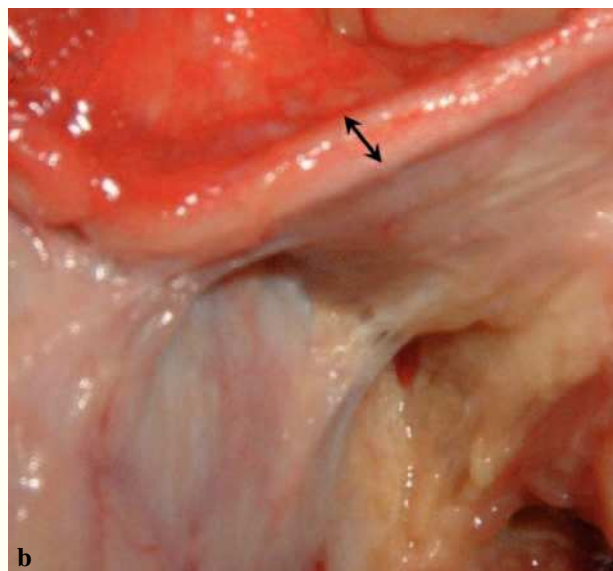
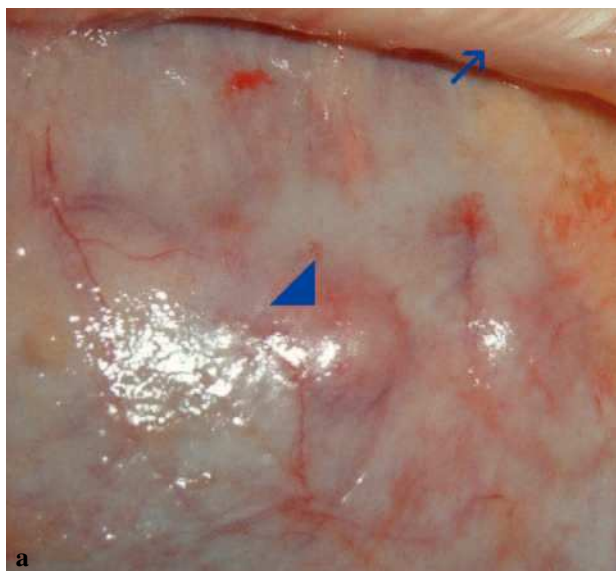


Figure 2. Macroscopic and histologic findings: a) whitish nodules in the pericardial visceral layer and adhered parietal layer, and b) thickened parietal pericardium.

underestimated. The prevalence of such metastatic involvement in case series has ranged from 15% to 30% of autopsies performed for cases of neoplastic disease and 4% of general autopsies.¹ Only tumors of the central nervous system have never been shown to metastasize to the heart. The most recent observational studies conclude that the primary cancers most commonly metastasizing to the heart are melanoma and breast and lung tumors; the most common cell type is adenocarcinoma.² Cardiac involvement can develop by retrograde lymphatic, hematogenic, direct, or transvenous extension. The cardiac location of the tumor depends on the path of dissemination. Lymphatic spread is usually to the pericardium and this is the most common metastatic pathway. In contrast, hematogenous spread usually produces myocardial metastasis and, much less commonly, endocardial involvement.³

Lung cancer is the most common primary tumor in patients with cardiac metastasis, which is generally located in the pericardium and epicardium—locations indicating direct and/or retrograde lymphatic spread.¹ The latter pathway—the most common—is found in mediastinal lymphatic vessels and moves cells toward the heart, seeding the epicardial surface with small tumors. The visceral layer of the pericardium contains most of the lymphatic vessels draining the pericardial space. These vessels empty into a zone at the aortic root. In the event of tumor extension, this lymphatic drainage easily becomes obstructed, thus causing pericardial effusion.

Cardiac involvement generally goes undetected due to the overriding preponderance of primary tumor symptoms. Thus, metastatic spread to the heart often goes undetected until autopsy.⁴ On other occasions the secondary neoplastic disease of the pericardium may lead to pericardial effusion, the most common complication of which is cardiac tamponade.⁵ Pericardial constriction by diffuse pericardial thickening of metastatic origin is a rare complication, and it would be unusual for such constriction to be the first manifestation of the neoplastic process.^{6,7} In severe pericardial involvement, cardiac tamponade, or

pericardial constriction, the symptoms are dyspnea (generally disproportionate to the radiologic findings), edema in the lower limbs, hepatomegaly, pleural effusion, and signs of low cardiac output.

Pericardial diseases (pericarditis, effusion, constriction, etc) call for a broad differential diagnosis. Given our patient's history of bladder cancer, tumor metastasis was the most probable diagnosis. Granulomatous reactions in many organs have been reported in the context of bacille Calmette-Guérin regimens⁸; therefore such reactions had to be ruled out as a cause of the pericardial thickening in the present case. Given the rapid evolution of our patient's clinical picture and the clinical absence of a primary tumor, the etiologic diagnosis could be made only at postmortem examination. Lung cancer is the primary tumor that most frequently metastasizes to the pericardium. Pericardial constriction is extremely rare, and as the only manifestation of the disease, as in the present case, it is even rarer.

REFERENCES

1. Abraham KP, Reddy V, Gattuso P. Neoplasm metastatic to the heart: review of 3314 consecutive autopsies. *Am J Cardiovasc Pathol.* 1990;3:195-8.
2. Klatt EC, Heitz DR. Cardiac metastases. *Cancer.* 1990;65:1456-9.
3. Chiles C, Woodard P, Gutiérrez F, Link K. Metastatic involvement of the heart and pericardium: CT and MR imaging. *Radiographics.* 2001;21:439-49.
4. Adenle AD, Edwards JE. Clinical and pathologic features of metastatic neoplasms of the pericardium. *Chest.* 1982;81:166-9.
5. Balghith M, Taylor DA, Jugdutt BI. Cardiac tamponade as the first clinical manifestation of metastatic adenocarcinoma of the lung. *Can J Cardiol.* 2000;16:925-7.
6. Tsolakis EJ, Charitos CE, Mitsibounas D, Nanas JN. Cardiac tamponade rapidly evolving toward constrictive pericarditis and shock as a first manifestation of noncardiac cancer. *J Card Surg.* 2004;19:134-5.
7. Laurat E, Revest M, Djenidi M, Decaux O, Jego P. Constrictive pericarditis as first manifestation of neoplasia. *Ann Med Interne (Paris).* 2003;154:249-51.
8. Lamm DL. Complications of bacillus Calmette Guerin immunotherapy. *Urol Clin North Am.* 1992;19:565-72.