

# High-Resolution Computed Tomography Patterns of Organizing Pneumonia

Alberto Bravo Soberón,<sup>a</sup> María Isabel Torres Sánchez,<sup>a</sup> Francisco García Río,<sup>b</sup> Carlos Sánchez Almaraz,<sup>a</sup> Manuel Parrón Pajares,<sup>a</sup> and Mercedes Pardo Rodríguez<sup>a</sup>

<sup>a</sup>Servicio de Radiodiagnóstico, Hospital Universitario La Paz, Madrid, Spain.

<sup>b</sup>Servicio de Neumología, Hospital Universitario La Paz, Madrid, Spain.

Organizing pneumonia is an uncommon lung disease with a wide variety of radiologic findings, few of which have been discussed in the literature. We performed high resolution computed tomography on 34 patients with a histological diagnosis of organizing pneumonia and studied the images they presented. Twenty-five of the cases were idiopathic and 9 secondary. The findings observed were parenchymal consolidation (76%), ground glass opacity (59%), bronchial dilatation (53%), centrilobular nodules (35%), septal thickening (23%), halo sign (15%), and reversed halo sign (12%). Secondary cases presented more findings of septal thickening and fewer complete remissions.

**Key words:** High resolution computed tomography. Organizing pneumonia. Bronchiolitis obliterans organizing pneumonia. Reversed halo sign.

## Introduction

Organizing pneumonia, described for the first time by Davison et al<sup>1</sup> in 1983, is an uncommon lung disease. Epler et al<sup>2</sup> called it "bronchiolitis obliterans organizing pneumonia" but the term "organizing pneumonia" is preferred in order to avoid confusion with airway diseases such as constrictive bronchiolitis obliterans.<sup>3</sup> The disease can be idiopathic (cryptogenic organizing pneumonia) or be associated with collagen disease,<sup>4-5</sup> infections, medication,<sup>6</sup> radiotherapy, or systemic diseases including cancer.<sup>7</sup>

High resolution computed tomography (HRCT) is the gold standard in all diffuse interstitial lung disease

Patrones de presentación de la neumonía organizada mediante tomografía computarizada de alta resolución

La neumonía organizada es una enfermedad pulmonar poco frecuente, con gran variabilidad en los hallazgos radiológicos, de la que hasta el momento existe un escaso número de casos en la mayoría de los estudios publicados en la bibliografía.

Hemos estudiado mediante tomografía computarizada de alta resolución 34 casos con diagnóstico histológico establecido de neumonía organizada valorando los diferentes patrones de presentación. De estos casos, 25 fueron idiopáticos y 9 secundarios. Los hallazgos observados fueron: consolidaciones parenquimatosas (76%), vidrio deslustrado (59%), dilataciones bronquiales (53%), nódulos centrolobulillares (35%), engrosamientos septales (23%), signo del halo (15%) y signo del halo invertido (12%). Se observó una mayor presencia de engrosamientos septales y un menor número de remisiones completas en los casos secundarios.

**Palabras clave:** Tomografía axial computarizada de alta resolución. Neumonía organizada. Bronquiolitis obliterante con neumonía organizada. Signo del halo invertido.

exploration, detecting abnormalities not seen on normal chest x-rays. It is used to assess the extent and type of lesion and as a guide to choose the site for lung biopsy.<sup>3</sup> However, the low incidence of organizing pneumonia means that most studies published have few patients and patterns of presentation.

In a retrospective analysis of the HRCT of 34 cases of organizing pneumonia between 1998 and 2004, we assess the role of this method in the diagnosis of organizing pneumonia, the various patterns of presentation and the findings that can lead to accurate differential diagnosis and distinguish idiopathic from secondary types.

## Description of Cases

Between January 1998 and October 2004, organizing pneumonia was histologically diagnosed in 17 men and 17 women. The patients' mean age was 53 years (range,

Correspondence: Dr. A. Bravo Soberón.  
Servicio de Radiodiagnóstico, Hospital Universitario La Paz.  
P.º de la Castellana, 261. 28046 Madrid, España.  
E-mail: beldar24@hotmail.com

Manuscript received July 12, 2005. Accepted for publication January 17, 2006.

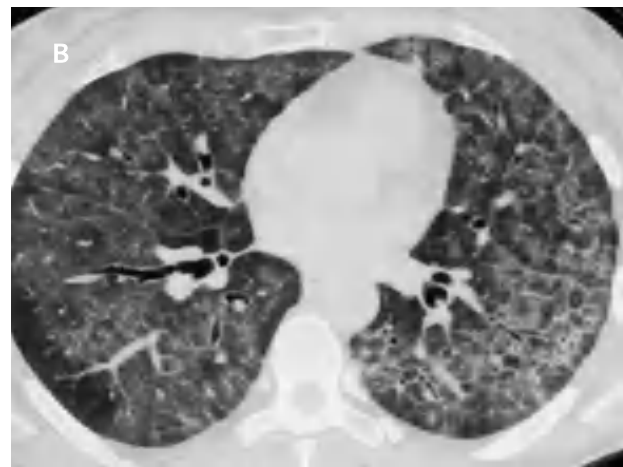
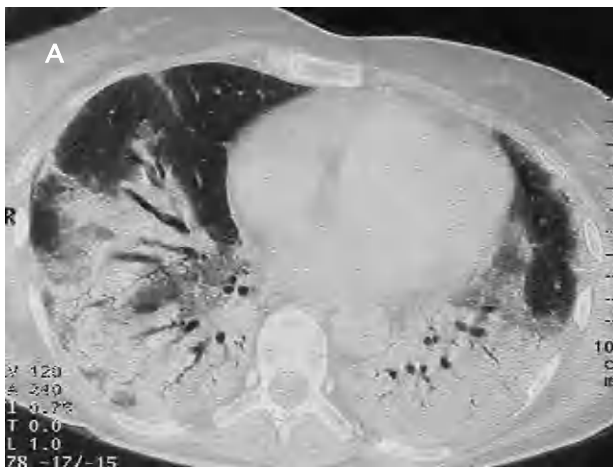

Figure 1. Patient 51 years of age with polymyalgia rheumatica (A): axial scan of 1 mm collimation showing extended parenchymal consolidation in both lower lobes, with dilated bronchioles in the interior. Patient with rheumatoid arthritis who presented dyspnea and dry cough (B): high resolution computed tomography of the lung bases revealed diffuse ground glass opacities, dilated bronchioles, and patchy subpleural septal thickening.

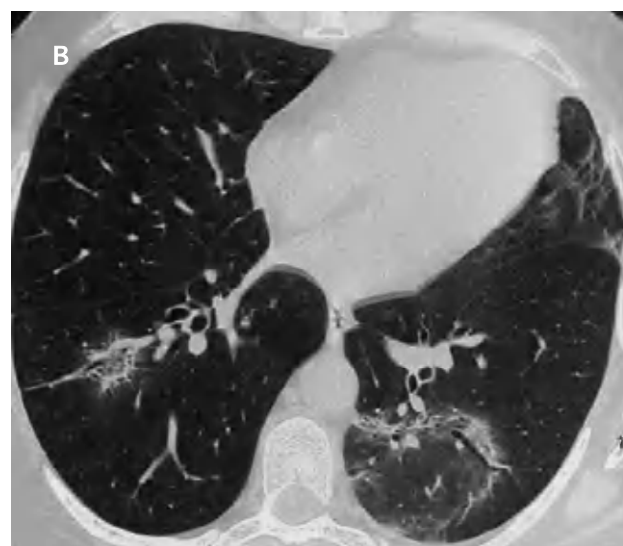
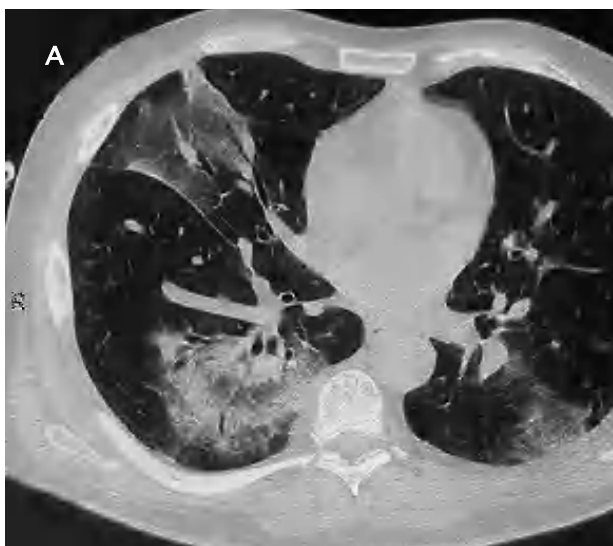
Figure 2. High-resolution computed tomography of the point of entrance of the pulmonary veins (A): ground glass opacity with dilated bronchioles in the middle lobe and peribronchovascular pseudonodular consolidation with the halo sign in the lower right lobe. Axial scan of 1mm collimation at the level of the basal pyramids (B): pseudonodular parenchymal consolidation with reversed halo sign in the left lower lobe and to a lesser extent in the right lower lobe.

22-87 years). Diagnosis was made with open lung biopsy in 28 patients and transbronchial biopsy in the remaining 6. HRCT was performed on all patients with a Somatom Plus 4 A scan (Siemens Medical Systems, Forchheim, Germany) following established guidelines: 1-mm collimation at 10-mm intervals, high resolution reconstruction algorithm, with kilovolts and milliamperes adjusted to the patient's weight. Of the 34 patients studied, 25 (73%) had no associated diseases and they were therefore classified as having cryptogenic organizing pneumonia. Of the 9 remaining patients, organizing pneumonia was secondary to rheumatoid arthritis in 2, breast cancer treated with chemotherapy in another 2, and bone marrow transplant in another 2. One patient had had zoster herpes treated by carbamazepine, 1 presented polymyositis, and 1

polymyalgia rheumatica.

The most common radiologic finding was the presence of parenchymal consolidation, which appeared in 26 (76%) patients; 19 of them were bilateral with slight predominance of middle and lower lobe involvement. The consolidations were patchy in 85% of patients, subpleural in 57%, and peribronchovascular in 62%.

The second most common finding was ground glass opacity which was observed in 20 patients (59%), bilateral in all but 1 patient, and slightly more common in middle and lower lobes. Bronchial dilatation in regions of parenchymal consolidation or ground glass opacity was found in 18 patients (53%).

Centrilobular nodules—10 of which were bilateral—were found in 12 patients (35%), mainly in upper lobes,

with patchy distribution in all cases. In 8 patients (23%), peripheral bilateral septal thickening was revealed; distribution was patchy and there was a certain predilection for the middle and lower lobes (Figures 1A and 1B).

The halo sign was seen in 5 patients (15%) and the reversed halo sign in 4 (12%), 1 in the upper lobe and 3 in the lower lobes. Two of the 4 patients with reversed halo sign had idiopathic disease and 2 had secondary forms, 1 to breast cancer and 1 to rheumatoid arthritis (Figures 2A and 2B).

No differences were found between the radiologic findings in patients with cryptogenic forms in comparison with organizing pneumonia secondary to other processes, except for septal thickening, which appeared in 4 of the 8 patients with organizing pneumonia secondary to another process (44%) compared with 4 of the 25 patients (16%) with cryptogenic organizing pneumonia.

Complete recovery was achieved in 24 patients (73%) and partial in 5 (15%) following prednisone treatment. More patients with idiopathic than secondary forms achieved complete recovery (88% compared with 33%). Four patients (12%) suffered remission after treatment cessation, 1 patient died from complications derived from bone marrow transplant and a patient with organizing pneumonia secondary to rheumatoid arthritis developed progressive pulmonary fibrosis.

## Discussion

Organizing pneumonia is an uncommon lung disease characterized by the presence of patches of granulation tissue polyps in the interior of the alveoli, alveolar ducts, and, to a lesser extent, in the bronchioles (Masson bodies) associated with focal organizing pneumonia. Earlier studies have indicated that the most common HRCT findings were areas of bilateral consolidation, predominantly subplural or peribronchovascular, associated with ground glass opacity. Lee et al<sup>8</sup> studied the computed tomography findings of 43 patients with cryptogenic organizing pneumonia, but HRCT was only used on 23. Parenchymal consolidation was observed in 79% of patients, ground glass opacity in 60%, and nodules or masses in 13%. Likewise, in a review published by the American Thoracic Society,<sup>9</sup> airway consolidations were more frequent (90% of patients) with peribronchial or subpleural distribution in over half with slight predilection for lower lung fields, and ground glass opacity was seen in 60%. In our study parenchymal consolidation was less frequent and when present was mostly subpleural or peribronchovascular, mainly affecting the lower lobes. With regard to ground glass opacity, our rates were similar to those of the studies mentioned, the pattern normally being associated with regions of consolidation.

Findings in other studies have varied, although both parenchymal consolidation and ground glass opacity are usually the more frequent patterns.<sup>10-14</sup> The discrepancy can be explained by the fact that some of the HRCT

explorations in our study were performed after prednisone treatment had been started, resulting in the disappearance of radiographic signs.

Bronchial dilatation normally appears in regions with airway consolidation, as Mihara et al<sup>12</sup> observed in 43% of patients, Kim et al<sup>13</sup> in 35%, and Arakawa et al<sup>14</sup> in 58%. In our series this finding appeared in 53% of patients, always associated with parenchymal consolidation or ground glass opacity. The rates of centrilobular nodules have ranged from 29% in the study by Mihara et al<sup>12</sup> to 63% in one by Johkoh et al<sup>11</sup>; in our series they occurred in about a third of patients and were mainly bilateral.

Several series have observed peripheral septal thickening,<sup>10-14</sup> which could be related to the stage of the disease or to related disorders such as connective tissue diseases in which fibrosis may occur to a greater extent. In our study occurrence was relatively low, predominantly in the lower lobes, and always bilateral.

One patient with associated rheumatoid arthritis presented progressive pulmonary fibrosis with a bibasilar reticular pattern. This pattern is more common in organizing pneumonia associated with connective tissue diseases, in which prognosis is poorer than in idiopathic forms.

In a study of 31 patients with cryptogenic organizing pneumonia, Kim et al<sup>13</sup> observed the presence of the reversed halo sign in 19% of patients. They examined the incidence of that sign in diseases with similar radiologic characteristics such as Wegener's granulomatosis, diffuse bronchioalveolar carcinoma, chronic eosinophilic pneumonia, or Churg-Strauss syndrome, finding that the reversed halo sign was never identified in those other diseases and concluding that the sign was sufficiently specific to establish a diagnosis of cryptogenic organizing pneumonia. More recently, Gasparetto et al<sup>16</sup> described this sign in 10% of patients with pulmonary paracoccidioidomycosis, so it would appear not to be as specific to organizing pneumonia as assumed.

We identified the reversed halo sign in 4 patients (12%) with organizing pneumonia—2 of them cryptogenic and 2 secondary—an indication that the sign does not only appear in idiopathic patients but may present in any patient with organizing pneumonia.

One of our patients presented organizing pneumonia associated with polymyalgia rheumatica, to our knowledge the third case described in the literature.<sup>17,18</sup>

In conclusion, HRCT helps identify the radiologic signs that characterize organizing pneumonia. There are no specific patterns of presentation that allow cryptogenic organizing pneumonia to be distinguished from secondary forms.

## REFERENCES

1. Davison AG, Heard BE, McAllister WA, Turner-Warwick ME. Cryptogenic organizing pneumonitis. *Q J Med.* 1983;52:382-94.
2. Epler GR, Colby TV, McLoud TC, Carrington CB, Gaensler EA. Bronchiolitis obliterans organizing pneumonia. *N Engl J Med.* 1985;312:152-8.

3. Xaubet A, Ancochea J, Blanquer R, Montero C, Morell F, Rodríguez Becerra E, et al. Diagnóstico y tratamiento de las enfermedades pulmonares intersticiales difusas. *Arch Bronconeumol.* 2003;39:580-600.
4. Rees JH, Woodhead MA, Sheppard MN, du Bois RM. Rheumatoid arthritis and cryptogenic organising pneumonitis. *Respir Med.* 1991;85:243-6.
5. Gammon RB, Bridges TA, al-Nezir H, Alexander CB, Kennedy JI Jr. Bronchiolitis obliterans organizing pneumonia associated with systemic lupus erythematosus. *Chest.* 1992;102:1171-4.
6. Aguiar Bujanda D, Aguiar Morales J, Bohn Sarmiento U. Bronquiolitis obliterante con neumonía organizada secundaria a quimioterapia. *Arch Bronconeumol.* 2004;40:290.
7. Rodrigo Garzón M, Asensio Sánchez S, López Encuentra A. Carcinoma broncogénico y bronquiolitis obliterante con neumonía organizada. *Arch Bronconeumol.* 1999;35:301-2.
8. Lee KS, Kullnig P, Hartman TE, Muller NL. Cryptogenic organizing pneumonia: CT findings in 43 patients. *AJR Am J Roentgenol.* 1994;162:543-6.
9. American Thoracic Society/European Respiratory Society. International multidisciplinary consensus classification of the idiopathic interstitial pneumonias. *Am J Respir Crit Care Med.* 2002;165: 277-304.
10. Ujita M, Renzoni EA, Veeraraghavan S, Wells AU, Hansell DM. Organizing pneumonia: peribubular pattern at thin-section CT. *Radiology.* 2004;232:757-61.
11. Johkoh T, Muller NL, Cartier Y, Kavanagh PV, Hartman TE, Akira M, et al. Idiopathic interstitial pneumonias: diagnostic accuracy of thin-section CT in 129 patients. *Radiology.* 1999;211: 555-60.
12. Mihara N, Johkoh T, Ichikado K, Honda O, Higashi M, Tomiyama N, et al. Can acute interstitial pneumonia be differentiated from bronchiolitis obliterans organizing pneumonia by high-resolution CT? *Radiat Med.* 2000;18:299-304.
13. Kim SJ, Lee KS, Ryu YH, Yoon YC, Choe KO, Kim TS, et al. Reversed halo sign on high-resolution CT of cryptogenic organizing pneumonia: diagnostic implications. *AJR Am J Roentgenol.* 2003;180:1251-4.
14. Arakawa H, Kurihara Y, Niimi H, Nakajima Y, Johkoh T, Nakamura H. Bronchiolitis obliterans with organizing pneumonia versus chronic eosinophilic pneumonia: high-resolution CT findings in 81 patients. *AJR Am J Roentgenol.* 2001;176:1053-8.
15. Oikonomou A, Hansell DM. Organizing pneumonia: the many morphological faces. *Eur Radiol.* 2002;12:1486-96.
16. Gaspardo EL, Escuissato DL, Davaus T, de Cerqueira EM, Souza AS Jr, Marchiori E, et al. Reversed halo sign in pulmonary paracoccidioidomycosis. *AJR Am J Roentgenol.* 2005;184:1932-4.
17. Case records of the Massachusetts General Hospital (Case 241986). *N Engl J Med.* 1986;314:1627-35.
18. Stey C, Truninger K, Marti D, Vogt P, Medici TC. Bronchiolitis obliterans organizing pneumonia associated with polymyalgia rheumatica. *Eur Respir J.* 1999;13:926-9.