

Thromboembolic Events in Patients After a Negative Computed Tomography Pulmonary Angiogram: a Retrospective Study of 165 Patients

David Jiménez,^a Mónica Gómez,^a Ruth Herrero,^a Eladio Lapresa,^a Gema Díaz,^b Luciano Lanzara,^a Carlos Escobar,^c Agustina Vicente,^d Javier Gaudó,^a Luis Máiz,^a and Antonio Sueiro^a

^aSección de Neumología, Hospital Ramón y Cajal, Madrid, Spain.

^bServicio de Neumología, Hospital de la Zarzuela, Madrid, Spain.

^cServicio de Cardiología, Hospital Ramón y Cajal, Madrid, Spain.

^dServicio de Radiodiagnóstico, Hospital Ramón y Cajal, Madrid, Spain.

OBJECTIVE: To determine the value of computed tomography (CT) angiography of the chest as a diagnostic test to exclude pulmonary embolism and to assess compliance with diagnostic protocols for thromboembolic disease.

PATIENTS AND METHODS: We retrospectively studied patients who underwent CT angiography of the chest because of suspected pulmonary embolism in 2004. All the patients were followed for 3 months. The percentage of patients diagnosed with a thromboembolic event based on an objective test during the follow-up period was determined. We analyzed the percentage of patients with a negative CT angiogram on whom additional diagnostic tests (ultrasound of the lower limbs and/or ventilation-perfusion lung scintigraphy) were performed.

RESULTS: One hundred sixty-five patients underwent CT angiography of the chest because of suspected pulmonary embolism in 2004. Four of the patients were excluded from the study because they were on chronic anticoagulation therapy and a further 2 were excluded because they had a life expectancy of under 3 months. Of the remaining 159 patients, 60 had CT angiograms that were interpreted as high probability for pulmonary embolism (prevalence of 38%). Thirty-five of the 99 patients with a negative CT angiogram experienced an objectively confirmed thromboembolic event (63% sensitivity; 95% confidence interval, 53%-73%). Other diagnostic tests were not performed in 46% of the cases.

CONCLUSIONS: In our setting, a negative single-detector helical CT angiogram was not sensitive enough to exclude the diagnosis of pulmonary embolism. Furthermore, compliance with internationally accepted diagnostic protocols was far from optimal.

Key words: Pulmonary thromboembolism. Diagnosis. Computed tomography.

Aparición de episodios tromboembólicos en pacientes con angiotomografía axial computarizada simple negativa.

Estudio retrospectivo de 165 pacientes

OBJETIVO: Determinar el rendimiento de la angiotomografía axial computarizada (angio-TAC) de tórax en el diagnóstico de exclusión de la tromboembolia pulmonar (TEP) y comprobar la observancia de los protocolos diagnósticos de enfermedad tromboembólica.

PACIENTES Y MÉTODOS: Realizamos un estudio retrospectivo de los pacientes a quienes se realizó una angio-TAC de tórax por sospecha de TEP durante el año 2004. Se realizó un seguimiento de 3 meses en todos ellos. Se determinó el porcentaje de pacientes diagnosticados de un episodio tromboembólico por un método objetivo durante el período de seguimiento. Se analizó el porcentaje de pacientes con angio-TAC negativa a quienes se realizó alguna prueba diagnóstica adicional (ecografía de miembros inferiores y/o gammagrafía de ventilación-perfusión pulmonar).

RESULTADOS: Durante el año 2004 se realizaron 165 angio-TAC de tórax por sospecha de TEP. Se excluyó a 4 pacientes con indicación de anticoagulación crónica y a otros 2 con pronóstico de vida inferior a 3 meses. De los 159 pacientes restantes, en 60 la angio-TAC se interpretó como de alta probabilidad para TEP (prevalencia del 38%). Entre los 99 pacientes con angio-TAC negativa, se produjo un episodio tromboembólico objetivamente confirmado en 35 de ellos (sensibilidad del 63%; intervalo de confianza del 95%, 53-73%). En el 46% de los pacientes no se realizó ninguna prueba diagnóstica adicional.

CONCLUSIONES: En nuestro medio la angio-TAC helicoidal no multidetectora negativa es insuficiente para el diagnóstico de exclusión de la TEP. La observancia de los protocolos diagnósticos internacionalmente aceptados dista de ser óptima.

Palabras clave: Tromboembolia pulmonar. Diagnóstico. Tomografía computarizada.

Correspondence: Dr. D. Jiménez.
Servicio de Neumología, Hospital Ramón y Cajal, Departamento de Medicina,
Universidad de Alcalá de Henares.
Ctra. de Colmenar, km 9.100. 28034 Madrid, España.
E-mail: djc_69_98@yahoo.com

Manuscript received July 7, 2005. Accepted for publication November 22, 2005.

Introduction

Computed tomography (CT) angiography of the chest is gradually replacing ventilation-perfusion scintigraphy as the method of choice for diagnosing pulmonary

embolism.¹⁻³ The diagnostic value of single-detector helical CT, however, has been shown to vary considerably in terms of both sensitivity (53%-100%) and specificity (73%-100%).^{4,5} In view of this variability, most clinicians diagnose pulmonary embolism when test results are positive and perform additional diagnostic tests (normally an ultrasound of the lower limbs) when test results are negative.¹ Such a strategy is supported by the findings of both a French multicenter study (ESSEP)⁶ and a Dutch multicenter study (ANTELOPE),⁷ which showed thromboembolic risk in the 3 months following a single-detector helical CT scan to be 1.7% (95% confidence interval [CI], 0.9%-3.2%) and 0.4% (95% CI, 0%-2.2%), respectively.

The emergence of multidetector-row CT angiography means that it is now possible to detect segmental and subsegmental pulmonary embolisms.^{8,9} Perrier and colleagues,¹⁰ for example, demonstrated that it is safe to use multidetector-row CT angiography to exclude pulmonary embolism without the need for further diagnostic tests. Their findings, however, cannot be extrapolated to settings with a different prevalence of pulmonary embolism or less sophisticated technology.

Although pulmonary angiography is the gold standard for diagnosing pulmonary embolism, interobserver agreement is not very satisfactory when subsegmental emboli are concerned,¹¹ and the method is also characterized by considerable morbidity and mortality.¹² In recent years, therefore, an increasing number of follow-up studies have begun to focus on the yield of the different diagnostic approaches used. These studies tend to analyze the rate of symptomatic embolic events in patients not receiving anticoagulants with a negative diagnosis.

Although the main aim of our study was to evaluate the usefulness of thoracic CT angiography for ruling out pulmonary embolism, we also wished to assess compliance with diagnostic protocols for venous thromboembolic disease in our setting. In other words, we wished to calculate what percentage of patients with a negative CT angiogram were given further diagnostic tests.

Patients and Methods

Design

We performed a retrospective study of all the patients suspected of pulmonary embolism who underwent thoracic CT angiography in the emergency department at Hospital Ramón y Cajal in the period between January 2004 and December 2004. Each of the patients' medical histories was reviewed to determine the probability of their having a pulmonary embolism according to the scoring system described by Wells and colleagues,¹³ which places patients into low, intermediate, and high clinical probability groups. Any patient whose probability could not be measured was placed in the low probability group.

Patients

All patients who underwent thoracic CT angiography because of suspected pulmonary embolism in the study period

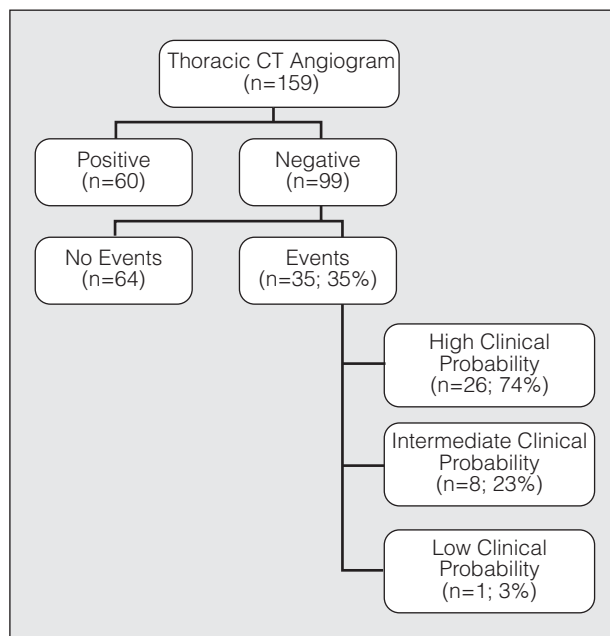


Figure. Flow diagram of patients included in study. CT indicates computed tomography.

were included. Excluded were patients on chronic anticoagulation therapy, patients with a life expectancy of under 3 months, and patients who could not be monitored at 3 months.

Diagnostic Tests

All the CT angiograms were interpreted by radiologists who were not specialized in pulmonary vascular disease. An Asteion single-slice 3500 CT scanner (Toshiba, Tokyo, Japan) was used to perform the helical CT angiograms in the study. Slice collimation was 3 mm, pitch was 1.3, and images were reconstructed at an interval of 1.5 mm. A contrast agent containing 370 mg/mL of iodine was injected intravenously at a rate of 3 mL/s. The images were taken in a caudal cephalad direction and viewed at a workstation with a mediastinal window setting.

Recurrent thromboembolic events were diagnosed according to standard criteria: positive Doppler ultrasound findings for deep vein thrombosis,¹⁴ ventilation-perfusion scintigram showing high probability of pulmonary embolism following the PLOPED recommendations¹⁵ for high and intermediate clinical probability patients, and death attributed to pulmonary embolism by 2 researchers (DJ and MG).

Follow-up

All the patients with a negative CT angiogram and who were still alive were contacted 3 months after the angiogram and their histories were reviewed to analyze the occurrence of recurrent thrombotic events. Two of the researchers (DJ and MG) reviewed the histories of deceased patients to determine the most likely cause of death.

Statistical Analysis

The diagnostic value of CT angiography was expressed in terms of sensitivity, negative predictive value, and the

TABLE 1
Baseline Characteristics of 159 Study Patients*

Characteristic	Value
Mean (SD) age, y	68 (16)
Female	91 (57%)
Previous cardiopulmonary disease	18 (11%)
Idiopathic PE	63 (40%)
PE secondary to neoplasm	29 (18%)
History of PE	21 (13%)
PE secondary to surgery	6 (4%)
PE secondary to immobility	10 (6%)
Clinical probability	
High	63
Intermediate	57
Low	39
Hemodynamic instability	5 (3%)

*PE indicates pulmonary embolism.

TABLE 2
Diagnostic Yield of Computed Tomography Angiography of the Chest in the Study Group*

	Percentage (95% CI)
Sensitivity	63 (53-73)
Negative predictive value	65 (55-74)
Negative likelihood ratio	0.37 (0.28-0.48)

*CI indicates confidence interval.

TABLE 3
Characteristics of 99 Patients With True and False Negative Findings by Computed Tomography Angiography of the Chest*

Characteristic	True Negative (n=64)	False Negative (n=35)	OR (95% CI)	P
Age ≥80 y	7 (11%)	4 (11%)	1 (0.3-3.9)	.7
Female	35 (55%)	17 (49%)	0.8 (0.3-1.8)	.7
Idiopathic PE	30 (47%)	14 (40%)	0.7 (0.3-1.7)	.6
PE secondary to neoplasm	10 (16%)	7 (20%)	1.3 (0.5-3.9)	.8
High clinical probability	8 (12%)	26 (74%)	20.2 (7-58.3)	<.0001
Alternative radiological diagnosis	13 (20%)	1 (3%)	0.1 (0.01-0.9)	.04
Hemodynamic instability	3 (5%)	1 (3%)	0.6 (0.06-6)	.9

*PE indicates pulmonary embolism; OR, odds ratio; CI, confidence interval.

negative likelihood ratio. False negatives were defined as cases in which an objectively diagnosed recurrent thrombotic event had occurred in the 3-month follow-up period or in which the patient was judged by 2 researchers to have died as a result of pulmonary embolism. The Wilson score method was used to calculate the 95% CIs for the proportions. Statistical significance was set at a value of *P* less than .05.

Results

One hundred sixty-five CT angiograms were performed because of suspected pulmonary embolism at the emergency radiology department of Hospital Ramón y Cajal between January and December 2004 (Figure). Two patients with advanced neoplastic disease and 4 patients on chronic anticoagulation therapy (to treat chronic cardiac arrhythmia in all cases) were excluded from the study. The remaining 159 patients had a mean age of 68 years (95% CI, 66-70 years) and

57% were female. The baseline characteristics of the patients are shown in Table 1.

Of the 159 CT angiograms performed, 60 (38%) were read as indicating high probability for pulmonary embolism and the corresponding patients were started on anticoagulation therapy. A thromboembolic event was diagnosed in 35 of the 99 patients with a negative CT angiogram, which is the equivalent of a sensitivity of 63% (95% CI, 53%-73%). The risk of developing a thrombotic event during the 3-month follow-up period in patients with a negative CT angiogram was 35% (95% CI, 26%-45%). Table 2 shows the diagnostic yield of CT angiography for the whole series of patients. The method offered an alternative diagnosis for 13 of the 65 patients who did not experience a thrombotic event (6 cases of emphysema, 4 cases of pneumonia, 2 neoplasms, and 1 aortic dissection) and for 1 patient who was diagnosed with pulmonary embolism in the follow-up period (alveolar pattern which had initially been interpreted as pneumonia).

Seven of the 35 thromboembolic events were diagnosed by ventilation-perfusion scintigraphy only (13 high-probability scintigrams in the high clinical probability group; 1 high-probability scintigram in the intermediate clinical probability group, and 3 intermediate-probability scintigrams). Three deaths were attributed to pulmonary embolism, and 15 patients

were diagnosed with deep vein thrombosis following an ultrasound of the lower limbs. The sensitivity of CT angiography for our series was 72% (95% CI, 63%-81%), even if we define as correct diagnosis of thromboembolic events only those based on ultrasound of the lower limbs or high-probability ventilation-

TABLE 4
Distribution of Thrombotic Events by Clinical Probability

Clinical Probability	Further Diagnostic Tests	Thrombotic Events
High (n=34)	24 (71%)*	26 (76%)†
Intermediate (n=33)	20 (61%)	8 (24%)‡
Low (n=32)	11 (34%)	1 (3%)

**P*=.06 compared to low clinical probability group.

†*P*<.001 compared to intermediate clinical probability group.

‡*P*=.03 compared to low clinical probability group.

perfusion scintigrams for patients in the high clinical probability group.

Table 3 compares the characteristics of patients with a true negative CT angiogram to those of patients with a false negative CT angiogram. High clinical probability was linked to a considerable increase in risk of thromboembolic recurrence in the 3 months following the CT angiogram. Risk was significantly reduced, on the other hand, by an alternative radiological diagnosis based on the CT angiogram.

Table 4 shows the distribution of diagnostic results according to clinical probability. The proportion of symptomatic thromboembolic events was significantly higher in the high clinical probability group. Forty-six percent of patients received no tests other than CT angiography (ventilation-perfusion scintigraphy and/or ultrasound of lower limbs) to exclude pulmonary embolism. More diagnostic tests were performed on patients in the intermediate and high clinical probability groups than in the low clinical probability group.

The CT angiogram and ultrasound of the lower limbs were negative in 18 patients. Thirteen (72%) of these patients experienced thromboembolic events. Eleven events occurred in the high clinical probability group (11 patients), 2 in the intermediate clinical probability group (4 patients), and none in the low clinical probability group (3 patients).

Discussion

Our experience indicates that a single-detector helical CT angiogram is not sensitive enough to rule out a diagnosis of pulmonary embolism. Negative test results were accompanied by an unacceptable rate of recurrence (28%) diagnosed using strict objective criteria. High clinical probability of pulmonary embolism and the absence of an alternative diagnosis on the basis of CT angiography findings considerably increased the risk of a recurrent thromboembolic event. Compliance with generally accepted diagnostic protocols for thromboembolic disease^{16,17} in our setting was far from optimal. Our results indicate that a negative CT angiogram of the chest and ultrasound of the lower limbs do not rule out pulmonary embolism in patients classified as having an intermediate or high clinical probability score.

Given the wide range of sensitivities and specificities reported by the numerous studies and meta-analyses conducted in recent years to evaluate the diagnostic yield of CT angiography in pulmonary embolism,¹⁸⁻²⁰ it is very important to validate the method in each setting. The sensitivity of the method in our setting was shown to be similar to that reported for other series in which single-detector helical CT angiography was used.²¹⁻²³ Although our results are clearly inferior to those reported by Moore and colleagues²⁴ in their meta-analysis, none of the studies they identified included patients requiring anticoagulation therapy to treat deep vein thrombosis. Their conclusions, therefore, are only applicable to patients with a negative CT angiogram and ultrasound of the lower limbs.

The diagnostic value of CT angiography can be compromised, not only by study design and level of technological sophistication, but also by interpretation errors made by nonexpert radiologists. Although not analyzed in our study, interobserver variability is a serious limitation of both CT angiography of the chest and other diagnostic tests for pulmonary embolism. Sostman and colleagues,²⁵ for example, found that sensitivity ranged from 62% to 92%, depending on who interpreted the test.

One of the advantages of thoracic CT angiography is that it offers an alternative diagnosis to that of pulmonary embolism in 11% to 85% of cases.^{18,22,26} We detected an alternative diagnosis in 14% of cases. Moreover, the detection of radiological changes other than those related to pulmonary embolism significantly reduced the probability of a thrombotic event during the follow-up period. The percentage of hemodynamically unstable patients (which generally means emboli are in the main pulmonary arteries), however, was the same in the false negative and true negative groups.

Although diagnostic guidelines for pulmonary embolism recommend the performance of further diagnostic tests for patients with negative helical CT angiograms,^{6,17} this was not done in over half the cases in our setting. Our findings show that a negative CT angiogram is clearly insufficient reason to rule out clinically significant pulmonary embolism, and do not support the idea that negative results come only in clinically insignificant cases.

Two prospective multicenter studies have shown that a negative CT angiogram along with a negative ultrasound of the lower limbs reliably rules out pulmonary embolism.^{6,7} A recently published review, however, recommends performing a pulmonary angiogram on all intermediate and high clinical probability patients with a negative CT angiogram and ultrasound.¹ Our findings support this recommendation given that 50% of the patients in our intermediate clinical probability group and 100% in our high clinical probability group were finally diagnosed with objectively confirmed pulmonary embolism.

Despite the limitations imposed by the design of our study, we believe significant bias is unlikely. Firstly, although the prevalence of pulmonary embolism in our series is greater than that reported for other groups of outpatients with suspected pulmonary embolism,²⁷ it is similar to the prevalence reported by numerous studies that have analyzed the diagnostic yield of CT angiography of the chest.^{22,28} The most plausible explanation for the high prevalence in our study population is that no additional diagnostic tests were performed on patients with low clinical probability scores and negative D-dimer levels. Secondly, none of the patients died in the 3-month follow-up period. Thirdly, recurrent embolism was diagnosed using strict objective criteria. And finally, studies most likely lose patients with pulmonary embolism, but these would have been correctly diagnosed by angiography in our study. The debate continues, however, as to whether it is necessary to anticoagulate patients with subsegmental pulmonary embolism who have few or no symptoms.²⁹

One thing that is certain, however, is that single-detector helical CT angiography should not be used in isolation to rule out pulmonary embolism in our setting.

REFERENCES

1. Fedullo PF, Tapson VF. The evaluation of suspected pulmonary embolism. *N Engl J Med*. 2003;349:1247-56.
2. Goldhaber SZ. Pulmonary embolism. *Lancet*. 2004;363:1295-305.
3. Kruij MJ, Leclercq MG, van der Heul C, Prins MH, Büller HR. Diagnostic strategies for excluding pulmonary embolism in clinical outcomes studies: a systematic review. *Ann Intern Med*. 2003;138:941-51.
4. Rathburn SW, Raskob GE, Whitsett TL. Sensitivity and specificity of helical computed tomography in the diagnosis of pulmonary embolism: a systematic review. *Ann Intern Med*. 2000;132:227-32.
5. Hiorns MP, Mayo JR. Spiral computed tomography for acute pulmonary embolism. *Can Assoc Radiol J*. 2002;53:258-68.
6. Musset D, Parent F, Meyer G, et al. Diagnostic strategy for patients with suspected pulmonary embolism: a prospective multicentre outcome study. *Lancet*. 2002;360:1914-20.
7. van Strijen MJL, De Monyé W, Schiereck J, et al. Single-detector helical computed tomography as the primary diagnostic test in suspected pulmonary embolism: a multicenter clinical management study in 510 patients. *Ann Intern Med*. 2003;138:307-14.
8. Ghaye B, Szapiro D, Mastora I, et al. Peripheral pulmonary arteries: how far in the lung does multi-detector row spiral CT allow analysis? *Radiology*. 2001;219:629-36.
9. Schoepf UJ, Goldhaber SZ, Costello P. Spiral computed tomography for acute pulmonary embolism. *Circulation*. 2004;109:2160-7.
10. Perrier A, Roy PM, Sánchez O, et al. Multidetector-row computed tomography in suspected pulmonary embolism. *N Engl J Med*. 2005;352:1760-8.
11. Stein PD, Henry JW, Gottschalk A. Reassessment of pulmonary embolism for the diagnosis of pulmonary embolism: relation of interpreter agreement to the order of the involved pulmonary arterial branch. *Radiology*. 1999;210:689-91.
12. Stein PD, Athanasoulis C, Alavi A, et al. Complications and validity of pulmonary angiography in acute pulmonary embolism. *Circulation*. 1992;85:462-8.
13. Wells PS, Anderson DR, Rodger M, et al. Derivation of a simple clinical model to categorize patients probability of pulmonary embolism: increasing the models utility with the SimpliRED D-dimer. *Thromb Haemost*. 2000;83:416-20.
14. Prandoni P, Cogo A, Bernardi E, et al. A simple approach for detection of recurrent proximal vein thrombosis. *Circulation*. 1993;88:1730-5.
15. PIOPED investigators. Value of ventilation/perfusion scan in acute pulmonary embolism: results of the prospective investigation of the pulmonary embolism diagnosis (PIOPED). *JAMA*. 1990;263:2753-9.
16. British Thoracic Society guidelines for the management of suspected acute pulmonary embolism. *Thorax*. 2003;58:470-83.
17. Uresandi F, Blanquer J, Conget F, et al. Guía para el diagnóstico, tratamiento y seguimiento de la tromboembolia pulmonar. *Arch Bronconeumol*. 2004;40:580-94.
18. Kim K, Müller NL, Mayo JR. Clinically suspected pulmonary embolism: utility of spiral CT. *Radiology*. 1999;210:693-97.
19. Donato AA, Scheirer JJ, Atwell MS, Gramp J, Duszak R. Clinical outcomes in patients with suspected acute pulmonary embolism and negative helical computed tomographic results in whom anticoagulation was withheld. *Arch Intern Med*. 2003;163:2033-8.
20. Quiroz R, Kucher N, Zou K, et al. Clinical validity of a negative computed tomography scan in patients with suspected pulmonary embolism. *JAMA*. 2005;293:2012-7.
21. Goodman LR, Curtin JJ, Mewissen MW, et al. Detection of pulmonary embolism in patients with unresolved clinical and scintigraphic diagnosis: helical CT versus angiography. *Am J Roentgenol*. 1995;164:1369-74.
22. Garg K, Sieler H, Welsh CH, Johnston RJ, Russ PD. Clinical validity of helical CT being interpreted as negative for pulmonary embolism: implications for patient treatment. *AJR Am J Roentgenol*. 1999;172:1627-31.
23. van Strijen MJL, De Monyé W, Kieft GJ, et al. Accuracy of single-detector spiral CT in the diagnosis of pulmonary embolism: a prospective multicenter cohort study of consecutive patients with abnormal perfusion scintigraphy. *J Thromb Haemost*. 2005;3:17-25.
24. Moores LK, Jackson WL, Shorr AF, Jackson JL. Meta-analysis: outcomes in patients with suspected pulmonary embolism managed with computed tomographic pulmonary angiography. *Ann Intern Med*. 2004;141:866-74.
25. Sostman HD, Layish DT, Tapson VF, et al. Prospective comparison of helical CT and MR imaging in clinically suspected acute pulmonary embolism. *J Magn Reson Imaging*. 1996;6:275-81.
26. van Beek EJR, Reekers JA. The value of pulmonary angiography for the differential diagnosis of pulmonary embolism. *Eur Radiol*. 1999;9:1310-6.
27. Perrier A, Roy PM, Aujesky D, et al. Diagnosing pulmonary embolism in outpatients with clinical assessment, D-dimer measurement, venous ultrasound and helical computed tomography: a multicenter management study. *Am J Med*. 2004;116:291-9.
28. Lorut C, Ghossains M, Horrellou MH, et al. A noninvasive diagnostic strategy including spiral computed tomography in patients with suspected pulmonary embolism. *Am J Respir Crit Care Med*. 2000;162:1413-8.
29. Perrier A. Evidence-based diagnostic algorithms for pulmonary embolism: why are they necessary? *Eur Respir Mon*. 2003;27:165-76.