

# Malignant Melanoma of Lung: Is It Easy to Determine Its Origin?

A.F. Ülger,<sup>a</sup> E. Şen,<sup>a</sup> S. Ereku,<sup>b</sup> and U. Gönüllü<sup>a</sup>

<sup>a</sup>Department of Thoracic Diseases and Tuberculosis, Faculty of Medicine, Ankara University, Ankara, Turkey.

<sup>b</sup>Department of Anatomopathology, Faculty of Medicine, Ankara University, Ankara, Turkey.

Malignant melanoma involving the respiratory tract is nearly always metastatic. True primary tumors are very rare, and only approximately 28 cases have been reported in the literature. Extensive clinical and histopathological examinations are needed to ascertain that the lung is the primary site. We present the case of a 67-year-old man with an apparent primary malignant melanoma of the lung in the right lower lobe. We also review the literature.

**Key words:** *Malignant melanoma of the lung. Primary lung tumor. Metastasis to lung.*

Melanoma pulmonar maligno: ¿es fácil determinar su origen?

El melanoma maligno que afecta al sistema respiratorio tiene un origen casi siempre metastásico y los tumores primarios verdaderos son muy frecuentes. En la bibliografía se han publicado aproximadamente 28 casos. Son necesarios estudios clínicos y anatomopatológicos detallados para considerar que el pulmón es la localización primaria del tumor. En este artículo se presenta el caso de un varón de 67 años de edad con un melanoma pulmonar maligno primario en el lóbulo inferior derecho. También se realiza una revisión de la bibliografía.

**Palabras clave:** *Melanoma maligno de pulmón. Tumor primario de pulmón. Tumor metastático de pulmón.*

## Introduction

Malignant melanoma involving the respiratory tract is nearly always metastatic in origin and true primary tumors are very rare.<sup>1</sup> Melanocytes are not normally found in the lower respiratory tract and descriptions of a blue nevus or primary melanomas of the bronchi are therefore surprising.<sup>2</sup> Our initial impression in the case we report was that the clinical picture consisted of malignant melanoma metastatic to the lungs and that multiple, small black-colored lesions on the skin were also metastatic from a primary cutaneous malignant melanoma. During the diagnostic work-up, the pathological features of skin and bronchial mucosa biopsies were consistent with a primary pulmonary malignant melanoma. We report this case of probable primary pulmonary malignant melanoma because of its rarity.

Correspondence: Dr. A.F. Ülger.  
Faculty of Medicine, Ankara University, 06100 Dikimevi, Ankara, Turkey.  
E-mail: fusunulger@yahoo.com

Manuscript received April 26, 2004. Accepted for publication May 5, 2004.

## Case Report

A 67-year-old man was admitted with a 3-month history of dyspnea, cough, sputum production, and weight loss and a 1-month history of multiple small black-colored lesions on skin. He was an ex-smoker, having smoked 20 cigarettes per day between the ages of 18 and 65. Physical examination revealed diffuse darkening of the skin, disseminated black-colored maculopapular lesions with an average diameter of 4 mm on skin, bilateral basal crackles on lung auscultation, and abdominal pain with palpation. A complete blood count showed anemia (hemoglobin: 9.7 mg/dL) and leukocytosis. The erythrocyte sedimentation rate was 94 mm/h. The lactate dehydrogenase level was 2896 U/L (normal: 220-450 U/L). Arterial blood gas analysis with the patient breathing room air revealed a PaO<sub>2</sub> of 58 mm Hg. A chest radiograph demonstrated a mass on the lower right side, and a thoracic computed tomography (CT) scan showed enlarged subcarinal lymph nodes, bilateral pleural thickening, fibrotic changes, and a subpleural mass in the right lower lobe. Bronchoscopic examination revealed diffuse black-colored lesions on hyperpigmented respiratory mucosa, and the one on the carina of right lower lobe bulged. Mucosal biopsy was performed. An eye examination was normal and a cranial CT revealed no lesions. Gastrointestinal endoscopy was not tolerated by the patient. Abdominopelvic CT images suggested multiple

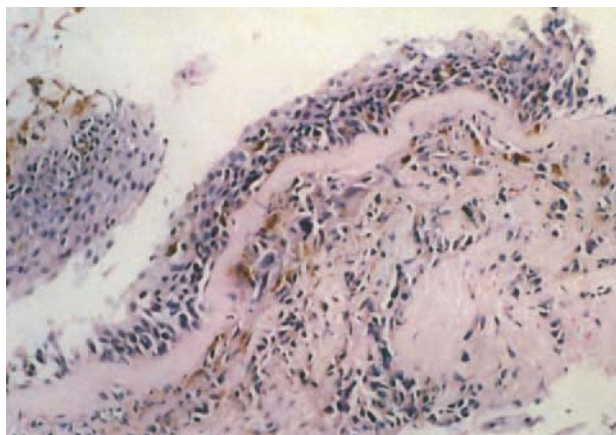


Figure 1. Bronchial mucosal biopsy (hematoxylin-eosin stain,  $\times 100$ ).

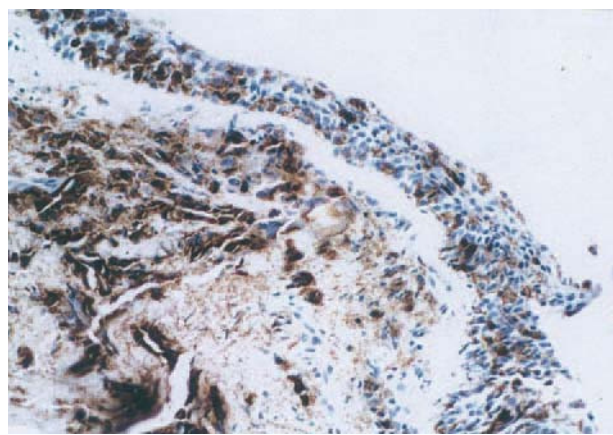


Figure 2. Bronchial mucosal biopsy (human monoclonal antibody to melanoma, HMB 45,  $\times 100$ ).

metastatic lesions in the liver and right adrenal gland, and metastatic thickening of the omentum. The most invasive skin lesion was biopsied.

Microscopic examination of the bronchial mucosal biopsy showed that the epithelium was generally intact except for metaplastic patches in the stratified squamous epithelium. Tumoral infiltration of the squamous epithelium above the basement membrane and spreading downwards into the stroma in the form of small cellular groups was observed. Histology revealed the tumor was composed of atypical cells with dense nuclei and a moderate amount of cytoplasm containing finely granular brown melanin pigmentation (Figure 1). Immunohistochemistry of tumor cells showed strong cytoplasmic positivity for the human monoclonal antibody to melanoma, HMB 45, and the S100 protein (Figure 2).

In the histopathological examination of the cutaneous lesion, a small, well-circumscribed dermal nodule having similar microscopic features was seen located beneath the epidermis. Infiltration of atypical cells into the epidermis and reactive changes of the squamous cells reminiscent of a primary malignant melanoma were not noted (Figure 3).

Based on those pathological findings, the pulmonary lesion was considered a *de novo* primary lesion of the bronchial mucosa, and the cutaneous nodule as its metastasis. Cisplatin-dacarbazine treatment was proposed by the medical oncology department, but the patient refused treatment and was discharged. He died within one month of discharge.

## Discussion

True malignant melanoma of the bronchus is very rare and metastasis from the more common primary sources must be carefully ruled out before this diagnosis is considered.<sup>1-3</sup> Most cases in the literature were reported as nearly proven or probable; only four were considered proven.<sup>3</sup>

In 1967, Allen and Drash<sup>4</sup> suggested specific criteria for establishing the primary site as lung or bronchus: *a*) junctional change with a dropping-off or nesting of melanoma cells beneath the bronchial epithelium; *b*) invasion of the bronchial epithelium by the melanoma cells in a non-ulcerated area; and *c*) an obvious

melanoma beneath these histological changes. In addition, a nevus-like lesion in the adjacent mucosa and increased pigmentation in the bronchial epithelium away from the tumor mass would be significant features.

Since then, other authors have proposed criteria that suggest primary occurrence in the lung: *a*) no previously resected pigmented skin lesion; *b*) no ocular tumor removed or evidence of a current or previous primary melanoma in any organ; *c*) solitary tumor in the surgical specimen from the lung; *d*) tumor morphology consistent with malignant melanoma involving the respiratory epithelium; *e*) junctional change, with invasion of intact bronchial mucosa by malignant melanoma cells; and *f*) full necropsy demonstrating absence of primary malignant melanoma elsewhere.<sup>5</sup>

Applying these criteria to cases reported previously in the literature greatly reduces the number of "probable" primary cases of malignant melanoma of the bronchus. In the case we report, the patient presented with predominantly pulmonary symptoms and a mass lesion in the right lower lobe. There was no history of a previously resected pigmented skin lesion. According to the patient, his skin lesions appeared after pulmonary

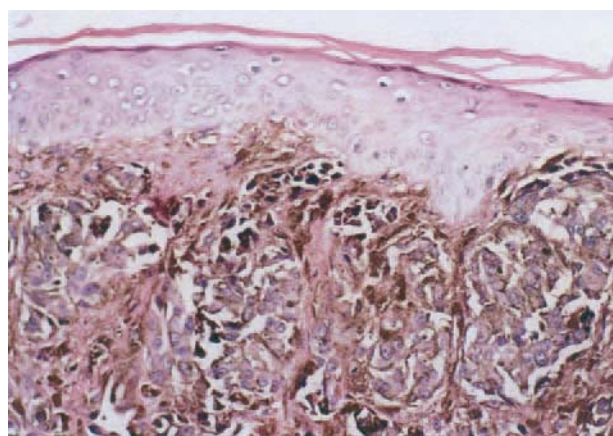


Figure 3. Biopsy of the cutaneous lesion (hematoxylin-eosin stain,  $\times 200$ ).

symptoms, and we observed rapid development of skin lesions during hospitalization. Only after analyzing the clinical presentation and histopathological evidence, which were consistent with a diagnosis of primary pulmonary tumor, did we consider the skin lesions to be metastatic.

When a cutaneous melanoma metastasizes, the thorax is often involved. Malignant melanoma of the skin is also known to regress and become clinically silent.<sup>7</sup> Our patient had no such medical history, however. The eye was also not the location of the primary tumor. CT revealed a thoracic mass, but no surgical material was obtained, because the patient was inoperable. Only bronchoscopic biopsy material was available, the main limitation of our case report. Nevertheless, the tumor showed all the previously described architectural and staining characteristics of a primary pulmonary malignant melanoma.

Why should malignant melanoma develop in the bronchi when melanocytes are not apparently present in the normal respiratory tract? One speculation is that such a tumor may arise from areas of squamous metaplasia in which a certain number of epithelial cells have undergone differentiation towards melanocytes, a phenomenon which also explains the occurrence of

pigmented squamous and basal cell tumors in the skin.<sup>1</sup> Squamous metaplasia might occur in bronchi irritated by cigarette smoke. Our patient had smoked for 47 years, making his lung a potential site for primary malignant melanoma.

The prognosis of malignant melanoma is known to be poor,<sup>1-3,7</sup> and our patient had died 1 month after discharge as a result of rapidly progressive disease. Our belief is that his tumor should be considered a probable primary malignant melanoma of the lung, even though we were never able to examine a resected tumor or autopsy material which could have provided confirmation.

#### REFERENCES

1. Farrell DJ, Kashyap AP, Ashcroft T, Morrill GN. Primary malignant melanoma of the bronchus. *Thorax*. 1996;51:223-4.
2. Corrin B. Rare pulmonary tumors. In: Corrin B, editor. *Pathology of the lungs*. 2nd ed. London: Churchill-Livingstone; 2000. p. 522-3.
3. Littman CD. Metastatic melanoma mimicking primary bronchial melanoma. *Histopathology*. 1991;18:561-3.
4. Allen MS, Drash EC. Primary melanoma of the lung. *Cancer*. 1968;21:154-9.
5. Carstens PH, Kuhns JG, Ghazi C. Primary malignant melanomas of the lung and adrenal. *Hum Pathol*. 1984;15:910-4.
6. Bagwell SP, Flynn SD, Cox PM, Davison JA. Primary malignant melanoma of the lung. *Am Rev Respir Dis*. 1989;139:1543-7.