

# Pulmonary Manifestations of Inflammatory Bowel Disease

M.C. Vennera and C. Picado

Servei de Pneumologia, Hospital Clínic, Barcelona, Departament de Medicina, Universitat de Barcelona, Barcelona, Spain.

## Introduction

Since the 1950s, lung diseases have been described in association with inflammatory bowel disease (IBD), in particular ulcerative colitis and Crohn's disease.<sup>1</sup> In 1976, Kraft et al<sup>2</sup> described 6 patients in whom chronic bronchial suppuration had appeared between 3 and 13 years after the onset of IBD. Since then, all respiratory complaints in IBD patients that cannot be explained by other causes have been defined as pulmonary manifestations of the disease.

Extraintestinal manifestations of IBD have been described in almost all organs. Their incidence, which ranges from 21% to 41%, increases with the duration of the intestinal disease, and they are more common in Crohn's disease than in ulcerative colitis.<sup>3</sup> The coincidence of multiple extraintestinal manifestation of IBD in the same individual is higher than that expected by chance. This has led to the suggestion that they may have pathogenic mechanisms in common.<sup>4</sup> Greenstein et al<sup>5</sup> distinguish 3 groups of extraintestinal manifestations: *a)* those that are associated with the inflammatory process of IBD and can respond to its treatment; *b)* those that persist even when IBD is no longer present; and *c)* those that are due to nonspecific mechanisms (less frequent).

In Spain the incidence of IBD, now considered a disease of industrialized countries, has increased in the last 30 years in line with changes in the standard of living. It is currently estimated that 65 000 Spaniards suffer from this disease, but that the figure could triple within 10 years. In 1990, Hinojosa et al<sup>6</sup> reported an overall incidence of 9.07 cases per 100 000 person-years and an overall prevalence of 28.87 per 100 000 population. In 1992, the Catalan IBD group<sup>7</sup> published a survey undertaken between 1978 and 1987 that showed a prevalence of 19 cases per 100 000 population in Barcelona and 18 per 100 000 in Gerona.

In the last 10 years, many advances have been made in the understanding of the genetic contribution to IBD.

Ethnic predominance (Ashkenazi Jews), higher frequency in members of the same family, and higher concordance between monozygotic twins are 3 clear indications of the central role of genetic factors in the pathogenesis of the disease. Recently, the detailed map of chromosome 16 has allowed the identification of a gene that codes for a cytoplasmic protein called NOD2, also known as CARD15. This protein, expressed by macrophages, represents a very important discovery for the understanding of IBD.<sup>8</sup>

## Pulmonary Manifestations

Although pulmonary disease represents the least frequent extraintestinal manifestation of IBD, it is likely that its true prevalence is unknown. In contrast to other extraintestinal manifestations, pulmonary deterioration is more commonly associated with ulcerative colitis than Crohn's disease.

Storch et al<sup>9</sup> reviewed 400 cases, of which 150 had had active pulmonary disease and a larger number had only exhibited subclinical manifestations. This review, in addition to providing a description and classification

TABLE 1  
Diagnostic Protocol for Pulmonary Diseases Associated With Inflammatory Bowel Disease

Laboratory
Complete blood count with differential leukocyte count
Antineutrophil cytoplasmic antibodies
Perinuclear antineutrophil cytoplasmic antibodies
Angiotensin converting enzyme
Erythrocyte sedimentation rate
Radiographic diagnosis
Chest radiograph
High-resolution computed tomography of the thorax
Others
Sputum culture
Purified protein derivative
More complex procedures
Pulmonary function testing
Bronchoscopy with bronchoalveolar lavage
Lung biopsy
Lower limb Doppler ultrasound
Ventilation-perfusion scintigraphy
Computed tomography angiography
Hypercoagulability testing

Correspondence: Dra. M.C. Vennera.  
Servei de Pneumologia, Hospital Clínic.  
Villarroel, 170. 08036 Barcelona, España.  
E-mail: mvennera@hotmail.com

Manuscript received May 25, 2004. Accepted for publication August 31, 2004.

Based on Storch et al.<sup>9</sup>

of the diseases encountered, contains a comprehensive list of studies that covers all differential diagnoses (Table 1).

Among the diseases that could be confused with extraintestinal manifestations, sarcoidosis and Wegener's disease, both of them granulomatous, can coincide with IBD. It has been postulated that infection by atypical mycobacteria may contribute to the formation of granulomas in Crohn's disease and sarcoidosis. These mycobacteria have been detected in tissues from patients with both diseases. Also, the Kveim reaction may be positive or negative in either disease, whilst angiotensin converting enzyme can be elevated in sarcoidosis but not in Crohn's disease. The presence of antineutrophil cytoplasmic antibodies and perinuclear antineutrophil cytoplasmic antibodies in IBD suggests common autoimmune mechanisms with Wegener's disease.

Mahadeva et al<sup>10</sup> studied the relationship between clinical events, physiological changes, and findings in high resolution computed tomography (HRCT) of the thorax in 17 patients with IBD (14 with ulcerative colitis and 3 with Crohn's disease) who presented pulmonary manifestations without causes that could explain their appearance. In 7 patients, colectomy had been performed due to severe disease. Dyspnea was the predominant symptom, independent of the type of disease. Some patients also presented bronchial hypersecretion. Pulmonary function was normal in 6 patients, despite the fact that they displayed radiographic signs of air trapping. In 13 patients, clear bronchiectasis was revealed by thoracic HRCT; 9 patients showed signs of air trapping, 5 had a "tree in bud" appearance, and 2 presented changes indicative of fibrosis. A single patient showed no alterations, although a diagnosis of alveolitis had been made and confirmed histologically 14 years earlier and treated effectively with corticosteroids. In this study, the use of HRCT alongside analysis of pulmonary function made it possible to detect respiratory disease early.

The difficulty in diagnosing pulmonary diseases associated with IBD is probably due to 2 main factors. Firstly, extraintestinal manifestations may present without coinciding with the onset of the intestinal disease, meaning that they are not linked by the doctor to the underlying disease. Secondly, they can be subclinical, meaning that the patient fails to notice them, does not report symptoms, and, therefore, the doctor does not investigate them. This situation can only change if the doctor bears in mind the possible association and, as a consequence, performs a focused diagnostic assessment.

The drugs used in the treatment of IBD (sulfasalazine, mesalamine, infliximab, and methotrexate) can induce pulmonary diseases as a side effect. These can be very severe and/or similar to some of the pulmonary diseases associated with IBD. They must be diagnosed early, since they improve when the implicated drug is suspended and can respond to corticosteroids.<sup>9</sup>

TABLE 2  
Pulmonary Manifestations in Inflammatory Bowel Disease

<p>Clinical manifestations</p> <p>Diseases of the upper airways: glottic and subglottic stenosis of the larynx, tracheal stenosis</p> <p>Diseases of the lower airways: bronchiectasia, bronchial suppuration, panbronchiolitis, necrotizing bronchiolitis, and granulomatous bronchiolitis</p> <p>Diseases of the pulmonary parenchyma: necrotizing bronchiolitis organizing pneumonia, sterile necrobiotic nodules, peripheral infiltrates with eosinophils</p> <p>Subclinical manifestations</p> <p>Increased numbers of lymphocytes in induced sputum and bronchoalveolar lavage</p> <p>Increase in exhaled nitric oxide</p> <p>Atopy</p> <p>Altered pulmonary function</p>
---

*Pulmonary Manifestations in Inflammatory Bowel Disease (Table 2)*

*Clinical.* Camus and Colby<sup>11</sup> provided an exhaustive description of all pulmonary manifestations (Table 3). In general, the most notable symptoms are cough, expectoration, and dyspnea, to which can be added dysphonia or stridor if the lesion is found in the upper airways, or pneumothorax, pneumomediastinum, or significant obstruction if it occurs in the small airway. In a very small number of cases hemoptysis has also been described. Curiously, although it is based on an inflammatory process, the bronchial response to methacholine is generally normal, and the bronchodilator test with inhaled beta agonists is not significant. Radiography may be normal or reveal narrowing of the trachea, when this is affected, or bronchial enlargements, as in chronic bronchial suppuration. Relatively frequently, bronchiectasis that is not visible in conventional radiographs can be diagnosed by thoracic HRCT. Bronchoalveolar lavage yields variable results: sometimes the presence of polymorphonuclear leukocytes or lymphocytes is revealed, whilst in other cases the results are nonspecific.

The following section describes the conditions.

*Diseases of the upper airways.* Glottic and subglottic stenosis of the larynx have been described,<sup>12</sup> as has tracheal stenosis;<sup>13</sup> in these conditions, the presence of friable and hemorrhagic tissue that obstructed the airway was observed by endoscopy. Histology confirmed an inflammatory process with the presence of plasma cells, lymphocytes, and neutrophils. The principal manifestations were stridor and dyspnea. In some cases the respiratory symptoms were associated with gangrenous hypodermis, episcleritis, and mouth ulcers. The patients responded to treatment with glucocorticoids and, in some cases, the obstruction required laser treatment.<sup>13-15</sup>

*Diseases of the lower airways.* Storch et al<sup>9</sup> found that bronchiectasia constituted the most frequently

TABLE 3  
**Pulmonary Manifestations in Inflammatory Bowel Disease: Site, Type of Lesion, Predominance, Symptoms, Endoscopic Findings, Radiography, Bronchoalveolar Lavage, Treatment, and Prognosis\***

Site	Lesion	UC	CD	Symptoms	Appearance	Endoscopy	BAL	Treatment	Prognosis
Upper airway									
Larynx and glottis	Stenosis	++	+	Cough, dyspnea, aphonia, stridor	Narrowing	Edema and glottic and subglottic inflammation	NS	iv steroids, laser resection	Good
Trachea	Stenosis and inflammation	++	+	Cough, dyspnea, aphonia, stridor, hemoptysis	Narrowing	Stenosis and inflammation	NS	Orally administered or iv steroids, laser ablation	Good
Bronchi	Chronic bronchitis	++	±	Cough, limited secretion, wheezing	Normal	Light inflammation of the large airways	PMN	Inhaled steroids	Good
	Chronic bronchial suppuration	++	±	Cough, wheezing copious secretions	Thickened bronchi	Severe inflammation of the large airways	PMN	Inhaled or orally administered steroids	Variable, sequelae
	Bronchiectasia	++	+	Cough, wheezing secretions	Thickened/dilated bronchi	Extensive inflammation and narrowing	PMN	Inhaled or orally administered steroids	Variable, sequelae
Small airway	Diffuse panbronchiolitis	+	-	Dyspnea, secretions	“Tree in bud”	Normal to light inflammation	NS	Inhaled or orally administered steroids	Poor
	Bronchiolitis obliterans	+	-	Dyspnea, obstruction of airflow	Mosaic pattern in CT	Normal	NS	Inhaled or orally administered steroids	Poor
Pulmonary parenchyma	BOOP	++	±	Dyspnea, fever, acute respiratory insufficiency	Bilateral or diffuse infiltration	Normal	Variable	Oral or iv steroids	Good
	NSIP	+	+	Dyspnea	Bibasilar opacity	Normal	LYM	Oral steroids	Good

\*BOOP indicates bronchiolitis obliterans organizing pneumonia; UC, ulcerative colitis; CD, Crohn's disease; NS, nonspecific; BAL, bronchoalveolar lavage; iv, intravenous; LYM, lymphocytes; NSIP, nonspecific interstitial pneumonia; PMN, polymorphonuclear leukocytes; and CT, computed tomography. Based on Camus and Colby.<sup>11</sup>

reported condition associated with IBD. Mahadeva et al<sup>10</sup> encountered bronchiectasia in 13 out of 17 patients studied. Camus et al<sup>13</sup> described bronchiectasia in 6 out of 15 patients with compromised upper airways; alongside chronic bronchitis, this represented the most common manifestation. In 85% of cases, pulmonary manifestations appeared after a diagnosis of IBD had been made. In 79%, pulmonary disease appeared when IBD was inactive due to medical or surgical treatment (colectomy). In 5%, both pulmonary and digestive tract diseases appeared at the same time. Bronchoscopy revealed tissue that appeared inflamed, and biopsy performed in 12 of the 13 cases likewise confirmed the presence of lymphocytes and plasma cells in the submucosa, with squamous metaplasia sometimes infiltrated by neutrophils in the mucosa. The authors mention that these endoscopic and histological findings are unusual, and that there is a histological similarity between the colon and the airways, especially in relation to neutrophil infiltration, mucosal ulceration, and underlying chronic inflammation with the presence of plasma cells. Sputum culture did not yield significant

results. Studies were based on patients who were nonsmokers and did not have a prior history of respiratory disease, who presented with coughing and high levels of mucopurulent expectoration,<sup>16</sup> and who did not respond to antibiotics but did respond to inhaled or systemic corticosteroids.<sup>13,17-20</sup>

As mentioned, chronic bronchitis is the second most common condition to be associated with IBD. It differs from pulmonary suppuration in the quantity of purulent sputum produced, and from bronchiectasia in that, in addition to cough and the quantity of secretions, the latter is visualized by bronchial dilation in thoracic HRCT.<sup>13</sup>

Camus et al<sup>13</sup> mentioned that, as in the case of bronchiectasia, there was no prior history of smoking in these patients, nor was there any parallel exacerbation of bronchial and intestinal symptoms; histology and the response to corticosteroids led them to think that a relationship exists between bronchial inflammation and IBD.

*Disease of the small airway.* The normal course of these lesions can result in irreversible damage.<sup>7</sup> In some

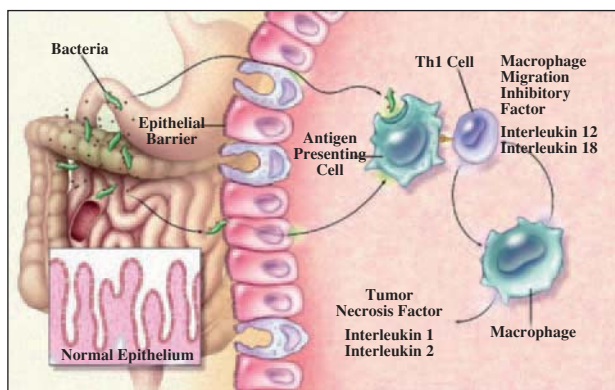


Figure. Pathogenesis of inflammatory bowel disease. Th indicates T helper. (Adapted from Podolsky.<sup>30</sup>)

cases they produce diffuse panbronchiolitis, a specific symptom that was originally described in Asians.<sup>21-23</sup> These diseases, as in almost all associated respiratory disorders, respond to oral, parenteral, or inhaled corticosteroids.

Panbronchiolitis, necrotizing bronchiolitis, and granulomatous bronchiolitis have been described in a small number of cases. These are diseases of the small airway that have been confirmed by biopsy in some cases. In addition, functional alterations consistent with small airway disease have been described without definitive histological evidence.

*Diseases of the pulmonary parenchyma.* In these cases, the predominant symptom is dyspnea. The most common manifestation is bronchiolitis obliterans organizing pneumonia,<sup>15,24</sup> which normally presents with fever, general malaise, and, on occasions, thoracic pain. It is accompanied by single or multiple radiographic opacities. In some cases, biopsy is indicated in order to arrive at a diagnosis.

Other forms of interstitial disease are rare. The formation of sterile necrobiotic nodules and peripheral infiltrates with eosinophilia has been described.<sup>13</sup> Drugs such as sulfasalazine and mesalamine can cause similar symptoms.

*Subclinical.* The development of more advanced techniques has facilitated the identification of subclinical indicators of respiratory disease in patients that are as yet asymptomatic:

*Induced sputum.* Fireman et al<sup>25</sup> studied pulmonary dysfunction through induced sputum in 24 patients with Crohn's disease and 9 healthy controls. The former had varying degrees of activity of the disease; they lacked respiratory symptoms and pulmonary function tests were normal. Induced sputum from the patients with Crohn's disease contained a higher percentage of lymphocytes than found in samples from the control group. In contrast, there was no difference in the eosinophil count. Two thirds of the patients had an

accumulation of CD4+ cells: CD4+/CD8+ ratio of 7.7 (2.5). The results of this study were similar to those of Bonniere et al,<sup>26</sup> who used bronchoalveolar lavage in 22 patients with Crohn's disease who did not display respiratory symptoms. These authors observed that 54% had an abnormal CD4+/CD8+ ratio.

*Nitric oxide.* Nitric oxide is a mediator of inflammation in a number of pathological processes. It is elevated in exhaled air (NOe) from asthmatic patients compared with healthy volunteers, and also in aspirated colonic gas from patients with Crohn's disease. On this basis, Koek et al<sup>27</sup> undertook an evaluation of NOe levels in active IBD that included 31 patients with Crohn's disease and 24 with ulcerative colitis. In addition, they assessed possible correlations between a) NOe levels and IBD activity, and b) spirometry and IBD activity in a subgroup. The authors found that NOe was elevated in active IBD, and in addition, observed a negative correlation between spirometry values and disease activity in patients with Crohn's disease.

*Bronchial hyperreactivity.* Ceyhan et al<sup>28</sup> undertook a study in 30 patients with IBD (19 with ulcerative colitis and 11 with Crohn's disease) and 16 control subjects to analyze the following: atopic state, based on skin tests; the existence of bronchial hyperreactivity, through bronchial provocation with methacholine; and the presence of functional indicators of respiratory abnormalities. The results revealed that the prevalence of allergic symptoms, positive skin tests, and functional abnormalities was significantly higher in patients with IBD. In contrast, there was no difference in the prevalence of bronchial hyperreactivity between the groups.

Herrlinger et al<sup>29</sup> studied 66 patients with IBD (31 with ulcerative colitis and 35 with Crohn's disease) and 30 controls using the following tests of respiratory function: forced expiratory volume in the first second, inspiratory vital capacity, ratio of forced expiratory volume in the first second to inspiratory vital capacity, and carbon monoxide diffusing capacity. The activity of IBD was also evaluated. The results revealed that pulmonary function was significantly impaired in both ulcerative colitis and Crohn's disease patients compared with the control group. No significant differences were observed between ulcerative colitis and Crohn's disease. The effect was more pronounced when IBD was active than when it was not.

## Pathogenesis

The pathogenesis of IBD is only partially understood. It is thought to be the result of inadequate and recurrent activation of the mucosal immune system, initiated by the presence of the normal gut flora.<sup>30</sup> As mentioned, genetic factors undoubtedly contribute to the susceptibility to IBD. Nevertheless, studies of identical twins, in which only 45% of the genetic loci



were concordant for Crohn's disease, suggest that the development of the disease depends on other factors. One of the factors mentioned was smoking, which appears to protect against ulcerative colitis but to increase the risk of Crohn's disease.<sup>31,32</sup> The role of nonsteroidal antiinflammatory drugs has also been considered, since they can provoke exacerbations. Furthermore, there has been some speculation about the role of early appendectomy, which has been associated with a reduced incidence of ulcerative colitis.<sup>33,34</sup> The gut flora is, perhaps, the most important factor in the development of the disease. Studies using animal models show that the disease does not develop in animals maintained in germfree conditions.<sup>35,36</sup> Other authors propose that antigens present in the diet could also contribute. Stimulation can occur as a result of the penetration of bacterial products through the mucosa to activate dendritic cells and lymphocyte populations, thereby triggering the classical immune response. In this way, the epithelium can produce chemokines and cytokines that will recruit and activate the immune cells of the mucosa. In one way or another, the differentiation of T helper 1 cells will be induced in patients with Crohn's disease, and that of T helper 2 cells in patients with ulcerative colitis (Figure). In Crohn's disease, the action of T helper 1 cells is characterized by the production of interferon gamma and interleukin 2, whilst in ulcerative colitis, the action of atypical T helper 2 cells results in mucosal production of transforming growth factor beta and interleukin 5.<sup>37</sup> Activation of the inflammatory process is accompanied by the production of a wide variety of nonspecific mediators of inflammation. These can include other cytokines, chemokines, growth factors, arachidonic acid metabolites (prostaglandins and leukotrienes), and nitric oxide.<sup>38,39</sup>

To date, the association of pulmonary disease with IBD has yet to be fully explained. The airways and alimentary canal have a common origin in the primitive gut, and both have a columnar epithelium containing goblet cells and submucosal glands, both of which undergo nonspecific inflammatory changes in the bronchial epithelium and in the colonic epithelium in the case of ulcerative colitis.<sup>40,41</sup> Various hypotheses have been proposed in support of common pathogenic mechanisms. One interesting hypothesis postulates that common irritants (antigens), both inhaled and ingested, sensitize the lymphoid tissue of the lung and intestine, and trigger an allergic inflammatory response in both.<sup>42</sup>

## Conclusions

The incidence and prevalence of IBD, and with it, all of its extraintestinal manifestations, is increasing in developed countries. Furthermore, reports of pulmonary manifestations of the disease are increasingly present in the literature. Nevertheless, their true extent remains unknown due to the difficulty of diagnosis. Advances in the understanding of the pathogenic mechanisms of

IBD have undoubtedly been made. However, no definitive conclusions have yet been reached. Although the 2 diseases are assumed to have common pathogenic processes, nothing is known with any degree of certainty. The possibility that inflammatory lung diseases can occur in response to substances arising in the digestive tract is a little-explored line of investigation, and as such, represents a challenge for researchers interested in understanding the mechanisms involved in this type of pulmonary disease. The recent introduction of noninvasive methods with which to study the inflammatory response of the lung—such as analysis of exhaled air (nitric oxide, carbon monoxide, and markers of oxidative stress), analysis of exhaled breath condensates (arachidonic acid, cytokines, etc), and induced sputum (cytological analysis)—will allow a more in-depth and risk-free study to be performed in a large sample of patients with IBD. This will facilitate a deeper understanding of the mechanisms responsible for respiratory disease associated with IBD.

## REFERENCES

1. Rubin EH. The lung as a mirror of systemic disease. Springfield: Charles C. Thomas; 1956.
2. Kraft SC, Earle RH, Rossler M, Estarly JR. Unexplained bronchopulmonary disease with inflammatory bowel disease. *Arch Intern Med.* 1976;136:454-9.
3. Velloso F, Carvalho J, Magro F. Immune-related manifestations of inflammatory bowel disease: a prospective study of 792 patients. *J Clin Gastroenterol.* 1996;23:29-34.
4. Rankin GB, Watts HD, Melnyk CJ, et al. National Cooperative Crohn's Disease Study: extraintestinal manifestations and perianal complications. *Gastroenterology.* 1979;77:914-20.
5. Greenstein AJ, Janowitz HD, Sachar DB. The extraintestinal complications of Crohn's disease and ulcerative colitis. *Medicine (Baltimore).* 1976;55:401-12.
6. Hinojosa J, Primo J, Lledó S, López A, Roig JV, Fernández J. Incidencia de enfermedad inflamatoria intestinal en Sagunto. *Rev Esp Enf Ap Dig.* 1990;78:283-7.
7. Solà la Moglia R, García-Pugués AM, Monés Xiol J, Badosa Gallart C, Badosa Gallart J, Casellas F, et al. Enfermedad inflamatoria crónica intestinal en Cataluña (Barcelona y Gerona). *Rev Esp Enf Ap Digest.* 1992;81:7-14.
8. Ogura Y, Bonen DK, Inohara N, et al. A frameshift mutation in NOD2 associated with susceptibility to Crohn's disease. *Nature.* 2001;411:603-6.
9. Storch I, Sachar D, Katz S. Pulmonary manifestations of inflammatory bowel disease. *Inflamm Bowel Dis.* 2003;9:104-15.
10. Mahadeva R, Walsh G, Flower CDR, Shneerson JM. Clinical and radiological characteristics of lung disease in inflammatory bowel disease. *Eur Respir J.* 2000;15:41-8.
11. Camus PH, Colby TV. The lung in inflammatory bowel disease. *Eur Respir J.* 2000;15:5-10.
12. Kelly JH, Montgomery WW, Goodman ML, Mulvaney TJ. Upper airway obstruction associated with regional enteritis. *Ann Otol Rhinol Laryngol.* 1979;88:95-9.
13. Camus P, Piard F, Ashcroft T, Gal AA, Colby TV. The lung in inflammatory bowel disease. *Medicine (Baltimore).* 1993;72:151-83.
14. Karasalioglu A, Kutlu K, Yilmaz T. Obstruction laringotracheale en cas de colitis ulcéreuse. *Rev Laryngol.* 1988;109:468-71.
15. Wilcox P, Millar R, Millar G, Heath J, Nelems B, Muller N, et al. Airway involvement in ulcerative colitis. *Chest.* 1987;92:18-22.
16. Cohen M, Sahn S. Bronchiectasis in systemic diseases. *Chest.* 1999;116:1063-74.
17. Higenbottam T, Cochrane GM, Clark TJH, et al. Bronchial disease

- se in ulcerative colitis. *Thorax*. 1980;35:581-5.
18. Butland RJA, Cole P, Citron KM, et al. Chronic bronchial supuration and inflammatory bowel disease. *Q J Med*. 1981; 50:63-75.
  19. Moles KW, Barghese G, Hayes JR. Pulmonary involvement in ulcerative colitis. *Br J Dis Chest*. 1988;82:79-83.
  20. Rickli H, Fretz C, Hoffman M, Walser A, Knoblauch A. Severe inflammatory upper airway stenosis in ulcerative colitis. *Eur Respir J*. 1994;7:1899-902.
  21. Desai SJ, Gephardt GN, Stoller JK. Diffuse panbronchiolitis preceding ulcerative colitis. *Chest*. 1989;95:1342-4.
  22. Iwata M, Sato A, Colby TV. Diffuse panbronchiolitis. En: Epler GR, editor. *Diseases of the bronchioles*. New York: Raven Press; 1994. p. 153-79.
  23. Schulte W, Szrepka A, Bauer PC, Guzmán J, Costabel U. Diffuse panbronchiolitis. *DTSCH Med Wochenschr*. 1999;124:584-8.
  24. Swinburn CR, Jackson GJ, Ascroft T, Morrit GN, Corris PA. Bronchiolitis obliterans organizing pneumonia in a patient with ulcerative colitis. *Thorax*. 1988;43:735-6.
  25. Fireman Z, Osipov A, Kivity S, Kopelman Y, Sternberg A, Lazarov E, et al. The use of induced sputum in the assessment of pulmonary involvement in Crohn's disease. *Am J Gastroenterol*. 2000;95:730-4.
  26. Bonniere P, Wallaert B, Cortot A, Marchandise X, Riou Y, Tonnel AB, et al. Latent pulmonary involvement in Crohn's disease: biological, functional, broncoalveolar lavage and scintigraphic studies. *Gut*. 1986;27:919-25.
  27. Koek GH, Verleden GM, Evenepoel P, Rutgeerts P. Activity related increase of exhaled nitric oxide in Crohn's disease and ulcerative colitis: a manifestation of systemic involvement? *Respir Med*. 2002;96:530-5.
  28. Ceyhan BB, Karakurt S, Cevik H, Sungur M. Bronchial hyperreactivity and allergic status in inflammatory bowel disease. *Respiration*. 2003;70:60-6.
  29. Herrlinger K, Noftz M, Dalhoff K, Ludwig D, Stange E, Fellermann K. Alterations in pulmonary function in inflammatory bowel disease are frequent and persist during remission. *Am J Gastroenterol*. 2002;97:377-81.
  30. Podolsky D. Inflammatory bowel disease. *N Engl J Med*. 2002; 347:417-29.
  31. Cosnes J, Beaugerie L, Carbornnel F, Gendre JP. Smoking cessation and the course of Crohn's disease: an intervention study. *Gastroenterology*. 2001;120:1093-9.
  32. Lindberg E, Tysk C, Andersson K, Jarnerot G. Smoking and inflammatory bowel disease: a case control study. *Gut*. 1988;29: 352-7.
  33. Andersson RE, Olaison G, Tysk C, Ekblom A. Appendectomy and protection against ulcerative colitis. *N Engl J Med*. 2001;334:808-14.
  34. Evans JM, McMahon AD, Murray FE, McDevitt DG, Mac Donald TM. Non-steroidal anti-inflammatory drugs are associated with emergency admission to hospital for colitis due to inflammatory bowel disease. *Gut*. 1997;40:619-22.
  35. Rath HC, Schultz M, Freitag R, et al. Different subsets of enteric induce and perpetuate experimental colitis in rats and mice. *Infect Immun*. 2001;69:2277-85.
  36. Elson CO. Experimental models of intestinal inflammation: new insights into mechanisms of mucosal homeostasis. En: Ogra PL, Mestecky J, Lamm ME, Strober W, Bienenstock J, McGhee JR, editors. *Mucosal immunology*. 2nd ed. San Diego: Academic Press; 1999. p. 1007-24.
  37. Fuss IJ, Neurath M, Boirivant M, et al. Disparate CD4+ lamina propria (LP) lymphokine secretion profiles in inflammatory bowel disease: Crohn's disease LP cells manifest increased secretion of IFN-gamma, whereas ulcerative colitis LP cells manifest increased secretion of IL-5. *J Immunol*. 1996;157:1261-70.
  38. Swidsinski A, Ladhoff A, Pernthaler A, et al. Mucosal flora in inflammatory bowel disease. *Gastroenterology*. 2002;122:44-54.
  39. Fiocchi C. Inflammatory bowel disease: etiology and pathogenesis. *Gastroenterology*. 1998;115:182-205.
  40. Kirsner JB. Ulcerative colitis 1970: recent developments. *Scand J Gastroenterol*. 1970; (6 Suppl):63-91.
  41. Kinnear W, Higenbottam T. Pulmonary manifestations of inflammatory bowel disease. *Inter Med Spec*. 1983;4:104-11.
  42. Kirsner JB, Shorter RG. Recent developments in "non-specific" inflammatory bowel disease. *N Engl J Med*. 1982;306:775-85.